

Abdominal Myolipoma in Dog- a Case Report

C. Mishra¹, M. K. Shah², S. Mainali¹ and B.R. Pandey¹*

¹Faculty of Animal Science, Veterinary Science and Fisheries, Agriculture and Forestry University, Rampur, Chitwan, Nepal

²Department of Veterinary Surgery and Pharmacology, Faculty of Animal Science, Veterinary Science and Fisheries, Agriculture and Forestry University, Rampur, Chitwan, Nepal

*Corresponding author: chiranjeevimishra1998@gmail.com

ABSTRACT

A 6-year-old female dog was referred to Veterinary Teaching Hospital of Agriculture and Forestry University, Rampur, Chitwan, Nepal. The complaint was an abdominal mass around the umbilicus centrally and cranial to the sternum without any clinical manifestation. Histopathologically, mature adipocytes of different sizes were seen and were interposed within spindle shaped smooth muscle fibre. The muscle fibres were seen separated due to the proliferative infiltration of these adipocytes in between. Abdominal myolipoma was diagnosed based on the clinical manifestation, gross and histopathological lesions. This could have been misdiagnosed with mammary tumour but the absence of proliferative myoepithelial cells ruled out the possibility.

Keywords: *H and E staining, Histopathology, Mesentery, Myolipoma*

INTRODUCTION

Lipomas are commonly called as tumor of subcutaneous as neoplasm of fat cells are encapsulated by fibrous tissues. Most of the cases present a re benign and frequent problem of senescing dogs, can be found anywhere in the body, but more often in the axillae, legs, abdomen, and subcutaneous areas of the chest (Rao & Krishna, 2011). It is a rare case and is described as soft tissue tumor, admixture with maturing adipocytes and smooth muscle cells. The differential diagnosis includes: liposarcoma, angioliipoma, leiomyosarcoma (Takahashi et al., 2004). Moore et al. (2006) found that cases of lipoma suggest a partially or fully capsulated mass with a uniform admixture of fat cells and smooth muscle. Similarly, Kim et al. (2013) reported similar findings of myolipoma in adult dogs based on their previous studies in the mesentery.

METHODOLOGY

The excision of the abdominal mass was done under general anesthesia. After the excision, the mass was preserved in 10% buffered formalin. Later on, the gross morphology of the mass was assessed using electric balance, vernier caliper and measuring cylinder. Immediately, histopathology was carried out and stained with H & E stain

CASE DESCRIPTION

A 6-year-old female dog, named Lucy, was referred to Veterinary Teaching Hospital of Agriculture and Forestry University, Rampur, Chitwan, Nepal in October 2021 with a 6-month history of painless muscular mass around umbilicus caudal to sternum distal to the mammary glands.

Vital parameters revealed normal parameters. Temperature, heart rate and respiration rate were 37°C, 85 beats/min and 45 breaths/min respectively. Hematological parameters provided no diagnostic evidence of clinical manifestations but abdominal palpation revealed a soft mass around the umbilicus. Aspiration of the mass revealed absence of pus or any sort of sepsis. Later, the mass was surgically resected under general intravenous anesthesia and taken lab for further investigation. The dog showed good post-operative recovery.

Gross morphology was assessed and histopathology of the mass was done. Gross morphology revealed a creamy white soft mass with sides measuring 58.37 mm × 45.03 mm × 30 mm, weighing 47.09g and volume of 50 ml.

Histopathology revealed numerous mature adipocytes and were interposed with clearly defined spindle shaped smooth muscles. Another major finding was the gap between the muscle fibers which was due to interposition of fat cells inside the fibers seeming as loose separation of muscle bundles. Blood vessels were seen congested. The location, gross morphology and histopathology of the mass confirmed the case of myolipoma of abdominal muscle.

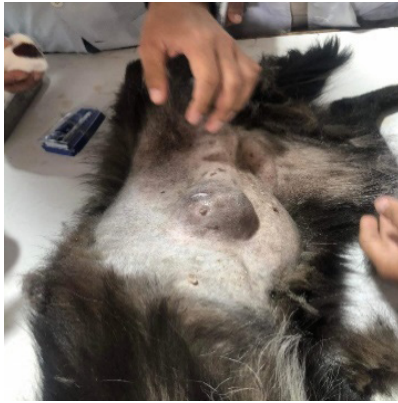

Figure 1: Gross appearance of abdominal mass before excision. The red arrow defines the area.

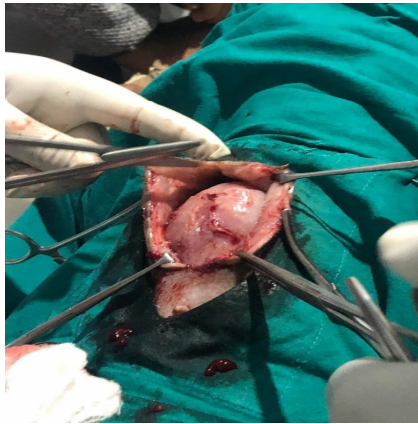

Figure 2: The mass was surgically exposed under general anesthesia.

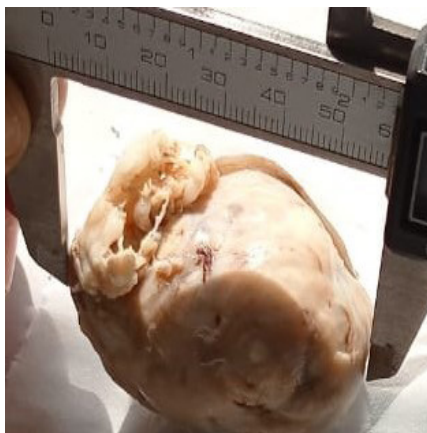


Figure 3: Gross section of resected tumor mass. The tumor's cut surface shows capsulation, hard, creamy white round mass.

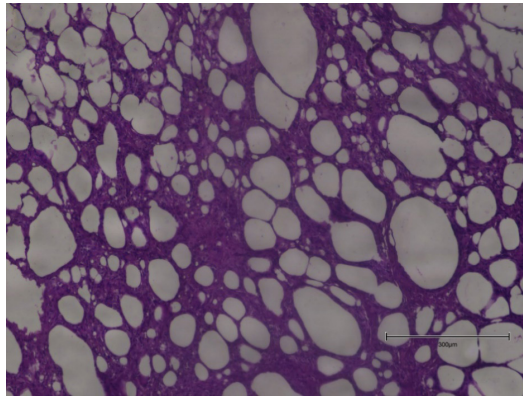


Figure 4: Microscopic Finding. The tumor shows admixture of smooth muscle fiber and adipocytes with congested vessels under H&E stain. Red arrows show distinguished adipocytes.

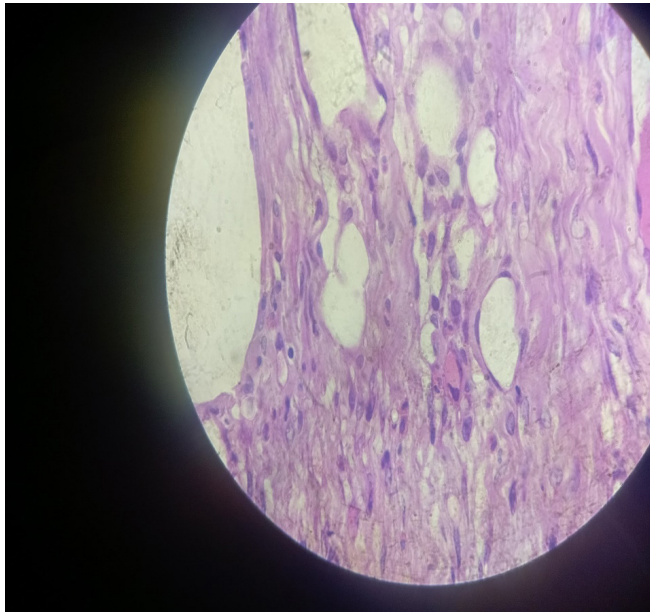


Figure 5: Microscopic Findings. The tumor shows prominent smooth muscle fibers (nucleus stained) and interspersed adipocytes under H&E stain. The red arrow shows well defined adipocyte between muscle fibers. The blue arrow shows gap in muscle fibers due to infiltration of small adipocytes.

CONCLUSION

This was a rare case of abdominal myolipoma in the dog diagnosed at Teaching Hospital, Rampur. The tumor is more frequent seen in female dogs and more predisposed with

old age. Correct diagnostic and imaging technique with histopathology is needed to accurately assess and resect the tumor. This surgery goes good with proper resection and follows good post-operative recovery. There was no evidence that the tumor recrudesces after 5 months of constant follow-up.

ACKNOWLEDGEMENT

We would like to thank Department of Fisheries for their help to conduct histopathology. We are indebted to Mr. Rahul Ranjan, Mr. Manoj Thagunna, and Bishow Raj Dawadi from the Agriculture and Forestry University for their valuable guidance throughout the study.

REFERENCES

1. Kim, H. S., Kim, S., Kim, K., Choi, K. U., & Kim, J. Y. (2013). Myolipoma of Mesentery: A Case Report. *Case Reports in Pathology*, 2013, 1–4. <https://doi.org/10.1155/2013/823823>
2. Moore, M. O., Richardson, M. L., Rubin, B. P., & Baird, G. S. (2006). Abdominal cavity myolipoma presenting as an enlarging incisional hernia. *Radiology Case Reports*, 1(1), 7–12. <https://doi.org/10.2484/rcr.v1i1.5>
3. Rao, C. M., & Krishna, N. V. V. H. (2011). Surgical Management of Lipoma in a Dog Reproduced with permission of the copyright owner . Further reproduction prohibited without permission . 4(1).
4. Takahashi, Y., Imamura, T., Irie, H., Tanaka, F., Fukushima, J. I., Fukusato, T., Harasawa, A., & Shiga, J. (2004). Myolipoma of the retroperitoneum. *Pathology International*, 54(6), 460–463. <https://doi.org/10.1111/j.1440-1827.2004.01646.x>