



# Pulmonary Alveolar Proteinosis: Conducting the first Whole Lung Lavage in Nepal

A.Uprety<sup>1</sup>, N.Bhatta<sup>1</sup>, R.Shahi<sup>1</sup>, A.Varma<sup>1</sup>, Y.Dhaka<sup>2</sup>, P. Aryal<sup>1</sup>, D.K.Yadav<sup>1</sup>, S.Chaudhary<sup>1</sup>, S.Hamal<sup>1</sup>, S.Chaudhary<sup>1</sup>, D.R.Mishra<sup>1\*</sup>


<sup>1</sup>Department of Pulmonary, Critical Care and Sleep Medicine

<sup>2</sup>Department of Anesthesia and Critical Care, B. P. Koirala Institute of Health Science, Dharan Nepal

## ABSTRACT

A case of Pulmonary Alveolar Proteinosis, probably secondary in etiology, was diagnosed at our institute based on clinical, radiological, and pathological evidence. Patient was planned for conducting whole lung lavage as per the guidelines. With this case, we report the first instance of conducting Whole lung lavage in Nepal and the logistics involved.

**Keywords:** Pulmonary Alveolar Proteinosis, Whole Lung Lavage



This work is licensed under a Creative Commons Attribution 4.0 Unported License.

## INTRODUCTION

Pulmonary Alveolar Proteinosis (PAP) is a well-known but rare disease with a worldwide prevalence of about 6.2 cases per million.<sup>1</sup> The disease, previously having ambiguity about the pathophysiology, is now deemed to be the altered surfactant homeostasis.<sup>2</sup> Diagnosing PAP depends upon the indolent course of disease, relevant radiological feature and bronchoalveolar lavage gross and microscopic findings. The definite management of PAP is Whole Lung Lavage (WLL) initially done in 1963.<sup>3</sup> WLL involves a multi-disciplinary team and single lung ventilation with consideration of due complications. The procedure incidentally had not been done in the country before. We present in this case report our approach to the case, management of logistics and the performance of WLL.

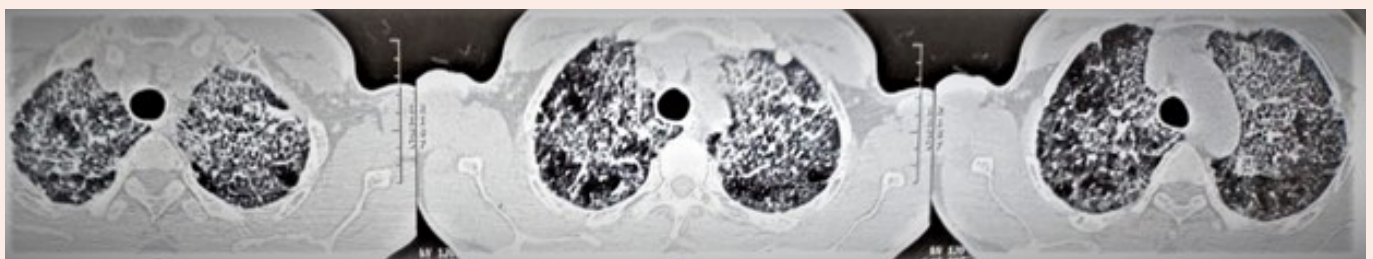
## CASE:

A 57-year non-smoker gentleman, working as "Tunnel-worker" in a foreign country for about 25 years was having

insidious onset of exertional dyspnea from last 2 years, which was more pronounced for the last 3 months. He also had history of Tubercular pleural effusion about 3 years ago, which was managed with anti-tubercular drugs then.

On evaluation he had baseline oxygen saturation of 92% without tachycardia. Oxygen saturation used to fall by 2-3% on mild exertion. Chest examination showed right sided infra-scapular and lower axillary region fine crepitation without cyanosis and clubbing.

Radiological evaluation dated March 2022, showed bilateral lung diffuse ground glass opacity with smooth thickening of interlobular and interlobar septal lines, crazy waving pattern predominantly on the left upper lobe and right middle lobe along with bilateral upper lobe para-septal emphysema, keeping the differential of PAP, organizing pneumonia and amyloidosis.



Corresponding author:

Dr Deebya Raj Mishra

Department of Pulmonary, Critical Care and Sleep Medicine

B P Koirala Institute of Health Sciences

Email: [deebya.mishra@bпкиh.edu](mailto:deebya.mishra@bпкиh.edu) ; [deebyaraj@gmail.com](mailto:deebyaraj@gmail.com)

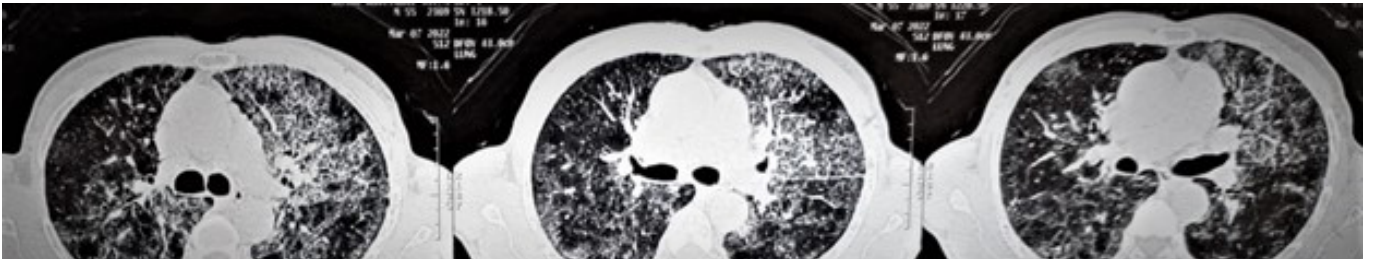


Figure 1: Initial High Resolution Computed Tomography of chest of the patient demonstrating the crazy waving pattern with smooth thickening of the interlobular septa along with ground glass opacity.

Bronchoscopy was done upon which BAL demonstrated rice-water colored fluid, which on cytology demonstrated moderately cellular macrophages, some with finely vacuolated cytoplasm against the foamy amorphous proteinaceous background.

With the indolent course of the disease along with coherent radiological and pathological report, a presumptive diagnosis of secondary PAP was made, and the patient planned for sequential partial lung lavage.

On 18<sup>th</sup> May 2022 AD, we performed the first lung lavage. For this procedure, we did not go for single lung ventilation with

double lumen tube. The patient was intubated with standard 8mm Endotracheal tube (ET) tube and Bronchoscope inserted via the ET tube and sequential lavage was done on left lung. The procedure was done in Pulmonary Intensive Care Unit with the patient under a ventilator and sedation and paralysis managed through intravenous drugs.

However, there was significant spillage of lavage fluid to the contralateral lung. Around 4.5 liters of lavage fluid was used and a return of 3200 ml of milky fluid collected. The fluid was collected in chronological series of lavage, which demonstrated sequential decrement in the sediment content with the process of the lavage.




Figure 2: The turbid fluid collected after the first episode of left upper lobe lavage. The gradual decrement of the thick sediment content can be demonstrated sequentially. The gradient of the sediment is also well demonstrated against the sunlight below.

Following the learnings from this modified lavage procedure, lavage for Right lung was done on 9<sup>th</sup> June 2022. However, this time the procedure was conducted in Operation theatre and under inhalational anesthetics.

This time around the patient was intubated with Double lumen endo-tracheal tube (DLT). The position of DLT was ascertained via bronchoscopy. Following this, single lung ventilation was done with the left lung being kept inflated and the right lung deflated. Sequentially, warm saline was infused in 500 ml aliquots, changing the position of the right lung to

be more dependent, followed by AMBU-bagging and chest percussion of the right lung for 4-5 minutes, fluid was then drained via gravity and suction, again reversing the above mentioned position<sup>4</sup>. In total, 7.5 liters warm normal saline was infused, and the return of 6.5 liters of fluid obtained. The total procedure comprised of 15 cycles of lavage and took about three hours. With single lung ventilation, there was no spillage to the other lung. However, a periodic check of the position of the DLT was made with bronchoscope in between. Following the procedure, the patient was kept overnight under ventilator and extubated the next day.



Figure 3: The lung lavage fluid collected after second episode of right lung using DLT which demonstrates lesser turbidity than the first collection. Like the first collection, there is sequential decrement of the sediment.

The patient had significant improvement in subjective functional capacity and an increase in oxygen saturation,

which rose to 95% from 92% pre-procedure. There were also significant changes improvement in the radiology (Figure 4).

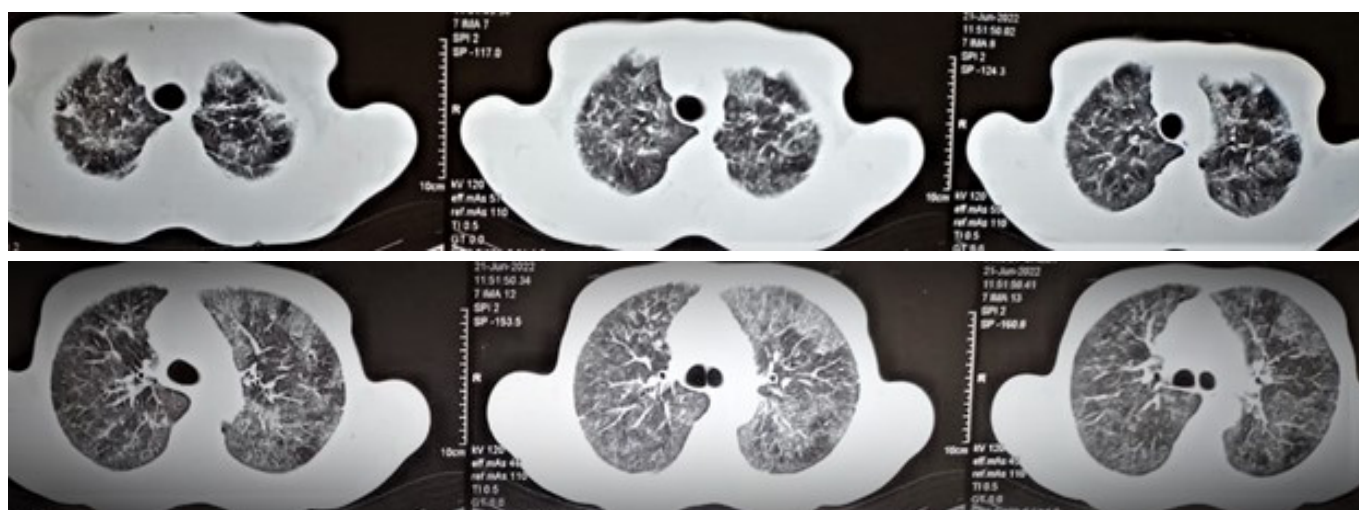


Figure 4: High Resolution Computed Tomography of chest of the same patient after 2 episodes of the lung lavage i.e., left upper lobe and the right lung lavage. The significant improvement in the left upper lobe opacity can be seen.

Following the procedure, the patient was symptomatically better for six months thereafter. However, there was an increase in dyspnea with exertion and a gradual decline in saturation noted after the six-month period.

more on the right side than on the left side. Following this, another sequential lavage was planned. Subsequently, repeat lavage of the right lung was done on the first week of March 2023. Following that lavage, the patient is symptomatically better. Sequential lavage as required is planned for the case. The patient has also been given the option for GM-CSF therapy.

Repeat CT scan showed an increase in ground glass opacity



## DISCUSSION:

The definitive management of Pulmonary Alveolar Proteinosis is well known to be whole lung lavage (WLL) and has been done beforehand with variable long-term outcomes. There has also been use of inhaled and sub-cutaneous GM-CSF (Granulocyte Macrophage-Colony Stimulating Factor), especially on the Autoimmune variant of PAP and PAP not responding to the WLL.

With regards WLL, the logistics involved in the performance of WLL include;

- I. Unit setup: Critical care unit with anesthesia machine (to deliver inhalational anesthesia and mechanical breath), paralyzing agent (vecuronium), and ventilator (needed after the procedure).
- II. Airway setup: Curved blade laryngoscope, DLT (39 Fr), bronchoscope and ventilator circuit.
- III. Fluid setup: 500mL normal saline bottle, intravenous sets, 3 buckets (to accommodate the bottles), water warmer machine, and thermometers (to maintain temperature of 37 degree Celsius).
- IV. Collection setup: 10 plastic bottles, and the labels.
- V. Manpower setup: pulmonary and critical care specialist, anesthesiologist, pathologists, radiologists, nurses, and helpers; all with lot of enthusiasm and patience!

With due consideration in mind, the procedure can be done safely.

Meanwhile, the patient is doing well now with a baseline saturation of 95% in room air, and able to perform all day-to-day activities and is under regular follow up.

Silva et al on 2014, reported a case series of three patients of PAP undergoing two WLL each on Centro Hospitalar São João, Porto, Portugal, under the modified version of the Royal Brompton Hospital (London) technique protocol<sup>5</sup>. They reported that single setting bilateral WLL was time and cost effective as well as safe with rapid patient's functional and clinical improvement. But we did the procedure consecutively on the two lungs, probably because of inertia of the procedure being done first time; but the note of the above-mentioned benefits would be kept on the future ahead. They estimated the saline instillation in each aliquot for left and right lung by calculating two-fifth and three-fifth of the Functional Residual Capacity (FRC) volume, which was our infrastructure related limitations. But, to overcome the barotrauma, we limited the aliquot instillation column to 15 centimeters of water, which was limited up to 40 centimeter of water in the above study.

Campo et al, at 2016, did a global analysis on current practice of WLL therapy for PAP; from which 27 centers responded, 20 of them used to treat adult patients. Like us, under general

anesthesia, 17 out of 20 centers performed WLL in separate episode for the two lungs; lung selection was based on radiological imprint of the insult in majority, which was as in our case, other independent of the lung lesion introduced the naturally smaller left lung first. On 9 centers, degassing (ventilation each lung with cent percent oxygen, followed by negative air way pressure induced lung deflation, maintaining it for 10-15 minutes which leads to absorption atelectasis) of each lung was done prior to lavage, ensuring lavage fluid to reach the alveoli. Like us two-third conducted the procedure in supine position. All centers used saline of 37 degree Celsius, but some centers used supplements such as N-Acetyl-Cysteine, aminophylline and hydrocortisone. Huge variations do occur regarding the amount of warm saline in each aliquot as well as the total lavage fluid amount, but most centers used total saline volume of <18 liters for each lung. Aiding to the efficiency of lavage, 14 (70%) centers were practicing chest percussion, 50% and 20% used manual and mechanical percussion respectively. Average duration of the procedure varied between 6±1 hours.

## CONCLUSION:

Whole Lung Lavage, the definitive management of PAP, is a cumbersome procedure done under general anesthesia in critical care setup. WLL isn't being practiced profoundly in our part of the world, probably because of the paucity of experience of the procedure. With the intent of management of PAP patient at our setup, we performed the first WLL in our country. We further conclude that, WLL can be practiced routinely at our setup, with the above-mentioned logistics.

## REFERENCES:

1. Khan A, Agarwal R. Pulmonary alveolar proteinosis. *Respiratory care*. 2011 Jul 1;56(7):1016-28.
2. Suzuki T, Trapnell BC. Pulmonary alveolar proteinosis syndrome. *Clinics in chest medicine*. 2016 Sep 1;37(3):431-40.
3. Ramirez J, Schultz RB, Dutton RE. Pulmonary Alveolar Proteinosis: A New Technique and Rationale for Treatment. *Archives of internal medicine*. 1963; 112:419-31.
4. Awab A, Khan MS, Youness HA. Whole lung lavage—technical details, challenges, and management of complications. *Journal of Thoracic Disease*. 2017 Jun;9(6):1697.
5. Silva A, Moreto A, Pinho C, Magalhães A, Morais A, Fiuza C. Bilateral whole lung lavage in pulmonary alveolar proteinosis—a retrospective study. *Revista Portuguesa de Pneumologia*. 2014 Sep 1;20(5):254-9.
6. Campo I, Luisetti M, Griese M, Trapnell BC, Bonella F, Grutters J, Nakata K, Van Moorsel CH, Costabel U, Cottin V, Ichiwata T. Whole lung lavage therapy for pulmonary alveolar proteinosis: a global survey of current practices and procedures. *Orphanet journal of rare diseases*. 2016 Dec;11(1):1-0.