



Non-resolving long term Mucormycosis in Post-COVID-19 Patient: A Case Report

Sanjeet Bhattarai¹, Ashish Karthak¹, Naresh Gurung¹, Ashish Shrestha¹, Rakesh Lama¹, Yuvaraj Bhusal¹, Bijay Giri², Sujan Chhetri³, Sanjeet Krishna Shrestha¹.

¹ Department of Pulmonary, Critical Care Medicine and Sleep Medicine, Nepal Medicity Hospital

² Sandwell General Hospital –NHS trust

³ Department of Otorhinolaryngology department, Nepal Medicity Hospital

ABSTRACT:

With the second wave of COVID-19, there was a surge of cases of mucormycosis co-infection in our health center. We would like to present a case of a 53 years old man with COVID-19 positive status who later developed mucormycosis, with invasion of Maxillary sinus, jugular vein, digastric recess in MRI. He was managed with Amphotericin –B injection along with insulin therapy in sliding scale and Posaconazole thereafter for six months. Debridement of the lesion was done along with removal of inferior alveolar process of maxillary process and 3 molar teeth and a premolar tooth of upper left side.

Keywords: COVID-19; Debridement.; Maxillary Sinus; Mucormycosis.



This work is licensed under a Creative Commons Attribution 4.0 Unported License.

CASE REPORT

A 53 year - old male presented with complaints of fever, cough and occasional breathlessness. He was tested COVID-positive in RT-PCR and treated for mild COVID. He was diagnosed with newly diagnosed diabetes mellitus- type 2. His condition deteriorated and oxygen demand increases up to 7 – 10 liters /min along with dyspnea , hence he was treated in COVID ICU with non-invasive ventilation and non-rebreather mask along with Proning sessions. He received tocilizumab and steroids to control his respiratory symptoms. His symptoms became better and oxygen support was reduced up to 4 liters/min and shifted to normal wards after COVID PCR-negative after 6 days.

While in ward , left side of his hard palate become blackish along with occasional mild pain of 4/10 a day before discharge. The blackish hue progressed day by day and pain level increased up to severity of 8/10 in pain scale. ENT surgeons were consulted, who advised for contrast MRI of PNS , orbit and brain.


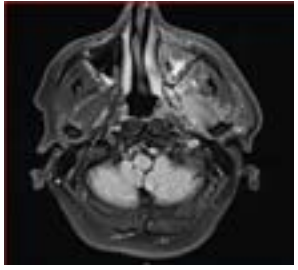

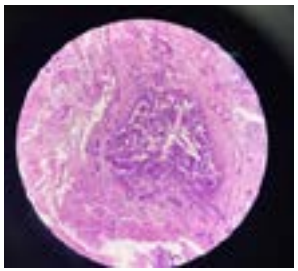
During his stay in hospital, lab reports were normal except magnesium(1.1mg/dl), sodium(125 mmol/L) and blood sugar(455 mg/dl). Electrolytes correction was done and they were in normal range when ENT planned for biopsy of the oral lesion. Subsequently, his MRI was done which showed invasive fungal sinusitis with alveolar process involvement. Biopsy was done and a sample was sent from the oral and sinus antrum area for fungal KOH, histopathology and

culture. Consequently, the histology report showed septate and aseptate hyphae with angle branching. His reports were reviewed by ENT surgeons along with the radiology department.

He was managed with liposomal Amphotericin – B 3 mg / kg on his fourth day of admission and later increased to 5 mg / kg once daily after 5 days of treatment along with nasal flush with amphotericin – B. His high blood sugar was managed with short acting insulin in sliding scale. His condition became better after placement of prosthesis in the void area with the help of a maxillofacial team. Nasogastric tube was removed and he was able to produce normal sound with minimal intonation and was able to eat as normal. He was planned to step down to oral posaconazole tablets after 4 weeks of injectable Amphotericin - B course. Posaconazole was continued for next 6 months with continuous monitoring of his liver and renal functions. Permanent prosthesis was delayed till posaconazole dose was complete for 6 months and in addition to that radiology clearance was also discussed with a multidisciplinary team. Hence, permanent prosthesis was kept with regular follow up. He is able to eat independently and speak clearly with little compromise. Assuming he got cleared off from those miserable mucor, he resumed his

Corresponding author:
Sanjeet Bhattarai
sanjeetbhattarai@gmail.com

work as a social worker taking good care of his health and regular follow up care scheduled. His maxillary defects were renovated with the artificial permanent prosthesis and he is able to eat and drink without regurgitation.

	
<p>Figure 1: Picture of the necrotic lesion in left side of the buccal cavity.</p>	<p>Figure 2: MRI brain showing Post contrast T1 weighted MRI shows heterogeneous enhancement of mucosa of left maxillary sinus. Non-enhancing component also noted in anterior and posterior aspect of thickened mucosa.</p>
	
<p>Figure 3 : X-Ray - COVID Pneumonia</p>	<p>Figure 4: Fungal KOH and Histopathology of the biopsy sample</p>

DISCUSSION

Mucormycosis is an invasive opportunistic fungal infection caused by the filamentous fungi of the order Mucorales of the class Zygomycetes.¹ Depending on the clinical presentation and anatomic site of involvement, Mucormycosis can be of six major clinical types: 1) Rhino - cerebral 2) Pulmonary 3) Cutaneous 4) Gastrointestinal 5) Disseminated 6) Uncommon rare forms such as osteomyelitis, peritonitis, endocarditis, and renal infection.²

Diabetes Mellitus and uncontrolled hyperglycemia are two important risk factors for developing Mucormycosis in the patients who have recovered from Covid-19 infection. Since diabetes mellitus is associated with both Covid-19 infection³ as well mucormycosis⁴, the patients with diabetes are at a particularly higher risk of getting co-infected with mucormycosis and Covid-19. Aside from diabetes, immunocompromised status of the patient, solid organ transplant recipients, iron overload and patients with neutropenia and hematological malignancies are particularly prone to develop mucormycosis.⁵ Therefore, it seems

mandatory to use corticosteroids judiciously in cases of Covid-19 infection as corticosteroids not only increase blood sugar levels, but also cause immunosuppression and all efforts to maintain optimal control of blood sugar levels seem to be important in the prevention of invasive mucormycosis.

Diagnosis of a case of invasive mucormycosis is made by exercising a high index of suspicion. Diagnosis is made by assessing the risk factors and clinical features, early use of imaging modalities and use of laboratory diagnostic methods such as histopathology, direct examination of wet KOH mounts, culture and molecular methods.⁶ On direct examination, the fungus shows aseptate or pauci-septate hyphae with irregular ribbon-like appearance and variable angle of branching, but mostly wide angle branching (90°).⁶

The treatment of invasive mucormycosis includes a multipronged approach. It involves early recognition and discontinuation of underlying risk factors (if possible), early administration of active antifungal agents at optimal doses, complete removal of infected tissues and the use of various adjunctive therapies.^{7,8,9} The first line therapy for mucormycosis includes the lipid formulation of Amphotericin B.¹⁰ Triazoles such as Posaconazole and a newer agent Isavuconazole are also active against the fungus, where Posaconazole is more commonly used as a maintenance or salvage therapy.^{9,10} Surgical intervention, where possible should be done to remove not only the dead necrotic tissues, but also the surrounding healthy-looking tissues as the ability of the Mucorales fungi to spread is high. Surgical debridement is particularly useful in rhino-orbito-cerebral mucormycosis.

CONCLUSION

In our battle against the COVID-19 infection, mucormycosis remains a dangerous, but possibly preventable fungal infection. It can be rapidly fatal, and thus prompt diagnosis and early treatment are invaluable in preventing its fatal complications. In our case, repeated debridement of the lesion along with prolonged antifungal treatment help us to win the battle against mucor. With advent of newer oral antifungals and various obturator prosthesis devices, the patient could resume daily living with little compromise of intonation and voice.

Consent : Signed by patient, Picture Consent – Taken.

Conflict of interest : None

ACKNOWLEDGEMENT:

1. Prof. Ram Kumar Ghimire
2. Prof. Dr. Gopi Aryal
3. Prof. Dr. Toran K.C.
4. Dr. Chandan Barnwal
5. Dr. Sahajan Raj Giri

REFERENCES

1. Kohler Julia R, Hube B, Puccia R, Casadevall A, Perfect John R. Fungi that Infect Humans. *Microbiology Spectrum* 2017. <https://doi.org/10.1128/microbiolspec.FUNK-0014-2016>
2. Goodman NL, Rinaldi MG, et al. Agents of Mucormycosis. *Manual of Clinical Microbiology*, 1991 5th ed Washington.
3. Lima-Martínez Marcos M, Boada Carlos Carrera, et al. COVID-19 and diabetes: A bidirectional relationship. *Clínica e Investigación en Arteriosclerosis* 2021. <https://doi.org/10.1016/j.arteri.2020.10.001>
4. Garg D, Muthu V, Sehgal IS, et al. Coronavirus disease (Covid-19) associated Mucormycosis (CAM): case report and systematic review of literature. *Mycopathologia* 2021. <https://doi.org/10.1007/s11046-021-00528-2>
5. Petrikkos G, Skiada A, Lortholary O, Roilides E, Walsh TJ, Kontoyiannis DP. Epidemiology and Clinical Manifestations of Mucormycosis. *Clin. Infect. Dis* 2012. 10.1093/cid/cir866
6. Skiada A, Pavleas I, Drogari-Apiranthitou M. Epidemiology and Diagnosis of Mucormycosis: An Update. *Journal of Fungi* 2020. 10.3390/jof6040265
7. Tissot F, Agrawal S, Pagano L et al.. ECIL-6 guidelines for the treatment of invasive candidiasis, aspergillosis and mucormycosis in leukemia and hematopoietic stem cell transplant patients. *Haematologica*. 2017. 10.3324/haematol.2016.152900
8. Cornely OA, Arikian-Akdagli S, Dannaoui E et al.. ESCMID and ECMM joint clinical guidelines for the diagnosis and management of mucormycosis. *Clin Microbiol Infect*. 2014. 10.1111/1469-0691.12371
9. Katragkou A, Walsh TJ, Roilides E. Why is mucormycosis more difficult to cure than more common mycoses? *Clin Microbiol Infect*. 2014. 10.1111/1469-0691.12466
10. Chamilos G, Lewis RE, Kontoyiannis DP. Delaying amphotericin B-based frontline therapy significantly increases mortality among patients with hematologic malignancy who have zygomycosis. *Clin Infect Dis*. 2008