



# Diagnostic Yield of Bronchoalveolar Lavage in Nepalese Patients Presenting with Chronic Cough with Normal Radiological Imaging in Tertiary Care Hospital

Rejina Shahi<sup>1</sup>, Narendra Bhatta<sup>1</sup>, Deebya Raj Mishra<sup>1</sup>, Avatar Verma<sup>1</sup>, Augraj Upreti<sup>1</sup>, Prakash Aryal<sup>1</sup>, Devesh Kumar Yadav<sup>1</sup>, Gunjan Regmi<sup>2</sup>

<sup>1</sup>Department of Pulmonary, Critical Care & Sleep Medicine, B.P. Koirala Institute of Health Sciences

<sup>2</sup>Department of Anaesthesia and Critical Care, Birat Medical College and Teaching Hospital

## ABSTRACT

**Background:** Cough is one of the most common symptoms that lead patients to seek medical attention. The diagnosis of chronic cough is complex and challenging. In our setting, a large proportion of patients with cough are treated empirically without a definite diagnosis. Despite investigation and treatment, fiberoptic bronchoscope with bronchoalveolar lavage (BAL) has been shown to be a useful technique in a selected group of patients with unexplained chronic persistent cough. The aim of the study was to determine the diagnostic yield of bronchoalveolar lavage in Nepalese patients presenting with chronic cough with normal radiological imaging.

**Methods:** This was a hospital based cross sectional study. The patients presenting with chronic cough (>8 weeks) with normal radiological imaging were enrolled in the study.

**Results:** 1 patient (2.6%) sputum sample for AFB was negative however BAL sample of the same patient sent for Gene xpert came positive for Mycobacterium Tuberculosis, 5 patients (12.8%) had positive BAL culture, 29 patients (74.4%) had normal cellular pattern in BAL Cytology.

**Conclusion:** Diagnostic yield of BAL was very low for chronic cough in our study. Patient presenting with eosinophilic pattern in BAL had cough variant asthma suffer from non-productive cough in the absence of other asthma symptoms such as dyspnea and wheezing. Thus, though fiberoptic bronchoscope with BAL is indicated in chronic cough of unknown etiology, its diagnostic yield is low.

**Keywords:** Bronchoalveolar lavage, Chronic cough, Fiberoptic bronchoscopy (FOB)



This work is licensed under a Creative Commons Attribution 4.0 Unported License.

## INTRODUCTION:

Patient with chronic cough accounts about 10-38% of respiratory outpatient basis.<sup>1</sup> Chronic cough is a significant health issue due to its substantial impact on quality of life,<sup>2</sup> it causes many clinical challenges.<sup>3,4</sup> Chronic cough is defined as cough more than eight weeks.<sup>5</sup> The most common etiologies for chronic cough are gastro-esophageal reflux, cough-variant asthma, eosinophilic airways disease and upper airways disease.<sup>6</sup> Bronchoscope helps in detecting many diseases that lead to chronic cough in the presence of a normal chest X-ray.<sup>7</sup> It provides many benefits as a diagnostic,<sup>8</sup> but also a therapeutic treatment option for patients with bronchopulmonary diseases.<sup>9</sup> Bronchoalveolar lavage (BAL) is a low-risk tool, which is very popular, commonly used to get diagnostic information.<sup>10</sup> Today, it serves predominantly as a diagnostic tool for the evaluation of lower respiratory tract pathology, it also has therapeutic utility.<sup>11,12</sup>

Chronic cough is under-diagnosed, under-treated and often unrecognized due to a lack of diagnostic services resulting

in nonspecific antibiotic treatment and failure to reach the specific diagnosis by utilizing access specialized pulmonary services. So, delayed diagnosis and treatment of these diseases facilitates increased severity and mortality.

The findings from this study will allow us to understand the etiologies of chronic cough in our population, helping us to direct health care resources and establish diagnostic-therapeutic protocols for evaluation and management of chronic cough in clinical practice in Nepal.

## METHODS

This was a single center, hospital based cross sectional study done from 2nd July 2021 to 1st April 2022 in the department of Pulmonary, Critical Care and Sleep Medicine of B.P. Koirala Institute of Health Sciences (BPKIHS), Dharan, Nepal. Patients presenting with chronic cough (> 8 weeks) with normal

Corresponding author:  
Rejina Shahi  
dr.rejina817@gmail.com

radiological imaging, age >18 years and giving informed consent were enrolled in the study and patients who were current smoker and taking an Angiotensin Converting Enzyme (ACE) inhibitor were excluded from the study. The study protocol was submitted for ethical approval to Institutional Ethical Review Board (IERB) and ethical clearance to conduct the study was obtained before doing the study. For sampling of BAL, bronchoscope was placed in a wedge position within the selected bronchopulmonary segment and normal saline was instilled through the bronchoscope, with a total volume of 100–300 ml and divided into three to five aliquots. After the instillation of each aliquot, instilled saline was generally retrieved using a negative suction pressure <100 mmHg. A 50 ml of BAL sample was sent for cytological examination. Medical documentation, the results of testing of samples collected during FOB: tests send for tuberculosis infection; Acid Fast Bacillus (AFB) smears and Gene xpert, microbiological cultures of bronchial washings and cytologic examinations of BAL were analyzed. Descriptive statistics were calculated using absolute and relative frequencies for categorical variables and means (median) and standard deviation (interquartile range) for numerical ones. Statistical analyses were performed using SPSS version 20.0.0.

**RESULTS**

During the study period, we enrolled 39 patients presenting with chronic cough. The mean age of the patients at bronchoscopy for chronic cough was 38.72 ± 12.25 years, including 26 females and 13 males. The baseline characteristics of patients presenting with chronic cough are shown in table no. 1.

Table 1: Baseline characteristics of the patients presenting with chronic cough

Patient Characteristics	Frequency (n=39)	Percentage %
<b>1. Gender</b>		
Female	26/39	66.7
Male	13/39	33.3
<b>2. Duration of cough</b>		
2-6 months	23/39	59
6months- 1 year	7/39	17.9
>1 year	9/39	23.1
<b>3. Socioeconomic status</b>		
Low	9/39	23.1
Medium	26/39	66.7
High	4/39	10.3
<b>4. Smoking Status</b>		
Never	27/39	69.2
Former	6/39	15.4
Tobacco consumer	2/39	5.1
Both smoker and Tobacco consumer	4/39	10.3

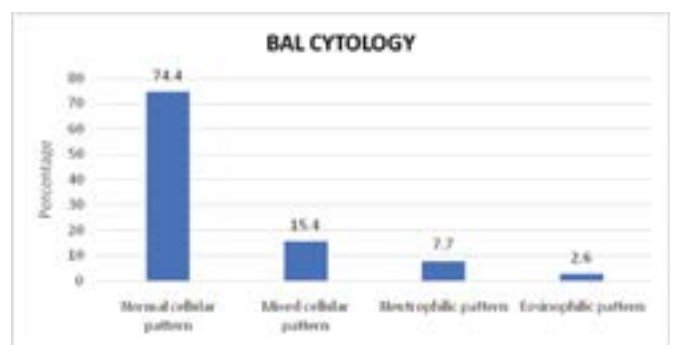
<b>5. Alcohol consumer</b>		
Yes	10/39	25.6
No	29/39	74.4

During Fiberoptic bronchoscopy, bronchoalveolar lavage was taken and sent for tubercular, microbiological and cytological study. BAL for AFB were negative in all patients whereas Gene xpert came out to be positive in 1 patient. 12.8 % patients had positive culture on BAL culture and organisms detected are shown in figure 1. On cytological examination, normal cellular patterns were seen in 74.4%, mixed cellular pattern was seen in 15.4%, neutrophilic cellular pattern and eosinophilic pattern were seen in 7.7 and 2.6% respectively as shown in figure 2.

Figure 1: BAL organism growth in patient presenting with chronic cough



Figure 2: BAL cytology in patient presenting with chronic cough



**DISCUSSION**

Cough is probably the most common of respiratory symptoms and varies in severity from a simple clearing of the throat to paroxysms of severe hacking cough.<sup>7</sup> In the present study, 66.7% (20/39) were middle aged female and most studies have shown a preponderance of females. This may be related to the increased sensitivity of cough reflex in women.<sup>13</sup>

During FOB, we found whitish plaque extending from vocal cord to whole tracheobronchial tree and right upper lobe in one patient with chronic cough, not improving clinically despite being under treatment. It was actively caseating type, swollen, hyperemic bronchial mucosa covered with whitish cheese-like material and partially occluding the right

bronchial lumen. BAL from right upper lobe was done from the endobronchial lesion. While unexpected, one patient in our study turned out to be Gene-xpert positive on BAL despite sputum smear was negative and normal imaging. Involvement of the tracheobronchial tree by tuberculosis is not uncommon. Spillage of infected material into the middle and lower lobes causes localized endobronchial infection in some patients with pulmonary tuberculosis. A study done by Mohammad Golshan<sup>14</sup> in patient with chronic unexplained cough found that in bronchial washing aspirate obtained during bronchoscopy was smear positive for AFB in seven out of the nine patients.

Interestingly in our study, 5 (12%) of patients with positive BAL cultures, FOB revealed no visible airway changes. This result may lead to many different hypothetical conclusions such as contamination or colonization. In one study done by Barnes et al on the utility of FOB in the differential diagnosis of chronic cough, 27 out of 48 FOB procedures included bronchial washings for cultures, and only 3 of them were positive. Furthermore, these three patients were treated with the appropriate course of antimicrobials, which has not improved their cough. According to the authors, this indicates that cultured bacteria have signified contamination, colonization, or were not responsible for cough.<sup>15</sup>

Bronchoalveolar lavage differential cell count have been reported to be typical of specific lung disease.<sup>16</sup> In our study 74.4% (29/39) had normal cellular pattern followed by mixed cellular 15.4% (6/39), neutrophilic 7.7% (3/39) and eosinophilic 2.6% (1/39) respectively. A study done by Marchant JM et al in young patient with chronic cough, neutrophil level of 42.5% and normal cellular level of 31.5% were found in BAL sample.<sup>17</sup>

In patient with chronic cough diagnosed with asthma increased proportion of eosinophil with an elevated mixed pattern with an increased proportion of neutrophil, lymphocyte and mast cells are also reported.<sup>18</sup> Whereas in other studies, in asthmatic patients who were on high-dose corticosteroids, a predominance of neutrophils over eosinophils were seen in the bronchoalveolar lavage fluid, and endobronchial and transbronchial sample.<sup>19</sup> In our study, 2.6% had eosinophilic infiltration in BAL sample. Patients with cough variant asthma suffer from non-productive cough in the absence of other asthma symptoms such as dyspnea and wheezing. This cough is characterized with bronchial hyper-responsiveness and eosinophilia in both sputum and bronchoalveolar lavage, but without bronchoconstriction or airway obstruction.<sup>20</sup> Interestingly, diagnostic yield of BAL cytology was very low and the results were negative for atypical cells in all BAL samples.

Limitations: As the Covid-19 pandemic evolved worldwide and, in our institute, healthcare system and providers struggled to strike a balance between providing medical care to those in need while limiting disease spread to patient and

staff. So, there was limitation in sample size due to Covid-19 during bronchoscopy as it is one of the aerosols generating procedure.

## CONCLUSIONS

Based upon the findings of our study, we conclude that the diagnostic yield of BAL for chronic cough after fiberoptic bronchoscopy add little help us in understanding the etiology, diagnosis and treatment of chronic cough in Nepal. Furthermore, it provides additional contribution in development of clinical cough guidelines.

## REFERENCES

1. Macedo P, Zhang Q, Saito J, Liang Z, Ffolkes L, Nicholson AG, et al. Analysis of bronchial biopsies in chronic cough. *Respir Med.* 2017;127:40–4. [PubMed]
2. French CL, Irwin RS, Curley FJ, Krikorian CJ. Impact of chronic cough on quality of life. *Arch Intern Med.* 1998;158(15):1657–61. [PubMed]
3. Irwin RS, Baumann MH, Bolser DC, Boulet LP, Braman SS, Brightling CE, et al. Diagnosis and management of cough executive summary: ACCP evidence-based clinical practice guidelines. *Chest.* 2006;129:1S-23S. [PubMed]
4. Morice AH, Fontana GA, Sovijarvi ARA, Pistolesi M, Chung KF, Widdicombe J, et al. The diagnosis and management of chronic cough. *Eur Respir J.* 2004;24(3):481–92. [PubMed]
5. Morice AH, Fontana GA, Sovijarvi ARA, Pistolesi M, Chung KF, Widdicombe J, et al. The diagnosis and management of chronic cough. *Eur Respir J.* 2004;24(3):481–92. [PubMed]
6. Faruqi S, Murdoch RD, Allum F, Morice AH. On the definition of chronic cough and current treatment pathways: An international qualitative study. *Cough.* 2014;10(1):1–9. [PubMed]
7. Poe RH, Israel RH, Utell MJ, Hall WJ. Chronic cough: Bronchoscopy or pulmonary function testing? *Am Rev Respir Dis.* 1982;126(1):160–2. [PubMed]
8. Everett CF, Kastelik JA, Thompson RH, Morice AH. Chronic persistent cough in the community: a questionnaire survey. *Cough.* 2007;3(1). [PubMed]
9. Heching M, Rosengarten D, Shitenberg D, Shtraichman O, Abdel-Rahman N, Unterman A, et al. Bronchoscopy for Chronic Unexplained Cough: Use of Biopsies and Cultures Increase Diagnostic Yield. *J Bronchol Interv Pulmonol.* 2020;27(1):30–5. [PubMed]
10. Stanzel F. Bronchoalveolar Lavage. *Princ Pract Interv Pulmonol.* 2013 Jan 1;165. [PubMed]
11. Gibelin A, Parrot A, Fartoukh M, De Prost N. Rare respiratory diseases in the ICU: when to suspect them and specific approaches. *Curr Opin Crit Care.* 2019;25(1):29–36. [PubMed]

12. Lachant DJ, Croft DP, McGrane Minton H, Hardy DJ, Prasad P, Kottmann RM. The clinical impact of pneumocystis and viral PCR testing on bronchoalveolar lavage in immunosuppressed patients. *Respir Med*. 2018 Dec 1;145:35. [Pubmed]
13. Morice AH, McGarvey L, Pavord I. Recommendations for the management of cough in adults. *Thorax*. 2006;61(1):1–24. [Pubmed]
14. Golshan M. Tuberculous Bronchitis with Normal Chest X-Ray Among a Large Bronchoscopic Population. *Ann Saudi Med*. 2002;22(1–2):98–101. [Internet]
15. Barnes TW, Afessa B, Swanson KL, Lim KG. The clinical utility of flexible bronchoscopy in the evaluation of chronic cough. *Chest*. 2004;126(1):268–72. [Pubmed]
16. Davidson KR, Ha DM, Schwarz MI, Chan ED. Bronchoalveolar lavage as a diagnostic procedure: a review of known cellular and molecular findings in various lung diseases. *J Thorac Dis*. 2020;12(9):4991–5019. [Pubmed]
17. Marchant JM, Masters IB, Taylor SM, Cox NC, Seymour GJ, Chang AB. Evaluation and Outcome of Young Children With Chronic Cough. *Chest*. 2006 May 1;129(5):1132–41. [Pubmed]
18. Smith DL, Deshazo RD. Bronchoalveolar lavage in asthma. An update and perspective. *Am Rev Respir Dis*. 1993;148(2):523–32. [Pubmed]
19. Doberer D, Trejo Bittar HE, Wenzel SE. Should lung biopsies be performed in patients with severe asthma? *Eur Respir Rev*. 2015;24(137):525–39. [Pubmed]
20. Sadeghi MH, Morice AH. The Emerging Role of The Eosinophil and Its Measurement in Chronic Cough. *Open Respir Med J*. 2017;11(1):17–30. [Pubmed]