

A Case Study on Demodicosis in Golden Retriever

Pradhan, F. and Paudel, S.

Nepal Polytechnic Institute, Bharatpur, Chitwan

Corresponding Email: flaviapradhan7@gmail.com

Abstract

A six-year-old Golden Retriever dog with a history of alopecia, itching, scratching and erythema all over the body was presented to Veterinary Teaching Hospital, Nepal Polytechnic Institute, Chitwan, Nepal. Dog weighed 44.6 kg was golden brown in colour. On clinical examination mucous membrane, temperature, Heart rate was normal. The eczematous lesions were erythematous and alopecia was seen in the area surrounding the lesions. The case was suspected of parasitic skin infection, and skin scrapping was taken from different affected area until there was a capillary bleeding with the help of scalpel blade after moistening the skin with glycerin. The scraping was treated with 10% KOH until it was submerged after that the solution was gently heated and the supernatant was discarded, and remnants were transferred to slide. A cover slip was placed, and it was examined first under the low power then high power for detail study. Demodex was observed under microscopic examination. The case was diagnosed as patchy demodex infestation with secondary bacterial infection. The lesions were cleaned by medicated ketachonazole shampoo and systemic administration of fixotic advance and Amoxicillin clavunate 375 mg antibiotic was given for secondary bacterial infection. After 2 weeks skin scrapping test was again performed and found negative. There were no red rashes and lesions were slowly healing.

Keywords: Demodicosis, Demodex, Skin scrapping and Alopecia

Introduction

Demodicosis is a common disease in canine practice, caused by a proliferation of *Demodex* mites (Sischo et al., 1989). *Demodex Canis*, *Demodex injai*, and short-bodied *Demodex* mite are the three common forms of *Demodex* mites identified in dogs (Mueller et al., 2012). The principal cause of canine demodicosis is *Demodex Canis*, which lives on hair follicles (Plant et al., 2011). Canine demodicosis is a frequent, non-contagious, inflammatory parasitic dermatosis and is characterized by an abnormally high number of the commensal mite *Demodex Canisin* the hair follicles as well

as sebaceous glands and typically leads to alopecia, follicular papules and pustules, scaling and crusting (Mueller et al., 2012). Although they are part of the healthy dogs' typical Cutaneous microfauna, this condition is brought on by overcrowding and a few other circumstances (Shrestha et al., 2015). However, the factors which allow the development of demodectic mites are not understood well but are thought to be associated with cell mediated immunity defects (Corbett et al., 1975). In the majority of species, demodicosis only affects animals who have been immunosuppressed by another illness (Mueller et al., 2020)

According to the extent of the disease, canine demodicosis can be classified as localized or generalized, as the course and prognosis of the two types of demodicosis are vastly different (Paradis, 1999). Clinical signs of demodicosis include local or generalized baldness, erythema, scale, or crusts accompanied with pustular or papular dermatitis (Kuznetsova et al., 2012) (Mu et al., 2021)(Sharma, 2018). The condition worsens until the animal exhibits baldness, thicker, wrinkled skin, and a "mousy" stench throughout vast portions of its body (Shrestha et al., 2015). Canine generalized demodicosis (CGD) is a skin disease with distinct breed predispositions. Secondary bacterial infections are common (Kuznetsova et al., 2012). In the dog they are transmitted during the first days of life from the dam to the puppies (Greve & Gaafar, 1966). Both types of demodicosis start during puppyhood (3 to 18 months), but adult onset demodicosis (AOD) can also occur. The AOD is a generalized demodicosis even more difficult to treat than juvenile demodicosis (Regmi et al., 2018). Most localized infections heal on their own and without the need for widespread therapy. They can be treated topically by using benzoyl peroxide by massaging it in the direction of hair development. Generalized therapy should be started if the lesions have spread, or you notice a high ratio of juvenile to mature mites. There are different methods for treating generalized mange: amitraz dips, oral ivermectin (Folz et al., 1984), (Paterson et al., 2014)

Management of demodicosis is one of the major challenges in canine practice. Besides the veterinarian, it also bothers owners as it involves more time and money to cure. So, it is important to understand the predisposing factors associated with canine demodicosis so that necessary preventive measures can be taken. There is not much information about canine demodicosis in Nepal (Shrestha et al., 2015). So, this study would add little information on canine demodicosis, and this information can be helpful to canine practitioners as well as dog owners.

Case history and clinical sign

A male Golden retriever dog named Jimmy of 6 years was presented to Veterinary Teaching Hospital, NPI. The dog was brown, weighing 44.6 kg with a Body Condition Score (BCS) 7. The dog had odd skin conditions a few months ago and was experiencing a mite infestation. He was treated with medication for a while and was eating normally.

The clinical signs were red rashes, wound all over the body (figure 1)) including ear and aural haematoma, irritation, itching, alopecia in leg, back of the body (figure 2) and Inflamed, thickened and wrinkled skin without suppuration, black crust (figure 3). The mucous membrane was pink and vital signs of the body were normal (temperature 102.1°C, respiratory rate 28/minute, and heart beat 130 beats/minute).

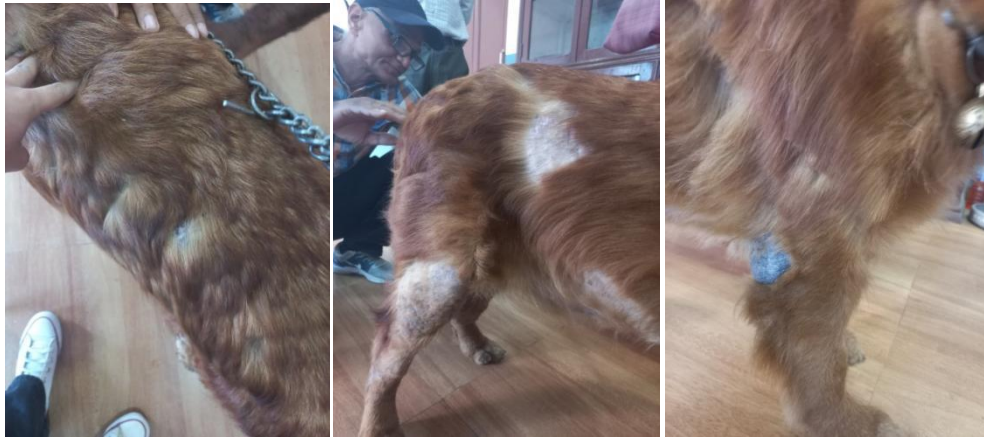

Fig-1: Wound

Fig-2: Alopecia

Fig-3: Crust

Laboratory findings

1. Haematology:

Table 1. Haematology parameters

Test	Result	Normal range	Units
Haemoglobin	9.4↓	11.0-17.0	g/dl
Platelets	120000↓	1,50,000-4,50,000	/ mm ³
Total WBC Count	7650	4,000-11,000	/ mm ³
Differential Count			

Neutrophil	4666	3000-12000	/mm ³
Lymphocyte	2428	1000-4200	/mm ³
Monocyte	306	100-2100	/mm ³
Eosinophil	229	100-1300	/mm ³
Basophil	00	00-100	/mm ³

2. Skin scrapping test

Samples were taken from three distinct afflicted areas, and the skin was scraped in the direction of hair development with the use of a scalpel blade until there was capillary bleeding then a drop of glycerin was put on the center of the glass slide and skin scrapped were transformed into glass slide.

The scrapings were placed in the test tube and 10% KOH was added until it was submerged after that the solution was gently heated with frequent shaking for about 5-10 minutes until all the debris were digested then centrifuged at 3000 rpm for 10 minutes and the supernatant was discarded, and remnants were transferred to slide and observed under microscope.

The sample was examined under microscope (10X) in the Veterinary Teaching Hospital, Diagnostic Laboratory of Nepal Polytechnic Institute. *Demodex canis* was observed (Fig. 4 and 5). The case was diagnosed as patchy *Demodex* infestation with secondary bacterial infection.

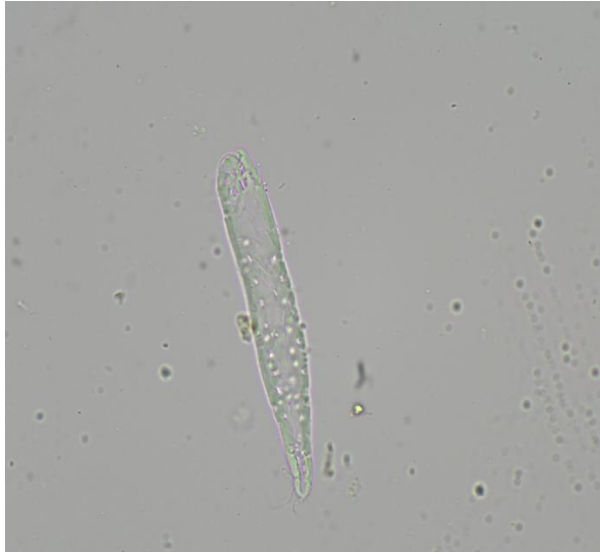

Figure 4. *Demodex spp.*

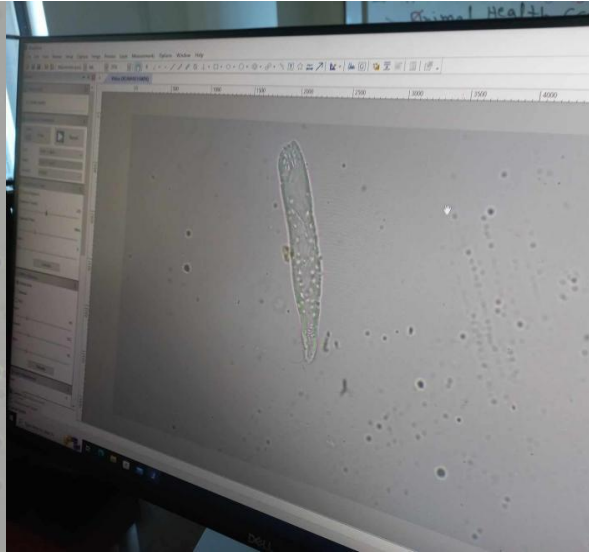


Figure 5. *Demodex spp.*

Treatments

Firstly, trimming of hair was suggested. The ketachlor shampoo was prescribed for cleaning lesion every three days for 3 months and fixotic advance was prescribed to apply all over the lesions every 15 days (about 2 weeks) for 1 months. Amoxicillin clavunate 375 mg were prescribed 2tab twice a day for one week.

After 7days, Amoxicillin clavunate was added for 5 days more. Nutrich tab was given: one tab a day* 60 days.

The itchiness and red rashes were completely cured.

Discussion

*Demodex*mites are considered to be a normal part of the cutaneous micro-fauna in the dog and are transmitted from the bitch to the pups during the first days of life which is called juvenile phase. Puppies raised in isolation after caesarean sections do not have any *Demodex* mites. But in adult phase it is assumed that immune-suppression or a defect in the skin immune system allows for mites to proliferate in hair follicles, sebaceous glands and apocrine sweat glands resulting in clinical signs (Mueller et at., 2011). Mainly two form are present; squamous form and pustular form. In squamous form hair follicles distended with mites and cellular debris, follicular epithelium is atrophic, hyperkeratosis is progressively evident, piece of cornified material exfoliate

from the surface. Hair may be separated/ disintegrated. Sebaceous gland may be atrophied. Hyper pigmentation occurs giving the skin a coppery red colour. The condition-progresses until large areas of the body are affected and animal shows alopecia, thickened or wrinkled skin with mousy odor. Pustular form develops due to the bacterial invasion of dermis. Extensive dermal infiltration of polymorph nuclear leucocytes and lymphocyte, plasma cells etc is seen. Pustules or abscess formation with marked inflammation occurs. This form is usually preceded by squamous form. Erythema, itching, and alopecia was seen which is said to be consistent in demodicosis in a previous study on canine demodicosis (Miller et al., 2012). The proliferation of the mites in patients displaying dermatologic symptoms is thought to be a genetic and/or immunological issue, with lack of appropriate inflammatory response and disease control. The inflammation is often complicated by secondary bacterial infection. Inflammation and irritation caused by mite action in the hair follicles might contribute to the extent of dermatologic lesions and signs (Muller et al., 2012), As a result, the head may shake often, which might lead to an aural haematoma which was similar to that of our case. The bio-chemical report showed decrease in haemoglobin concentration which is in agreement with (Salem. et al., 2020), which says hematological profile of affected dogs showed a significant reduction in Hemoglobin, RBCs associated with insignificant reduction in PCV. Loss of skin protein as a result of *Demodex* infection could cause anaemia, skin scaling and crust. Bacterial invasion results in the recruitment and activation of immune cells, including platelets. Platelets contribute to the resolution of inflammation by a multitude of factors, including interaction. Platelet production are affected by inflammatory processes (Margraf et al., 2019) which was similar in this case.

Conclusion

The dog was found to be recovered after 2 weeks of treatment when the skin scraping test was found negative on microscopic examination. The localized form usually takes time to heal but, in this case red rashes were completely cured but the black crust might take time to be cured. For monitoring the effectiveness of treatment in Demodicosis, skin scraping and hematological examination should be done on regular interval. For the prevention of *Demodex* infestation, medicines used for the treatment of ticks and mites could be used together with the isolation of infected pets. Besides, pet owners should be well educated about the *Demodex* and their control.

Acknowledgements

I would like to express my sincere gratitude to Prof. Dr. D.K. Singh, Dr. Gopal Dev, Mr. Shyam Adhikari, Khema Pandey and Jyoti Chaudhary.

References

- Corbett, R., Banks, K., Hinrichs, D., & Bell, T. (1975). Cellular immune responsiveness in dogs with demodectic mange. *Transplantation Proceedings*, 7(4).
- Folz, S. D., Kakuk, T. J., Henke, C. L., Rector, D. L., & Tesar, F. B. (1984). Clinical evaluation of amitraz as a treatment for canine demodicosis. *Veterinary Parasitology*, 16(3–4). [https://doi.org/10.1016/0304-4017\(84\)90051-7](https://doi.org/10.1016/0304-4017(84)90051-7)
- Greve, J. H., & Gaafar, S. M. (1966). Natural transmission of *Demodex canis* in dogs. *Journal of the American Veterinary Medical Association*, 148(9).
- Kuznetsova, E., Bettenay, S., Nikolaeva, L., Majzoub, M., & Mueller, R. (2012). Influence of systemic antibiotics on the treatment of dogs with generalized demodicosis. *Veterinary Parasitology*, 188(1–2), 148–155. <https://doi.org/10.1016/J.VETPAR.2012.02.023>
- Margraf, A., Ley, K., & Zarbock, A. (2019). Neutrophil recruitment: from model systems to tissue-specific patterns. *Trends in immunology*, 40(7), 613-634.
- Mu, P., Author, C., Mp, S., Ta, S., Siddiqui, M., Gm, C., & Gayal, S. D. (2021). Prevalence of canine demodicosis in and around Parbhani. ~ 548 ~ *The Pharma Innovation Journal*, 12, 548–550. <http://www.thepharmajournal.com>
- Mueller, R. S., Bensignor, E., Ferrer, L., Holm, B., Lemarie, S., Paradis, M., & Shipstone, M. A. (2012). Treatment of demodicosis in dogs: 2011 clinical practice guidelines. *Veterinary Dermatology*, 23(2). <https://doi.org/10.1111/j.1365-3164.2011.01026.x>
- Mueller, R. S., Rosenkrantz, W., Bensignor, E., Karaś-Tęcza, J., Paterson, T., & Shipstone, M. A. (2020). Diagnosis and treatment of demodicosis in dogs and cats: Clinical consensus guidelines of the World Association for Veterinary Dermatology. In *Veterinary Dermatology* (Vol. 31, Issue 1, pp. 5–27). Blackwell Publishing Ltd. <https://doi.org/10.1111/vde.12806>

- Paradis, M. (1999). New Approaches to the Treatment of Canine Demodicosis. *Veterinary Clinics of North America: Small Animal Practice*, 29(6), 1425–1436. [https://doi.org/10.1016/S0195-5616\(99\)50136-8](https://doi.org/10.1016/S0195-5616(99)50136-8)
- Paterson, T. E., Halliwell, R. E., Fields, P. J., Louw, M. L., Ball, G., Louw, J., & Pinckney, R. (2014). Canine generalized demodicosis treated with varying doses of a 2.5% moxidectin+10% imidacloprid spot-on and oral ivermectin: Parasiticidal effects and long-term treatment outcomes. *Veterinary Parasitology*, 205(3–4). <https://doi.org/10.1016/j.vetpar.2014.08.021>
- Plant, J. D., Lund, E. M., & Yang, M. (2011). A case-control study of the risk factors for canine juvenile-onset generalized demodicosis in the USA. *Veterinary Dermatology*, 22(1). <https://doi.org/10.1111/j.1365-3164.2010.00922.x>
- Regmi, B., Regmi, B., & Thakur, B. (2018). *Type: Double Blind Peer Reviewed International Research Journal*. 18. <https://www.researchgate.net/publication/331047073>
- Salem, N. Y., Abdel-Saeed, H., Farag, H. S., & Ghandour, R. A. (2020). Canine demodicosis: Hematological and biochemical alterations. *Veterinary world*, 13(1), 68.
- Sharma, P. (2018). Epidemiological, clinico-haematological and therapeutic studies on canine demodicosis. *Journal of Dairy, Veterinary & Animal Research*, 7(3). <https://doi.org/10.15406/jdvar.2018.07.00200>
- Shrestha, D., Thapa, B., Rawal, G., Dhakal, S., & Sharma, B. (2015). Prevalence of Demodectic Mange in Canines of Kathmandu Valley having Skin Disorder and Its Associated Risk Factors. *International Journal of Applied Sciences and Biotechnology*, 3(3), 459–463. <https://doi.org/10.3126/ijasbt.v3i3.13218>
- Sischo, W. M., Ihrke, P. J., & Franti, C. E. (1989). Regional distribution of ten common skin diseases in dogs. *Journal of the American Veterinary Medical Association*, 195(6).