

Original Article

Fractional Ablative Carbondioxide Laser Resurfacing for Acne Scars - A single Centered Study

Rima Shrestha¹, Anupama Karki²

¹Department of Dermatology & Venereology, KIST Medical College and Teaching hospital, Lalitpur, Nepal

²Department of Dermatology & Venereology, National Academy of Medical Sciences, Kathmanu, Nepal

ABSTRACT

Introduction: Pulsed carbon dioxide laser devices are considered highly effective treatment options for skin resurfacing. The aim of this study was to evaluate the efficacy and safety of an ablative 10,600-nm carbon dioxide fractional laser system on moderate to severe acne scars.

Materials and Methods: Forty participants (Fitzpatrick skin types III-IV) ranging from the age group of 25-45 who had moderate to severe acne scars were included in the study. CO₂ Fractional laser was used, Unit: eCO₂ Lutronic Korea; FDA approved, in 3 sessions at one month interval and 4th and 5th sessions at the interval of 2 months. Comparison was done on a monthly basis for the improvement of scars at one monthly interval and any other symptoms like pain, recovery time for wound healing and complications of laser like hyperpigmentation were noted by asking the patient to fill up a questionnaire.

Results: All the patients completed the treatment. At the end of the session participants experienced a reduction in the size of the scars. At the first laser session, they presented 10-25%, at the second session 20-45% and at the third session 30-60%. All participants felt an ascending improvement rate during and after the course of treatment. An average improvement of 71% was observed. Twelve of sixteen patients showed mild erythema which was transient and recovered at its own.

Conclusions: Fractional CO₂ laser ablation provides a safe and effective treatment of moderate to severe facial acne.

Keywords: Ablative; Acne; Laser; Scar

Copyright: This is an open-access article distributed under the terms of the Creative Commons Attribution 4.0 International License, which permits unrestricted use, distribution, and reproduction in any medium, provided the original author and source are credited.

Correspondence:

Dr. Rima Shrestha, MD
Associate Professor, Department of Dermatology
KIST Medical College and Teaching hospital, Lalitpur, Nepal
ORCID ID: 0000-0002-7103-107X
Email: rimashrestha00@yahoo.com

Submitted: 5th January 2018

Accepted: 16th August 2018

Published: 1st December 2018

Sources of Support: None

Conflict of Interest: None



Citation: Shrestha R, Karki A. Fractional ablative carbondioxide laser resurfacing for acne scars - A single centered study. Nep Med J 2018;2:79-81. DOI: <http://dx.doi.org/10.3126/nmj.v1i2.21582>

INTRODUCTION

Acne is a common skin condition especially in adult age group¹. Its course varies according to its severity, mishandling and management.² Acne scars are quite common and lead to disfigurement and psychosocial problems.^{3,4} A recent, comprehensive and functional scheme was proposed, whereby scars are classified as rolling, ice-pick, shallow boxcar, and deep boxcar. Various procedures like chemical peeling, derma abrasion,

laser resurfacing, punch excision, elevation and scar revision may have to be sorted to improve the appearance with variable results and outcomes.^{4,5}

Ablative therapies with CO₂ fractional laser has been effectively used for the treatment of acne scars. High-energy, short duration exposure to 10,600 nm CO₂ laser light vaporizes intra and

Table 1. Grade of improvement treated with Fractional ablative carbon dioxide laser resurfacing for acne scars¹⁰

Grade	Percentage	Improvement Remarks
Grade I	0-25%	Minimal or no improvement
Grade II	26-50%	Moderate improvement
Grade III	51-75%	Marked improvement
Grade IV	>75%	Near total improvement

Table 2: Number of laser procedures and percentage of scar Improvement

Evaluators	First sitting	Second Sitting	Third Sitting
Patient	10-25 %	20-45%	30-60%
Dermatologist	10-20%	25-50%	30-70%

extracellular water, causing tissue ablation, rapid enough to limit dermal injury and reduce the likelihood of additional scarring.⁶ Ablative laser therapies with CO₂ fractional laser and erbium-doped yttrium aluminum garnet (Er:YAG) lasers are well accepted treatments for post acne scars.⁷ Use of these lasers in Asian patients was discouraged due to delayed recovery time, edema, prolonged erythema, post-inflammatory pigmentations and scarring.^{8,9} In this study, we examined the efficacy and safety of ablative CO₂ fractional laser, (10,600nm) in 40 patients with mild to moderate acne scars.

MATERIALS AND METHODS

The study was conducted in Nepal skin hospital, Bijulibazar from March 2012 to September 2013. Permission from the ethical committee was obtained. A series of forty participants (Fitzpatrick skin types III–IV) ranged 25-45 years-old who had moderate to severe acne scars have been included. Participants with the following criteria were excluded from the study: active infections, history of keloid scar formation, known allergies to lidocaine, recent accutane use, smoking, pregnancy or cosmetic procedures in the treatment area within last 2 months.

The treatment areas were cleansed (debris, including dirt, makeup and powder) by using a mild cleanser and 70% isopropyl alcohol. Lidocaine 2.5% and prilocaine 2.5% cream (Lidocaine-p cream) were applied under close dressing on the entire face. After 40 minutes of application, the anesthetic cream was gently removed with clean gauze.

CO₂ Fractional laser was used, Unit: eCO₂ Lutronic Korea; FDA approved, in 3 sessions at one month interval and 4th and 5th sessions at the interval of 2 months. Photographic documentation using identical camera settings, lighting, and patient positioning were obtained at baseline, before each treatment session, and 3 months after the final treatment session. We compared improvement rate of scars after every sessions at 1 month interval. Adverse effects and recovery times were recorded in each session and visit. We had two questionnaire sheets, one of them filled by the participants and the other one by another dermatologist who evaluated the photographs. We requested them to fill the questionnaire sheets about the scale of clinical improvement as fair (<30%), good (30%-60%) and excellent (>60%).

Immediately, after each treatment session, they also were asked to rate the pain associated with treatment on a 10-point pain scale (0 = very light to 10 = very severe). Finally, data were analyzed

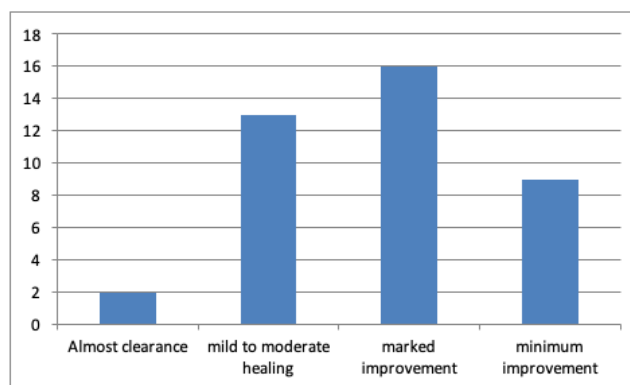


Figure 1: Grades of improvement after 1st laser session.

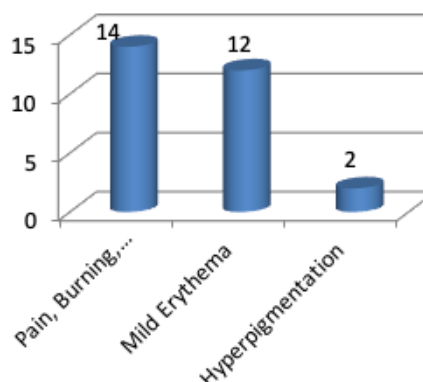


Table 2: Side-effects of lasers procedure in the studied population.

and the results were confirmed. The baseline features such as the texture, score, scars were noted using a skin analyser. In addition to it, two dermatologists independently compared the digital photos for clinical evaluation of the acne scars and graded according to table 1.

Statistical Analysis

Data were presented as Kendall test for comparison of the three sessions. SPSS software version 18 was used. In the comparison of the different sessions for each participant, we estimated a P-value at most <0.05, consequently, we confirmed the significant difference of statistical analysis in this clinical trial.

RESULTS

A total of 40 patients were included in the study as 40 patients completed the treatment session. Among them 29 (72.5%) were female and 11 (27.5%) were male patients, completed the treatment sessions. They have a mean age of 21 years.

At the end of the session participants experienced a reduction in the size of the scars. After the first laser session, they presented 10-25%, at the second session 20-45% and at the third session 30-60 percent reduction in the size of the scars as shown in bar diagram 1. All participants felt an ascending improvement rate during and after the course of treatment. The fractional CO₂ laser showed significant reductions in the scars compared to baseline according to the dermatologist opinion.

All participants tolerated the treatment sessions quite well. The

mean pain score was 2.2 (a score of 2.5 is easily tolerated). All of them had an improvement in their acne scarring but of variable grade. Two of the patients showed almost clearance of scarring (grade 4), while a large number (13 patients) showed mild to moderate healing of acne scars grade 2 and 16 patients showed marked improvement (grade 3) and 9 patients showed minimal improvement. An average improvement of 70% was observed. Among the studied population, 10- 20% achieved near total clearance of scarring after 1st sitting, whereas 30-70% required 3 sessions to reach near total clearance of scarring. (Table 2)

Side effects (14 patients) included mild pain or burning during laser treatment, post-treatment crusting, scaling and transient pigmentation (fig.2). Twelve of sixteen patients showed mild erythema which was transient and recovered at its own. Two of these had hyperpigmentation. It is interesting that, the initial edema and erythema improved after 2-3 days, but there was remarkable superficial crusting which remained for 4-7 days so they could return to work after 4days after applying sunscreen and moisturizing lotion. There were no pigmentation changes, infections and other immediate adverse effects. No long-term side effects were observed after 6 months of follow-ups and improvement continued after the last session.

DISCUSSION

This study demonstrated the efficacy of fractional CO₂ laser treatments for moderate to severe acne scarring. Final results in participants and dermatologist evaluation was 20%-70% and 30%-70%, respectively. The fractional CO₂ laser is useful in the treatment of scars, wrinkles, nevus, sun damaged skin and etc^{5,6}.

REFERENCES

1. Fife D, Clin J. Practical evaluation and management of atrophic acne scars: tips for the general dermatologist. *Aesthet Dermatol* 2011;4(8):50-7.
2. Taub AF, Garretson CB. Treatment of acne scars of skin types ii to v by sublative fractional bipolar radiofrequency and bipolar radiofrequency combined with diode laser. *J Clin Aesthet Dermatol* 2011;4(10):18-27. [Crossref](#)
3. Woo SH, Park JH, Kye YC. Resurfacing of different types of facial acne scar with short-pulsed, variable pulsed, and dual-mode Er: YAG laser. *Dermatol Surg* 2004;30:488-93. [Crossref](#)
4. Grevelink JM, White VR. Concurrent use of laser skin resurfacing and punch excision in the treatment of facial acnes carrying. *Dermatol Surg* 1998;24:527-30. [Crossref](#)
5. Jacob CI, Dover JS, Kaminer MS. Acne scarring: a classification system and review of treatment options. *J Am Acad Dermatol* 2001;45:109-17. [Crossref](#)
6. Zaenglein AL and Thiboutot DM. *Dermatology*. In: Bologna JL, Jorizzo JL and Rapini R (Eds). *Acne Vulgaris*. Mosby Publishing; 2008. pp213-4.
7. Tay YK, Kwok C. Minimally ablative erbium: YAG laser resurfacing of facial atrophic acne scars in Asian skin: a pilot study. *Dermatol Surg* 2008;34:681-5. [Crossref](#)
8. Hasegawa T, Matsukura T, Mizuno Y et al. Clinical trial of a laser device called fractional photo-thermolysis system for acne scars. *J Dermatol Treat* 2006;33:623-7. [Crossref](#)
9. Lee HS, Lee JH, Ahn GY, et al. Fractional photo-thermolysis for the treatment of acne scars: a report of 27 Korean patients. *J Dermatol Treat* 2008;19:45-9. [Crossref](#)
10. Hsiao P, Lin Y, Huang C. Efficacy and safety of a single treatment using 10,600 nm carbon-dioxide fractional laser for mild-to-moderate atrophic acne scars in asian skin. *Dermatologica Sinica* 2013;31:59-63. [Crossref](#)
11. Gozali M, Zhou B. Effective treatments of atrophic acne scars. *J clin Aesthet Dermatol* 2015;8:33-40. [Crossref](#)

Theoretically, the mechanisms of action of laser resurfacing include tissue ablation, immediate collagen shrinkage, and dermal collagen remodeling. Columns of microscopic ablated epidermis and dermis after treatment with Fractional CO₂ laser may result in macroscopic epidermal regeneration as evidenced by clinical improvement of scar and skin texture.⁷

No evidence of clinical infection occurred during the study period. The participants returned back to work after 4 days. Considering the recovery time, adverse effects and outcome, Fractional CO₂ laser can be an alternative treatment technique for acne scar. There are many options for the treatment of acne scarring including chemical peeling, dermabrasion, punch techniques, fat transplantation, other tissue augmenting agents, needling, subcision and combined therapy. Various modalities have been used to treat the patient's scar, but with limited efficacy and problematic side effects have restricted their applications.

For acne scars CO₂ fractional lasers has been used worldwide with 50-70% improvement in scars individual scars which vary widely in type and depth different treatment approaches are recommended. Hence the treatment is to be individualized according to the patients need.¹¹

CONCLUSIONS

Fractional CO₂ laser ablation provides a safe and effective treatment of moderate to severe facial acne. It has very less side effects and patient tolerate very well. Hence, fractional CO₂ laser ablation should be the recommendation to the patient with facial scar.