

FUNCTIONAL OUTCOME OF ACROMIOCLAVICULAR JOINT DISLOCATION TYPE III INJURIES TREATED WITH HOOK PLATE

Vijayendra Adhikari,¹ Prasamsha Sitaula,¹ Sumi Singh,² Praphulla Shrestha,¹ Pralhad K Chalise,¹ Anil K Mishra,¹ Ramesh Prasad Singh¹

¹Department of Orthopaedics, Nepal Medical College and Teaching Hospital, Attarkhel, Gokarneshwor-8, Kathmandu, Nepal, ²School of Medicine and Biomedical Sciences, University of New York, Buffalo, USA

ABSTRACT

The acromioclavicular joint (AC) dislocation is a complex injury due to the disruption of ligaments and joints, leading to instability and pain. Rockwood type III injuries remain controversial, so clinical evaluation should be taken into consideration before deciding the treatment modalities. The study aimed to evaluate the functional outcome of AC joint dislocation type III injuries treated with a hook plate. A total of 30 patients with AC joint dislocation type III injuries were treated with open reduction and fixation with hook plate during a period of 18 months. The functional outcome was evaluated using constant murley score, the mean score of which was 82 (58-96). There were 7 (23.33%) cases of plate impingement and the symptoms was improved after plate removal. The hook plate is a good fixation device for the treatment of AC joint dislocation -Rockwood type III injuries with minimal complications, as it is a simple procedure, with good functional outcome, without ligamentous procedure and the only drawback is second surgery for implant removal.

KEYWORDS

Acromioclavicular joint (AC) dislocation, hook plate, injuries

Received on: June 27, 2024

Accepted for publication: August 24, 2027

CORRESPONDING AUTHOR

Dr. Vijayendra Adhikari
Assistant Professor,
Department of Orthopaedics,
Nepal Medical College Teaching Hospital
Attarkhel, Gokarneshwor-8, Kathmandu, Nepal
Email: vijayfrnd@live.com
Orcid No: <https://orcid.org/0000-0002-5670-8214>
DOI: <https://doi.org/10.3126/nmcj.v26i3.69887>

INTRODUCTION

The acromioclavicular joint (AC) dislocation is a complex injury due to disruption of ligaments and joints, leading to instability and pain.¹ AC joint dislocation occurs due to direct impact or forces applied around the shoulder joint resulting in mild sprain to complete disruption of the joint. The most commonly used Rockwood classification is based upon displacement of the joint on radiographs ranging from type I to VI injuries.² This classification categorizes injuries and guides the management of AC joint dislocation, although it has limitations like the degree of pain and functional impairment experienced by patients may not be related to the degree of displacement.² While type I and II injuries are managed conservatively with slings and surgical treatment like joint fixation with pins, tension band wiring, screw and washer, suspensory fixation devices and clavicular hook plate for type IV-VI injuries, the appropriate treatment for type III injuries remains controversial.³ So, clinical evaluation should be taken into consideration before deciding the treatment modalities for type III AC joint dislocation injuries.

The study aimed to evaluate the functional outcome of AC joint dislocation type III injuries treated with a hook plate, without ligament reconstruction.

MATERIALS AND METHODS

This is a prospective observational study that was conducted in the Department of Orthopaedics of Nepal Medical College Teaching Hospital. A total of 30 patients with AC joint dislocation Type III injuries were treated with open reduction and fixation with hook plate during a period of 18 months (May 2022 – November 2023). Out of 30 patients, 27 (90%) were males and 3 (10%) were females. The patients were in between the age group of 20 to 62 years with an average age of 32 years. The most frequent cause of injury was road traffic accidents, followed by fall injuries. In all patients, radiographic analysis of an Anteroposterior and Stress view was done and classified according to Rockwood classification for AC joint dislocation injuries.

The average duration of surgical intervention from the day of injury was 4.3 ± 2.34 days. The duration ranged from 1-12 days after injury due to variation in duration of injury to presentation.

Surgery was performed in beach chair position, under general or regional anesthesia, through a

transverse skin incision along the distal clavicle to acromion. The AC joint was visualized, reduction done and fixed with hook plate, tip of hook plate was placed in posterior inferior of the acromion and screws over lateral end of clavicle, without repair or reconstruction of ligament. The AC joint reduction was confirmed intra operatively by C-arm fluoroscopy before the closure.

Postoperatively, the arm was immobilized for 2 weeks and pendulum exercises were started from the next day of surgery. After suture removal at 2 weeks, patients were allowed for daily activities but overhead activity was avoided. The constant Murley shoulder score⁴ was used to assess the functional outcome at 6 weeks, 12 weeks, 18 weeks and 24 weeks. The removal of the implant was advised after 6 months of surgery to all patients.

RESULTS

Few patients experience some degree of pain or discomfort initially, but all patients returned to pre-injury activity level during the final follow-up. The functional outcome was evaluated using constant murley score, mean score was 82 (58-96). There were 7 (23.3%) cases of plate impingement and symptoms was improved after the plate removal (Fig. 1).

Minimum time of implant removal was 6 months, whereas maximum was 10 months after surgery, hook plate was removed in 25(83.3%) cases, whereas 5 (16.66%) patients were lost in follow-up (Fig. 2 a-c). Two patients had a subluxation of AC joints after hook plate removal but clinically there was no tenderness and patients were able to do daily activities without any discomfort.

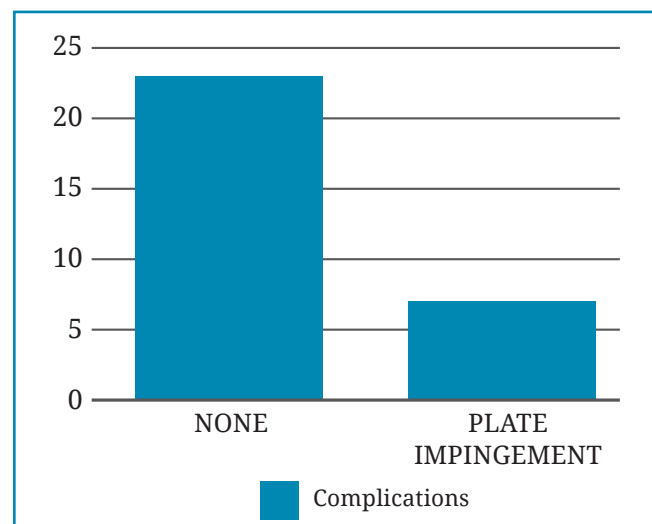


Fig. 1: Complications

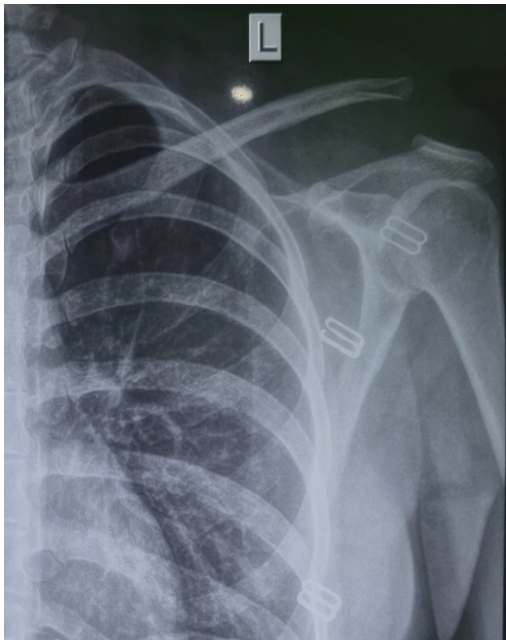


Fig.2a: Left AC joint dislocation

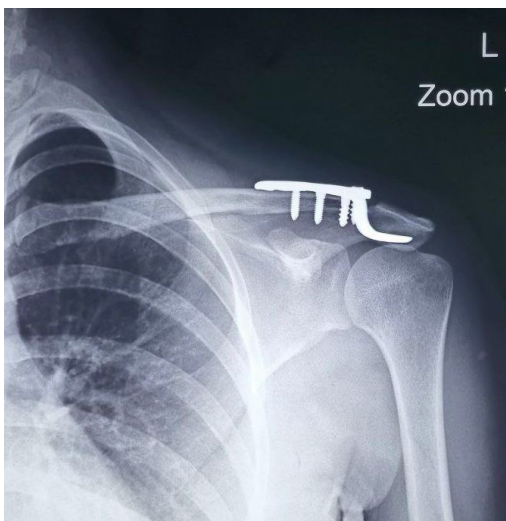


Fig. 2b: Hook plate fixation

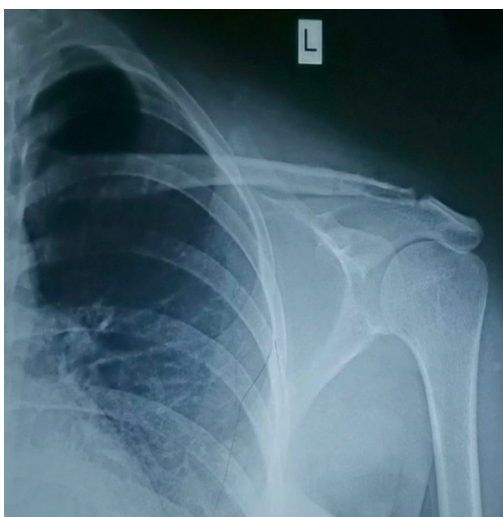


Fig. 2c: Implant removal

DISCUSSION

The approach to the management of AC joint dislocation, in Rockwood type III injuries, there is still no consensus towards conservative or Surgical treatment.³ Conservative treatment has some drawbacks like pain, cosmetic deformity and difficulty in daily activities later on whereas there is extensive description of surgical techniques but still consensus on the optimal fixation or device is still lacking.^{5,6} The use of K wire with or without tension band wiring, smooth or threaded pins fixation has been phased out due to complications such as pin breakage and migration.⁷ The Transclavicular coracoid fixation, with or without ligament reconstruction has been associated with screw misplacement, pull out, irritation and re-dislocation.⁸

The weaver and Dunn procedure, transfer of coraco-acromial ligament is characterized by weak strength, incomplete reduction or instability and loss of reduction or recurrence rate is approximately 29%.⁹ Arthroscopic suspensory loop fixation is considered effective for fixation but have a higher complication like loss of reduction, adhesive capsulitis and it is technically demanding procedure.¹⁰ The hook plate closely resembles to physiological mechanical strength, stiffness and preserved biomechanics of AC joint, allowing early movement but is associated with common complication like subacromial impingement, osteolysis, bone erosion, implant failure and redislocation.¹¹⁻¹⁴ The main aim of surgery is to make the patients return to their preinjury level as soon as possible. In our study, all the patients returned to their normal daily activities with a mean constant murley score of 82 (58-96), which is comparable to Kumar *et al*¹⁵ study where they obtained excellent and good results with hook plate fixation without coracoclavicular ligament reconstruction. The main drawbacks of hook plate are second surgery, subacromial impingement, acromial osteolysis and loss or reduction.¹³⁻¹⁴

Our study shows, 7 (23.33%) patients had plate impingement symptoms, which was improved after the plate removal. So, early removal of plate after healing is an effective way to decrease the complications. Two patients had loss of reduction after implant removal but it was not affected in their daily activities, as several studies have shown that the hook plate insertion had achieved good clinical outcomes despite loss of reduction.

In conclusion, hook plate is a good fixation device for the treatment of AC joint dislocation

Rockwood type III injuries with minimal complications as it is simple procedure, with good functional outcome, without ligamentous procedure and the only drawback is second surgery for implant removal.

The limitations of the study were a relatively small sample size and no comparison with other surgical methods.

Conflict of interest: None

Source of research fund: None

REFERENCES

1. Lemos M. The evaluation and treatment of the injured acromioclavicular joint in athletes. *Am J Sports Med* 1998; 26: 137-44.
2. Phillips A, Smart C, Groom A. Acromioclavicular dislocation: conservative or surgical therapy. *Clin Orthop Rel Res* 1998; 353: 10-7.
3. Spencer EJ. Treatment of grade III acromioclavicular joint injuries: a systematic review. *Clin Orthop Rel Res* 2007; 455: 38-44.
4. Constant C, Murley A. A clinical method of functional assessment of the shoulder. *Clin Orthopaedics Related Res* 1987; 214: 160-4.
5. Fung M, Kato S, Barrance P, Elias J, McFarland E, Nobuhara K. Scapular and clavicular kinematics during humeral elevation: a study with cadavers. *J Shoulder Elbow Surg* 2001; 10: 278-85.
6. Domos P, Sim F, Dunne M, White A. Current practice in the management of Rockwood type III acromioclavicular joint dislocations - National survey. *J Orthop Surg* 2017; 25: 2309499017717868.
7. Hackenburch W, Regazzoni P, Schwyzer K. Surgical treatment of lateral clavicular fracture with the clavicular hooked plate. *Z Unfallchir Versicherungsmed* 1994; 87: 145-52.
8. McConnell A, Yoo D, Zedro R. Methods of operative fixation of the acromion-clavicular joint: a biomechanical comparison. *J Orthop Trauma* 2007; 21: 248-53.
9. Weinstein D, McCann P, McIlveen S. Surgical treatment of complete acromioclavicular dislocations. *Am J Sports Med* 1995; 23: 324-31.
10. Clavert P, Meyer A, Boyer P, Gastaud O, Barth J, Duparc F. Complication rates and types of failure after arthroscopic acute acromioclavicular dislocation fixation. Prospective multicenter study of 116 cases. *Orthop Traumatol Surg Res* 2015; 101: S313-6.
11. Charity R, Haidar S, Ghosh S, Tillu A. Fixation failure of the clavicular hook plate: a report of three cases. *J Orthop Surg* 2006; 14: 333-5.
12. Meda P, Machani B, Sinopidis C, Braithwaite I, Brownson P, Frostick S. Clavicular hook plate for lateral end fractures-a prospective study. *Injury* 2006; 37: 277-83.
13. Monsaert A, Steenbrugge F, Van Damme R, Claus B, De Witte E, Van Nieuwenhuyse W. Repair of complete acromioclavicular separations: hook-plate versus K-wiring. In: *Folia traumatologica Lovaniensia* 2003; Leuven, Belgium: 14-7.
14. Nadarajah R, Mahaluxmivala J, Amin A, Goodier D. Clavic-ular hook-plate: complications of retaining the implant. *Injury* 2005; 36: 681-3.
15. Kumar N, Sharma V. Hook plate fixation for acute acromioclavicular dislocations without coracoclavicular ligament reconstruction: a functional outcome study in military personnel. *Strategies Trauma Limb Reconstr* 2015; 10: 79-85.