

TOPOGRAPHY AND INDEXING OF THE NUTRIENT FORAMINA OF THE ADULT LONG BONES

Umeshwar Prasad Thakur,¹ Pranav Kumar Yadav,² Brijendra Kumar Sah,³ Ram Jiban Prasad,¹ and Tirtha Narayan Shah⁴

¹Department of Clinical Anatomy and Cell Biology, Karnali Academy of Health Sciences, Chandannath-4, ²Department of Anatomy, Universal College of Medical Sciences and Teaching Hospital, Ranigaon, Bhairahawa, ³Department of Radiology, Nepalgunj Medical College and Teaching Hospital, Kohalpur, Banke, ⁴Department of Biochemistry, Karnali Academy of Health Sciences, Chandannath-4, Jumla, Nepal

ABSTRACT

The primary source of blood supply for long bones comes from the nutrient arteries that pass through the nutrient foramen. Understanding the location and structure of these foramina is important in surgical procedures to ensure that the bone's blood supply is not disrupted. To study the morphology and topography of nutrient foramina and to determine the foraminal index of the upper and lower limb long bones. The long bones of the upper and lower limbs including 47 humeri, 38 radii, 38 ulnae, 53 femurs, 57 tibiae, and 44 fibulae were studied. The number and position of primary nutrient foramina were noted and the foraminal index was calculated. Results showed that 82.9% of the humeri had a single nutrient foramen, and 17.0% had double foramina. For the radii, 97.4% had single nutrient foramen and 2.6% had double foramina. A single nutrient foramen was observed in all the ulnae. In the lower limb bone, the femurs had 41.5% of single nutrient foramen, 56.6% had double foramina and only 1.9% had triple nutrient foramina. The tibiae showed 93.0% of the single nutrient foramen and only 7.0% had double foramen. In fibulae, only one nutrient foramen was seen. The mean foraminal index was 57.26 for the humerus, 34.82 for the radius, and 39.32 for the ulna. Similarly, the mean foraminal index of the femur was 44.73, the tibia was 32.32 and the ulna was 46.18. Understanding the location of foramina is crucial in maintaining bone vasculature during surgical procedures, which can improve the success rates of bone grafting, fracture fixation, and replacement surgeries involving the shoulder, elbow, and knee joints.

KEYWORDS

Foraminal index, nutrient foramen, nutrient artery, morphometry

Received on: May 21, 2023

Accepted for publication: August 15, 2023

CORRESPONDING AUTHOR

Dr. Umeshwar Prasad Thakur,
Lecturer,
Department of Clinical Anatomy and Cell Biology,
Karnali Academy of Health Sciences,
Chandannath-4, Jumla, Nepal
Email: sharmaumeshck@gmail.com
Orcid No: <https://orcid.org/0009-0000-9337-2003>
DOI: <https://doi.org/10.3126/nmcj.v25i3.58733>

INTRODUCTION

Bones are essential components of the human skeleton and provide the structure and support for the body. They are made up of living connective tissues and are hardened by calcium.¹ Long bones, found in the limbs, include the humerus, radius, ulna, femur, tibia, and fibula. They have a cylindrical shaft called the diaphysis, with an enlarged end at each end called the epiphysis. These bones grow through two different centers of ossification: the primary center for the diaphysis and the secondary center for the epiphysis.² Long bones are made up of dense compact bone on the outer layer, while the inner layer is a spongy bone that houses bone marrow. The medullary arterial system is crucial for revascularizing damaged bone tissue and promoting healing. Overall, bones are constantly being remodeled to maintain their strength and adapt to the body's needs, and play important roles in protecting organs, supporting movement, storing minerals, and producing blood cells.³ The nutrient foramen is a significant opening found on the shaft of long bones that facilitates the entry of the nutrient artery, which plays a crucial role in nourishing and promoting growth. It is believed that the direction of the nutrient foramen is influenced by the end of the bone that is growing at a faster rate, which can be up to twice as fast as the non-growing end. Consequently, the nutrient vessels move away from the rapidly growing end of the bone. This phenomenon is often described as "fleeing from the knee and heading towards the elbow," indicating the variation in the nutrient foramen's location between the upper and lower limbs.⁴

The nutrient artery is responsible for supplying the medullary cavity, which contains bone marrow, as well as the inner two-thirds of the compact portion of the diaphysis and metaphysis. This artery enters the compact bone through Volkmann's canal and provides nutrition to the Haversian system.⁵ In addition to its role in fracture healing, the vascular system of bones, which includes the nutrient artery, is also crucial for bone conditions such as developmental abnormalities and hematogenic osteomyelitis.⁶ Therefore, studying the blood supply of long bones and the specific areas supplied by the nutrient artery is essential for developing new techniques in the fields of transplantation and resection.⁷

The present study aims to determine the number and position of the nutrient foramina (NF) of the adult human humerus, radius, ulna of the upper limb and femur, tibia, and fibula

of the lower limb and to observe the size and direction of the nutrient foramina. This study also focuses on determining the foraminal index.

MATERIALS AND METHODS

The study was conducted in the Department of Anatomy, Nepalgunj Medical College, Chisapani during the period of one month in December 2022. The materials for the present study consist of 277 selected adult humans with cleaned and dried long bones having no appearance of pathological changes and fractures. The total length of individual bone was taken as the distance between the proximal point on the upper end and the most distal point of the lower end of all long bones. An elastic rubber band was applied around these foramina to determine the location of the foramina from its proximal end. The length will be measured in mm through an osteometric board. In the entire long bones after determining the sides, the nutrient foramina were studied based on:

- i. The number of foramen
- ii. Direction and size of nutrient foramen-18G, 20G, 21G, 22G, 23G, 26G and 27G needles were used to confirm the size and direction of the foramen.
- iii. All long bones were examined to know the position of nutrient foramen according to their anterior, posterior, medial, and lateral surfaces along with their borders.
- iv. Calculation of foraminal index.
- v. Location of nutrient foramina according to FI was divided into three types, according to FI:
 1. Type 1: FI above 33.33, the foramen was in the proximal third.
 2. Type 2: FI below 33.33 up to 66.66, the foramen was in the middle third.
 3. Type-3: FI above 66.66, the foramen was in the distal.

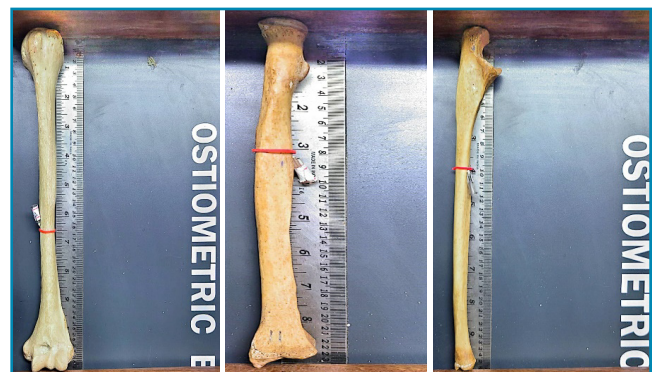


Fig. 1. Determining the length and location of the foramina of the humerus, radius, and ulna

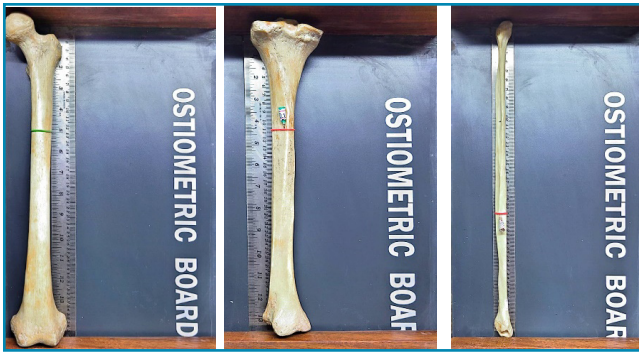

Fig. 2. Determining the length and location of the foramina of the femur, tibia, and fibula

RESULTS

In the present study, 83.0% of the humeri had a single nutrient foramen. The double foramen was observed in 17.1% of the humeri. 97.4% of radii had a single foramen while only 2.6% of the radii has double foramina. All the ulnae had a single primary nutrient foramen. In the lower limb bone, the femurs showed 41.5% of the single primary nutrient foramen, 56.6% double nutrient foramina and only 1.9% had triple nutrient foramina. The tibiae showed the majority of a single nutrient foramen in 93.0% of bones and only 7.0% of tibiae had double nutrient foramen. In fibulae, only one primary nutrient foramen was seen.

The topography of nutrient foramina of the humerus is shown in Table 1. Among them, 81.8% of the foramina were on the anteromedial surface, 7.3% of the foramina on the posterior surface, and 10.9% of the foramina were on the medial border. All of the foramina were in the middle third of the humeri. The topography of nutrient foramina of the radius is shown in Table 2. 84.6% of the foramina was on the anterior surface, 12.8% of the foramina were on the posterior surface while only 2.6% foramina were on the interosseous border.

Table 1: Morphological and topographical distribution of the nutrient foramina in the humerus

Surfaces/ borders of humerus n=55	Number of foramina			% of foramina		
	Right	Left	Total	Right	Left	Total
Anteromedial surface	20	25	45	36.4	45.4	81.8
Posterior surface	1	3	4	1.8	5.4	7.3
Medial border	2	4	6	3.6	7.3	10.9
Upper third	0	0	0	0.0	0.0	0.0
Middle third	23	32	55	41.8	58.2	100.0
Lower third	0	0	0	0	0	0

38.4% of the foramina were in the upper third and 61.5% of the foramina were in the middle third of the radii. The topography of nutrient foramina of the ulna is shown in Table 3. All of the foramina were on the anterior surface.

Table 2: Morphological and topographical distribution of the nutrient foramina in the radius

Surfaces/ borders of radius n=39	Number of foramina			% of foramina		
	Right	Left	Total	Right	Left	Total
Anterior surface	14	19	33	35.9	48.7	84.6
Posterior surface	4	1	5	10.2	2.6	12.8
Interosseous border	0	1	1	0.0	2.6	2.6
Upper third	9	6	15	23.1	15.4	38.4
Middle third	9	15	24	23.1	38.5	61.5
Lower third	0	0	0	0.0	0	0

Table 3: Morphological and topographical distribution of the nutrient foramina in the ulna

Surfaces/ borders of ulna n=38	Number of foramina			% of foramina		
	Right	Left	Total	Right	Left	Total
Anterior surface	17	21	38	44.7	55.3	100.0
Upper third	2	3	5	5.3	7.9	13.2
Middle third	15	18	33	39.5	47.4	86.8
Lower third	0	0	0	0.0	0.0	0.0

Table 4: Morphological and topographical distribution of the nutrient foramina in the femur

Surfaces/ border of femur n=85	Number of foramina			% of foramina		
	Right	Left	Total	Right	Left	Total
Medial surface	6	7	13	7.0	8.2	15.3
Lateral surface	1	3	4	1.2	3.5	4.7
Posterior surface	14	21	35	16.5	24.7	41.2
Linea aspera	13	15	28	15.3	17.6	32.9
Spiral line	4	0	4	4.7	0.0	4.7
Popliteal surface	1	0	1	1.2	0.0	1.2
Upper third	6	8	14	7.0	9.4	16.5
Middle third	32	38	70	37.6	44.7	82.3
Lower third	1	0	1	1.2	0.0	1.2

Table 5: Morphological and topographical distribution of the nutrient foramina in the tibia

Surfaces/ border of tibia n=61	Number of foramina			% of foramina		
	Right	Left	Total	Right	Left	Total
Anterolateral surface	1	0	1	1.6	0.0	1.6
Posterior surface	28	31	59	45.9	50.8	96.7
Medial border	0	1	1	0.0	1.6	1.6
Upper third	24	23	47	39.3	37.7	77.0
Middle third	5	9	14	8.2	14.7	22.9
Lower third	0	0	0	0.0	0.0	0.0

Table 6: Morphological and topographical distribution of the nutrient foramina in the fibula

Surfaces/ border of fibula n=44	Number of foramina			% of foramina		
	Right	Left	Total	Right	Left	Total
Posterior surface	15	15	30	34.1	34.1	68.2
Medial surface	9	5	14	20.4	11.1	31.8
Upper third	0	1	1	0.0	2.3	2.3
Middle third	24	19	43	54.5	43.2	97.7
Lower third	0	0	0	0.0	0.0	0.0

13.2% of the foramina were in the upper third and 86.8% of the foramina were in the middle third of the ulnae.

The topography of the primary nutrient foramina of femurs is shown in table 4. Among them, 15.3% of the foramina were on the medial surface, 4.7% of the foramina on the lateral surface, 41.2% foramina were on the posterior surface, 32.9% of the foramina were on the linea aspera, 4.7% of foramina were on the spiral line and 1.2% of the foramina were on the popliteal surface. 16.5% of foramina were in the upper third, 82.3% of foramina were in the middle third and 1.2% of foramina were in the lower third of the femurs. The topography

of nutrient foramina of tibiae is shown in Table 5. A total of 96.7% of the foramina were on the posterior surface and 1.6% foramina were on the anterolateral surface and medial border both. 77.0% of the foramina were in the upper third and 22.9% of the foramina were in the middle third of the tibiae. The topography of nutrient foramina of fibulae is shown in table 6. 68.2% of the foramina were on the posterior surface and 31.8% of the foramina were on the medial surface. 2.3% of the foramina were in the upper third and 97.7% of the foramina were in the middle third of the fibulae.

The mean foraminal index in the humerus was 57.26. This implies that the majority of the primary diaphyseal foramina in the humerus are in the middle third. The mean foraminal index in the radius was 34.82. This suggests that the majority of the primary foramina in the radius are in the middle third. The mean foraminal index in the ulna was 39.32. This also indicates that the majority of the primary foramina in the ulna are in the middle third of the bone.

The mean foraminal index in the femur was 44.73. This implies that the majority of the primary foramina in the femurs are in the middle third of the bone. The mean foraminal index in the tibia was 32.32. This indicates that the majority of the primary foramina in the tibia are in the upper third of the bone. The mean foraminal index in the fibula was 46.18. This suggests that the majority of the primary foramina in the fibula are in the middle third of the bone. It is observed that in all the long bones of the upper and lower limbs, the majority of the foramina are in the middle third of the bone except the tibia where the maximum foramina are located in the upper third.

The size/diameter of the nutrient foramina of all long bones are shown in Table 7. All the nutrient foramen in the upper limb bone are directed towards the elbow i.e., away from the growing end, and the nutrient foramen in the lower limb bone is directed away from the knee. There were no changes in the obliquity of the canal whether they are in the center or at the periphery of the bone.

Table 7: Diameter of the nutrient foramina of the individual long bone of upper and lower limbs

Bones	Diameter of Individual long bone							
	1.27mm (18G)	0.91mm (20G)	0.83mm (21G)	0.70mm (22G)	0.63mm (23G)	0.464mm (26G)	0.42mm (27G)	Total Foramina
Humerus	00	00	02	09	07	17	20	55
Radius	00	00	00	03	05	13	18	39
Ulna	00	00	00	07	05	10	16	38
Femur	00	11	07	18	19	05	25	85
Tibia	06	17	17	06	09	05	01	61
Fibula	00	00	00	00	00	14	30	44

DISCUSSION

In the present study, in the humerus, single nutrient foramen has a higher percentage (83.0%) compared to that of double (17.0%). Many authors like Longia *et al*⁸ (85.0%), Bhojaraja *et al*⁹ (77.0%) Chandrasekharan *et al*¹⁰ (76.7%), also reported a higher percentage of a single nutrient foramen. According to Ukoha *et al*,¹¹ it was reported that 26.0% of the humeri studied had no nutrient foramen. Kizilkanat *et al*¹² found that in 1.0% of the humeri studied, there were four nutrient foramina present.

In the present study, 97.4% of radii had a single nutrient foramen and only 2.6% of radii had double nutrient foramina. Many authors like Longia *et al*,⁸ Kizilkanat *et al*,¹² Parthasarathy *et al*¹³ and Veeramuthu *et al*,¹⁴ also reported single nutrient foramen in more than 90.0% radii and remaining had double nutrient foramina. Radii without nutrient foramen were also reported by Ukoha *et al*¹¹ (16.0%) and Parthasarathy *et al*¹³ (4.2%).

In the present study, all the ulnae examined had a single nutrient foramen similar to most author. Ukoha *et al*¹¹ and Parthasarathy *et al*¹³ reported ulna without nutrient foramen. Longia *et al*⁸ observed the presence of three nutrient foramina in the ulna.

In the present study, 41.5% femurs had a single nutrient foramen, 56.6% had double nutrient foramina and 1.9% had triple nutrient foramina. Kizilkanat *et al*¹² reported single nutrient foramen in 75.0% of femurs and double nutrient foramina in 25.0%. Bhatnagar *et al*¹⁵ reported single nutrient foramen in 55.0%, double foramina in 43.3%. Similarly Pereira *et al*¹⁶ observed single nutrient foramen in 63.8%, double nutrient foramina in 34.9% and triple foramina in 1.3%. Also Mysorekar¹⁷ reported single nutrient foramen in 45% of femurs, double foramina in 50% and triple foramina in 1.6%.

In the present study, 93.0% of tibia had a single nutrient foramen while only 7.0% had double nutrient foramina. Murlimanju *et al*¹⁸ reported single nutrient foramen in 98.6% of the tibiae and 1.4% of the tibia had no nutrient foramen. Patel *et al*¹⁹ studies showed that 100.0% of the tibia examined had only one nutrient foramen present.

In the present study, all fibulae examined had a single nutrient foramen. Murlimanju *et al*¹⁸ reported single nutrient foramen in 90.2% of the fibulae and 9.8% of the fibula had no nutrient foramen. Another study by Patel *et al*¹⁹

reported 80.0% of fibula had a single foramen and the remaining 20.0% had double foramina.

In the present study, humeri had most of the nutrient foramina on the anteromedial surface (81.8%) followed by the medial border (10.9%). Kizilkanat *et al*¹², Parthasarathy *et al*¹³ and Murlimanju *et al*¹⁸ all reported comparable results, with 62.0%, 60.0%, and 60.0%, respectively demonstrating similar findings. In Asharani *et al*²⁰ studies, it was noted that there were a greater number of nutrient foramina (57.0%) located on the medial border compared to the anteromedial surface. Similarly, radii had most of the nutrient foramina on the anterior surface (84.6%) followed by the posterior surface (12.8%). Challa *et al*²¹ reported similar findings 70.0% and 30.0% in the anterior surfaces and medial border respectively. Ulnae had all their foramina on the anterior surface while Challa and Nanna²¹ reported 78.4% foramina on their anterior surface only.

In the present study, femurs had most of the nutrient foramina on the different parts of the posterior surface (80.0%) followed by the medial surface (15.3%). Joshi and Mathur²² reported all the foramina present on the different aspects of the posterior surface. Similarly, the tibia had most of the nutrient foramina on the posterior surface (84.6%) followed by equal numbers of the anterolateral surface and medial border (1.6%). Kamnath *et al*²³ reported 97.2% on the posterior surface and 2.8% on the medial surface. Fibula had 68.2% of their foramina on the posterior surface followed by the medial surface (31.8%) while Kamnath *et al*²³ reported 100.0% foramina on their posterior surface only.

The mean foraminal index in the humerus was 57.26. This implies that the majority of the primary diaphyseal foramina in the humerus are in the middle third. The mean foraminal index in the radius was 34.82. This suggests that the majority of the primary foramina in the radius are in the middle third. The mean foraminal index in the ulna was 39.32. This also indicates that the majority of the primary foramina in the ulna are in the middle third of the bone.

The mean foraminal index in the femur was 44.73. This implies that the majority of the primary foramina in the femurs are in the middle third of the bone. The mean foraminal index in the tibia was 32.32. This indicates that the majority of the primary foramina in the tibia are in the upper third of the bone. The mean foraminal index in the fibula was 46.18. This suggests that the majority of the primary foramina in the fibula are in the middle third of

the bone. It is observed that in all the long bones of the upper and lower limbs, the majority of the foramina are in the middle third of the bone except the tibia where the maximum foramina are located in the upper third.

The study confirmed previous reports regarding the number, position, and diameter of the nutrient foramina in the long bones of the limbs. It is crucial for surgeons to have a solid understanding of the location of foramina when performing bone operations. Surgeons

must exercise caution when operating in areas where there is a high concentration of nutrient foramina. Knowledge of foramen location assists in the preservation of bone vasculature during surgical procedures, thereby enhancing the likelihood of successful bone grafting, fracture fixation, and shoulder, elbow, and knee replacement procedures.

Conflict of interest: None

Source of research fund: None

REFERENCES

- Gray, Drake RL, Vogl AW, Mitchell AWM. Gray's Anatomy for Students. 2nd ed. London: Churchill Livingstone; 2004.
- Standaring S, Collins P, Wigley C. Gray's Anatomy, 39th ed. London: Elsevier Churchill Livingstone, 2005: 93-6.
- Bishop AT, Shin AY. Vascularized Bone Grafting, In; Wolfe SW, Green's Operative Hand Surgery, 7th ed. Philadelphia, Elsevier, 2017: 1405.
- Garg K. BD Chaurasia's Hand Book of General Anatomy. Blood supply of bones. 5th ed. 2015; 67-9.
- Bokariya P, Gudadhe D, Kothari R, Murkey PN, Shende MR. Comparison of humerus and femur with respect to location and number of nutrient foramina. *Ind J Forensic Med Pathol* 2012; 5: 79-81.
- Sissons H, Kember N. Longitudinal bone growth of human femur. *Post Med J* 1977; 53: 433-7.
- Collipal E, Vargas R, Parra X, Silva H, Sol M. Diaphyseal nutrient foramina in the femur, tibia, fibula bones. *Int J Morph* 2007; 25: 305-8.
- Longia GS, Ajmani ML, Saxena SK *et al.* A study of diaphyseal nutrient foramina in human long bones. *Acta Anat (Basal)* 1980; 107: 399-406.
- Bhojaraja VS, Kalthur SG, Dsouza AS. Anatomical study of diaphyseal nutrient foramina in adult humerus. *Arch Med Health Sci* 2014; 2: 165-9.
- Chandrasekaran S, Shanthi KC. A study on the nutrient foramina of adult humeri. *J Clin Diagn Res* 2013; 7: 975-7.
- Ukoha UU, Umeasalugo KE, Nzeako HC *et al.* A study of nutrient foramina in long bones of Nigerians. *Nat'l J Med Res* 2013; 3: 304-8.
- Kizilkanat E, Boyan N, Ozsahin ET *et al.* Location, number and clinical significance of nutrient foramina in human long bones. *Ann Anat* 2007; 189: 87-95.
- Parthasarathy M, Sharma D, Pushpalatha M, Parthasarathy K, Krishna A, Tulasi RP. Morphological and topographical anatomy of nutrient foramina in human upper limb long bones and their surgical importance. *Ind J Dent Med Sci* 2016; 15: 80-5.
- Veeramuthu M, Elangovan M, Manoranjitham. Nutrient foramina: a study in the long bones of human upper extremities. *Int J Anat Res* 2017; 5: 4394-9.
- Bhatnagar S, Kumar A, Tripathi A *et al.* Nutrient foramina in the upper and lower limb long bones. *Int J Sci Res* 2014; 3: 301-3.
- Pereira GAM, Lopes PTC, Santos AMPV, Silveira FHS. Nutrient foramina in the upper and lower limb long bones: Morphometric study in bones of southern Brazilian adults. *Int'l J Morphol* 2011; 29: 514-20.
- Mysorekar VR. Diaphyseal nutrient foramina in human long bones. *J Anat* 1967; 101: 813-22.
- Murlimanju BV, Prashanth KU, Prabhu LV, Chettiar GK, Pai MM, Dhananjaya KVN. Morphological and topographical anatomy of nutrient foramina in the lower limb long bones and its clinical importance. *Australas Med J* 2011; 4: 530-7.
- Patel S, Vora R, Jotania B, A study of diaphyseal nutrient foramina in human lower limb long bones. *Nat'l J Integr Res Med* 2015, 6: 14-8.
- Asharani SK, Ningaiah A. A study on the nutrient foramen of the humerus. *Int'l J Anat Res* 2016; 4: 2706-9.
- Challa P, Nanna RK. A study of nutrient foramina in human upper limb long bones. *J Evol Med Dent Sci* 2019; 8: 610-2.
- Joshi P, Mathur S. A comprehensive study of nutrient foramina in human lower limb long bones of indian population in Rajasthan state. *Galore Int J Health Sci Res* 2018; 3: 34-42.
- Venkatesh K, Asim M, Bhat S, Avadhani RK. Primary nutrient foramina of tibia and fibula and their surgical implications. *Ind J of Clin Anat Physiol* 2016; 3: 41-4.