

A CASE OF RETINAL ARTERY MACROANEURYSM: A TICKING TIME BOMB OF THE EYE

Sanket Parajuli,¹ Sadhana Sharma,² Ruchi Shrestha¹

¹Reiyukai Eiko Masunaga Eye Hospital, Banepa, Kavre, ²Mechi Eye Hospital, Birtamod, Jhapa, Nepal

ABSTRACT

Retinal arterial macroaneurysms are acquired, focal dilation of a retinal artery. Patients with retinal arterial macroaneurysms can present with an acute or gradual loss of vision as a result of vitreous hemorrhage, preretinal hemorrhage or macular edema. An 81 year old female, a known hypertensive since 12 years under regular follow-up visits, presented to us with vitreous hemorrhage secondary to ruptured retinal artery macroaneurysm in the right eye. She was managed with indirect argon laser treatment. Accurate diagnosis and co-management are crucial to save vision and help prevent life altering complications. This case report emphasizes the need of ocular examination in systemic diseases and further establishes 'eye as the window of the body'.

KEYWORDS

Retinal artery macroaneurysm, vitreous hemorrhage, RAM

Received on: November 6, 2022

Accepted for publication: March 31, 2023

CORRESPONDING AUTHOR

Dr. Sanket Parajuli
Consultant,
Reiyukai Eiko Masunaga Eye Hospital,
Banepa, Kavre, Nepal
Email: sanketparajuli@gmail.com
Orcid No: <https://orcid.org/0000-0002-1472-4769>
DOI: <https://doi.org/10.3126/nmcj.v25i2.56081>

INTRODUCTION

Retinal arterial macroaneurysms (RAM) are acquired, focal dilation of a retinal artery, usually located within the first three bifurcations of the central retinal artery.¹ Most commonly they are found at the arteriovenous crossings or at a bifurcation.^{1,2} RAM can occur as solitary lesion or can be multiple. Multiple RAMs is seen in 15–20% of cases and are bilateral in up to 10% of cases.² The arteriovenous crossings lack advential layer thus creating a weakness in the arterial wall making the walls prone to aneurysmal dilatation.³ RAMs are seen commonly in elderly females, age ranging from 66 to 74 years old.^{3,4} RAM can be associated with systemic hypertension, arteriosclerosis and abnormal lipid levels. Almost 75% of patients with RAM have systemic hypertension.^{4,5} Patients with RAM can present with an acute or gradual loss of vision as a result of vitreous hemorrhage, preretinal hemorrhage or macular edema. A significant number of RAMs go undiagnosed in absence of symptoms, later leading to various complications.²

CASE REPORT

An 81-year-old female presented with sudden vision loss in her right eye of 2 days duration. There was no history of flashes of light or ocular pain. Medical history was notable for hypertension, diagnosed 12 years ago, for which she was taking amlodipine and losartan. We noted poor compliance with these medications. Best corrected visual acuities were hand motion on right eye (OD) and 6/9 on left eye (OS). Pupils were equal, round and reactive to light without relative afferent pupillary defect. Ocular motility were in full range in both eyes (OU). Anterior segment examination was unremarkable in each eye. Goldmann applanation tonometry readings were 16 and 18 mmHg in right and left eye respectively. Blood pressure measured 198/96 mmHg. Patient denied having symptoms of elevated blood pressure, including headache, shortness of breath, dizziness, nausea, chest pain or paresthesias. Dilated fundus examination of right eye revealed dense vitreous hemorrhage obscuring the view of the fundus. Dilated fundus examination of left eye was normal. Right eye biometry scan gave an impression of attached retina with normal retina-choroidal-scleral thickness. Patient was managed conservatively for vitreous hemorrhage. On 2 weeks follow up, the vitreous hemorrhage had organized to a significant extent and allowed us a window for retina examination. Fundus revealed normal optic disc and macula. Along the inferotemporal arcade, there was a

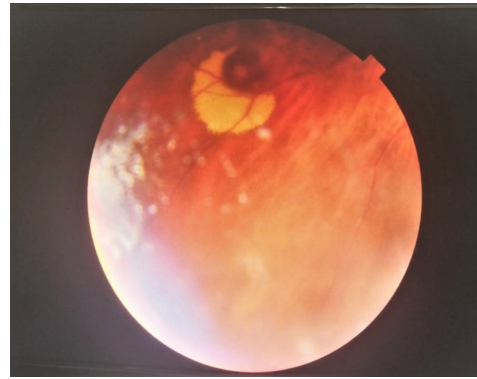


Fig. 1: Retinal artery macroaneurysm appearing as a large intraretinal hemorrhagic spot surrounded by yellowish lipid exudate)

large intraretinal hemorrhagic spot (1 disc diameter in size) surrounded by yellowish lipid exudate (5 disc diameter in size) (Fig. 1). Vasculature was mildly tortuous and showed generalized arterial attenuation. A diagnosis of retinal artery macroaneurysm was made and confirmed on spectral domain optical coherence tomography (SD OCT). Retina surrounding the RAM was treated with 134 spots of argon laser photocoagulation (spot size 200µm, duration 0.2sec, interval 0.5 sec, power 210 mW) in 2-3 rows. The patient was educated on the importance of strict blood pressure control, referred to cardiologist for blood pressure management and cardiovascular evaluation. The patient was advised for follow-up 2 weekly for a month then monthly for 3 months and then 3 monthly. The vision has been stable on all follow-up visits since 12 months. Final best corrected acuities measured 6/9 on both eye. The retinal macroaneurysm had diminished in the extent of exudation on last visit.

DISCUSSION

RAM can present as vitreous hemorrhage, hemorrhage in multiple layers of retina, including subretinal, intraretinal, preretinal and vitreal or may be found as an incidental finding.^{1,6} Arteries are high flow vessels with weak walls. When an aneurysm ruptures, the blood is pushed into retinal layers or into vitreous.^{2,5} Exudation are seen in a circinate pattern surrounding the aneurysm.⁴ Complications although rare, do occur. The common complications include vision loss from hemorrhagic sequelae or chronic macular edema.

Our case report depicts a scenario where a patient despite having been in a regular followup every 6-8 monthly since past 8-10 years had not been diagnosed with RAM. This shows how easily RAMs remain silent and

suddenly culminates into more severe, vision threatening complications.

Eyes with vitreous and pre-retinal hemorrhage have good prognosis in terms of visual outcome compared to eyes with macular edema and deeper retinal hemorrhaging. Submacular hemorrhage has the poorest prognosis.⁷ Effect of subretinal blood results in damage to photoreceptors as a result of effect of chemical toxins, outer-retinal shear forces and a barrier effect limiting diffusion between the photoreceptors and retinal pigment epithelium.^{1,7} Severe damage, resulting in permanent vision loss is thought to occur in as little as 2 days and definitely within 2 weeks.¹ Macular holes and subretinal neovascularization have also been reported to occur as a result of submacular hemorrhage.⁸ Chronic macular edema and dense long-standing exudates can also cause a permanent loss of best corrected visual acuity.^{1,9} Additional reported complications include secondary angle closure glaucoma, serous or hemorrhagic retinal detachments and retinal vein occlusion.^{1,10}

Direct argon laser to macroaneurysm, applied cautiously, can help hasten resolution of the RAM. Laser should be applied with low power, long burn duration, and large spot size to avoid rupture of the RAM. Only 16% to 27% of RAMs are successfully thrombosed after treatment with direct laser photocoagulation.¹¹ Indirect retinal laser photocoagulation is thought to reduce oxygen consumption and thus blood flow to the RAM as well as decreasing exudation from surrounding capillaries. This technique avoids direct thermal energy to the lesion, results in arteriolar occlusion and rupture. However, it has not been established which of these methods is superior, and some physicians prefer a combination of both direct and indirect laser.¹²

Intravitreal injections of anti-vascular endothelial growth factor (VEGF) have been studied as a treatment option for RAM with macular hemorrhage or secondary macular edema.¹³ Pars planavitreotomy (PPV) may be considered in cases of non-clearing vitreous hemorrhage, usually after 3 months of observation.^{2,14}

Patients presenting with RAM need evaluation by their primary care physician for hypertension, lipid and arteriosclerosis control. Since a significant number of RAMs are missed on evaluation, it may act as a ticking time bomb which can cause deleterious effects on vision. Accurate diagnosis and co-management are crucial to save vision and help prevent life altering complications.

Conflict of interests: None

Source of research fund: None

REFERENCES

1. Holdeman NR, Sable GM, Lopez-Gurrola M, Tang RA. Retinal arterial macroaneurysm. *Clin Refractive Optometry* 2007; 18: 344-9.
2. Bopp S. Retinal arterial macroaneurysms. In: Jousseaume AM, Gardner TW, Kirchhof B, Ryan SJ, editors. *Retinal Vascular Disease* [Internet] Springer-Verlag; New York, NY: 2007. pp. 543-60.
3. Lavin MJ, Marsh RJ, Peart S, Rehman A. Retinal arteriole macroaneurysms: a retrospective study of 40 patients. *Br J Ophthalmol* 1987; 71: 817-25.
4. Adamczyk AT, Olivares GE, Petito GT. Retinal arterial macroaneurysm: a longitudinal case study. *J Am Optom Assoc* 1989; 60: 840-5.
5. Rabb MF, Gagliano DA, Teske MP. Retinal arterial macroaneurysms. *Survey Ophthalmol* 1988; 33: 73-96.
6. Gedik S, Gur S, Yilmaz G, Akova YA. Retinal arterial macroaneurysm rupture following fundus fluorescein angiography and treatment with Nd:m YAG laser membranectomy. *Ophthalmic Surg Lasers Imag* 2007; 38: 154-6.
7. Tonotsuka T, Imai M, Saito K, Iijima H. Visual prognosis for symptomatic retinal arterial macroaneurysm. *Japanese J Ophthalmol* 2003; 47: 498-502.
8. Murthy K, Puri P, Talbot J. Retinal macroaneurysm with macular hole and subretinal neovascular membrane. *Eye* 2005; 19: 488-9
9. Moosavi RA, Fong KC, Chopdar A. Retinal artery macroaneurysms: clinical and fluorescein angiographic features in 34 patients. *Eye* 2006; 20: 1011-20.
10. Pantou RW, Goldberg MF, Farber MD. Retinal arterial macroaneurysms: risk factors and natural history. *Brit J Ophthalmol* 1990; 74: 595-600.
11. Meyer JC, Ahmad BU, Blinder KJ, Shah GK. Laser therapy versus observation for symptomatic retinal artery macroaneurysms. *Graefes Arch Clin Exp Ophthalmol* 2015; 253: 537-41.
12. Koinzer S, Heckmann J, Tode J, Roeder J. Long-term, therapy-related visual outcome of 49 cases with retinal arterial macroaneurysm: a case series and literature review. *Brit J Ophthalmol* 2015; 99: 1345-53.
13. Cho HJ, Rhee TK, Kim HS. Intravitreal bevacizumab for symptomatic retinal arterial macroaneurysm. *Amer J Ophthalmol* 2013; 155: 898-904.
14. Wu TT, Chuang CT, Sheu SJ, Chiou YH. Non-vitreotomizing vitreous surgery for premacular hemorrhage. *Acta Ophthalmol* 2011; 89: 194-7.