

EVALUATION OF PORTAL VEIN VELOCITY IN NON ALCOHOLIC FATTY LIVER DISEASE BY DOPPLER ULTRASOUND

Prabhat Basnet, Pramod Kumar Chhetri, Kripesh Thapa

Department of Radiology and Imaging, College of Medical Sciences, Bharatpur, Chitwan, Nepal

ABSTRACT

Nonalcoholic fatty liver disease is being increasingly recognized as one of the major causes of chronic liver disease. It is associated with various metabolic condition including obesity and diabetes. As the incidence of diabetes and obesity is increasing every day due to change in lifestyle, the incidence of nonalcoholic fatty liver disease is also increasing and so does its related chronic liver disease. Doppler ultrasound is easily available, noninvasive modality to see the hemodynamics of portal vein in various diffuse liver diseases. Our objective in our study is to show the correlation between the nonalcoholic fatty liver disease and Doppler findings of portal vein. The study was conducted in Department of Radiology of College of medical sciences, Bharatpur. Total 70 participants with in group of 30-60 years were included in our study (50 patients with fatty liver disease and 20 with normal liver parenchyma). All ultrasound examination performed with the Toshiba Aplio 500 with convex array deep probe of frequency 3.5MHZ. Prospective cross-sectional study was conducted over the period of one year between September 2020 to August 2021. The mean age of our patients with fatty liver was 42.1 ± 8.4 years, mean BMI was 30.6 ± 3.6 similarly mean V_min and V_max of portal vein is 20.0 ± 7.7 cm/s and 24.6 ± 7.4 cm/s respectively. Same way the control group without fatty liver had 40.6 ± 9.7 years mean age, 23.55 ± 4.8 cm/s mean BMI, 30.05 ± 5.1 cm/s mean V_min and 34 ± 5.0 cm/s mean V_max. There is statistically significant difference of mean BMI ($p < 0.001$), Minimum Portal Vein Velocity ($p < 0.001$) and Maximum Portal Vein Velocity ($p < 0.001$) among the patients having fatty liver disease and not having fatty liver. Our findings suggest that patients with nonalcoholic fatty liver have lower portal venous velocities than normal healthy study participants.

KEYWORDS

Body mass index, doppler scan, non-alcoholic fatty liver, peak systolic velocity, ultrasound

Received on: November 21, 2021

Accepted for publication: January 14, 2022

CORRESPONDING AUTHOR

Dr. Prabhat Basnet
Assistant Professor,
Department of Radiology, College of Medical Sciences,
Bharatpur, Chitwan, Nepal
Email: pbasnet99@gmail.com
Orcid No: <https://orcid.org/0000-0003-1112-7800>
DOI: <https://doi.org/10.3126/nmcj.v24i1.44104>

INTRODUCTION

Non-alcoholic fatty liver disease is commonly encountered condition that may progress to end-stage liver disease. The pathogenesis of the disease is similar to the alcoholic liver injury but it occurs in patients who do not consume alcohol.^{1,2} Nonalcoholic fatty liver disease is becoming the preferred term, and it refers to a wide spectrum of liver damage, ranging from simple steatosis to steatohepatitis, advanced fibrosis, and cirrhosis. The clinical implications of nonalcoholic fatty liver disease are derived mostly from its common occurrence in the general population and its potential to progress to cirrhosis and liver failure. Nonalcoholic fatty liver disease may affect persons of any age and has been described in most racial groups. In most series, the typical patient with nonalcoholic fatty liver disease is a middle-aged woman.^{1,3-6}

Ultrasound examination shows increased echogenicity of liver parenchyma compared to the adjacent renal cortex. Ultrasound has a sensitivity of 89 percent and a specificity of 93 percent in detecting steatosis and a sensitivity and specificity of 77 percent and 89 percent, respectively, in detecting increased fibrosis.⁷ In CT scan the fatty liver disease cause low density hepatic parenchyma. Focal fat or focal fat sparing in the ultrasound and CT can be sometimes challenging to diagnose and may misdiagnosed as hepatic mass, in such case the MRI is problem solving.⁸ It helps to distinguish between the hepatic mass and focal fat or focal fat sparing. Magnetic resonance spectroscopy allows a quantitative assessment of fatty infiltration of the liver.⁹

Doppler ultrasound is very important diagnostic method for non-invasive assessment of the hemodynamics of the hepatic vascular flow. Various studies showed that the flow of hepatic and portal vein is altered in patient with liver cirrhosis, portal vein thrombosis, Budd-Chiari syndrome and vascular malformation. There are also recent studies showing relationship between the fatty liver disease and Doppler flow of the portal vein. This study also aimed to evaluate the Doppler parameters in fatty liver disease and show the relationship between the fatty liver disease and portal vein Doppler study.

MATERIALS AND METHODS

The study was conducted in Department of Radiology and Imaging, College of Medical Sciences, Bharatpur from September 2020 to

August 2021. All USG examination were done using Aplio 500 Toshiba Machine with convex array deep probe of frequency 3.5MHZ. The Doppler scan of the 70 subjects done, 50 subjects with variable degree of fatty liver and 20 subjects with normal liver with age between 30-60 years were included in our study. The grading of fatty liver was done from 1 to 3 depending on the ultrasound scan. The weight and height of the every patient were taken to calculate the body mass index. Patients with history of alcohol intake, history of heart disease, acute or chronic liver disease, positive hepatitis B and C and age >60 years and below 30 years were excluded from study.

Examination was done after overnight fasting. Each patient was examined in supine position with arms raised above the head. The liver parenchyma was scanned and chronic liver disease, liver benign and malignant mass and vascular malformation were excluded. The B mode ultrasound was done to grade the fatty liver from 1 to 3. The Doppler scan of the portal vein was done in quite inspiration and spectral Doppler waveform of the portal vein was recorded (Scatariage *et al.* 1984; Karabulut *et al.* 2004). The point of measurement was main portal vein. To characterize the portal vein the maximum and minimum peak velocity was obtained in patients with fatty liver and normal control group.

Data obtained was compiled and analyzed using standard statistical analysis. SPSS 20.0 and Microsoft Excel were used for the data analysis and presentation. The research protocol was submitted and approved by the ethical review committee of College of Medical Science Teaching Hospital, Bharatpur, Nepal.

RESULTS

Total 70 subjects in age group of 30-60 years were included in our study (50 patients with fatty liver disease and 20 with normal liver parenchyma). The relation between the different parameters including BMI, age, sex, portal venous velocity (V_{max} and V_{min}) in both groups, with or without fatty liver disease were compared and P-value was calculated to see if significant correlation exists between them.

Study showed the mean age of our patients with fatty liver was 42.1 ± 8.4 years, mean BMI was 30.6 ± 3.6, similarly mean V_{min} and V_{max} of portal vein is 20.0 ± 7.7cm/s and 24.6 ± 7.4cm/s respectively. Same way the control group without fatty liver had 40.6 ± 9.7 mean

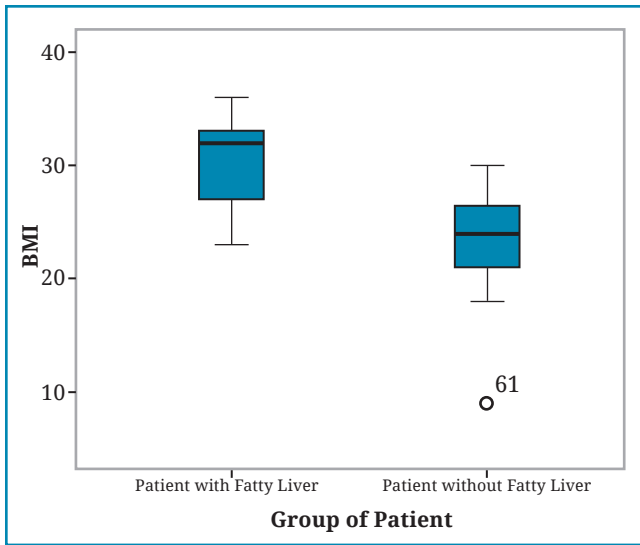


Fig 1: Relation between the BMI and fatty liver disease. The patients with fatty liver disease shows higher BMI value comparing with control group without fatty liver.

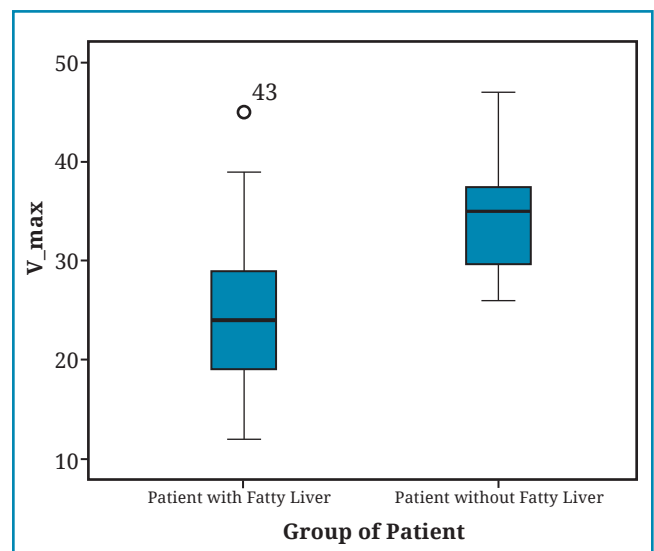


Fig: 3 Relation between the fatty liver disease and Portal vein velocity (max). The maximum portal vein velocity is low in the patients with fatty liver disease comparing with control group with no fatty liver disease.

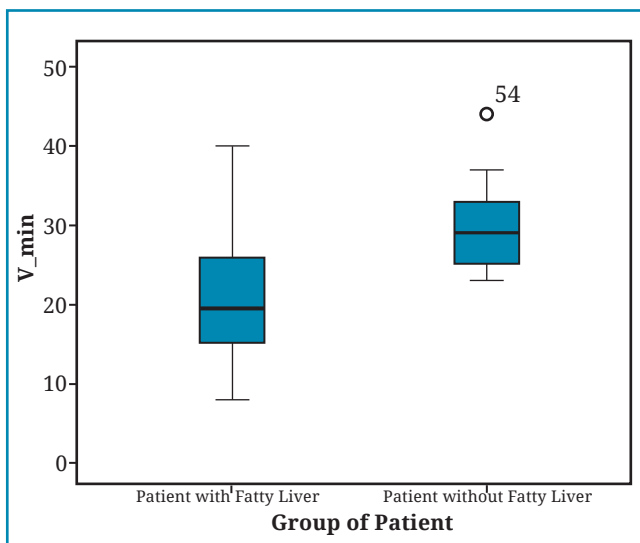


Fig 2: The relation between the fatty liver disease and Portal vein velocity (min). The minimum portal vein velocity is low in the patients with fatty liver disease comparing with control group with no fatty liver disease.

age, 23.55 ± 4.8 mean BMI, 30.05 ± 5.1 cm/s mean V_min and 34 ± 5.0 cm/s mean V_max.

There is statistically significant difference of mean BMI ($p < 0.001$), Minimum Portal Vein Velocity ($p < 0.001$) and Maximum Portal Vein Velocity ($p < 0.001$) among the patients having fatty liver disease and not having fatty liver.

Females shows high distribution of the fatty liver (80%) among the patients with nonalcoholic fatty liver disease has.

The patients with fatty liver disease showed fatty liver grade 2 in 64% followed by fatty liver grade 1 in 32% and fatty liver grade 3 in 4%.

DISCUSSION

The main findings of our study is that the V_max and V_min decrease in patients with fatty liver and in patients with high BMI. The cause

Table 1: Calculation of the mean, standard deviation, range and p value of age, BMI, V max and V min variables.

Variables	Pt with Fatty Liver (n=50)		Pt without Fatty Liver (n=20)		Mean difference	p Value
	Mean \pm SD	Range	Mean \pm SD	Range		
Age	42.1 ± 8.4	30-60	40.6 ± 9.7	31-57	NA	
BMI	30.6 ± 3.6	23-36	23.55 ± 4.8	19-30	7.03	<0.001
V_min	20.0 ± 7.7	8-40	30.05 ± 5.1	23-44	10.05	<0.001
V_max	24.6 ± 7.4	12-45	34 ± 5.0	26-47	9.40	<0.001

Table 2: Distribution of fatty liver disease among the male and females

Sex	Group of patient		p Value
	Patient with Fatty Liver n (%)	Patient without Fatty Liver n (%)	
Female	40 80.0%	10 (20.0%)	0.019
Male	10 20.0%	10 (20.0%)	

Table 3: Fatty liver grading among the patients with fatty liver disease

FL Grading	Patient with Fatty Liver		Total
0 (with no fatty liver)	0	0%	20
1	16	32%	16
2	32	64%	32
3	2	4%	2

of reduced V_{max} and V_{min} may be due to reduced vascular compliance in the liver with fatty infiltration. The high BMI is seen in obesity. The various study shows that the prevalence of obesity in patients with nonalcoholic fatty liver disease varies between 30 and 100 percent, the prevalence of type 2 diabetes varied between 10 and 75 percent and prevalence of the hyperlipidemia varied between 20 and 92 percent.^{1,3,10}

Dietrich *et al*¹¹ found that the relative contribution of intrahepatic fat deposition and inflammatory changes to the flow patterns of the hepatic and portal veins are unknown. They investigated that the correlation between the V_{max} and V_{min} of the portal vein and degree of fatty infiltration defined histologically in biopsy proven hepatitis-C patients, and found that v max and V min decreased as the degree of hepatosteatosis increased.

Schneider *et al*¹² found a negative correlation between the degree of fatty liver and portal vein flow modulation in patients with hepatitis C and a negative correlation between the degree of fatty infiltration and the portal vein MFV. In our group the patients with hepatitis B,C and chronic liver disease are excluded. The correlation between the fatty liver and V_{max} and V_{min} showed negative correlation.

Balci *et al*¹³ reported a relationship between fatty infiltration of the liver and decreased portal venous velocity and pulsatility in a study which showed decreased V_{max} and V_{min} with increased fatty liver which is similar to our study.

Erdogmus *et al*¹⁴ also found that there is negative correlation between the fatty liver and portal vein V_{max} and V_{min}, pulsatility index and mean flow velocity. This is also similar to our study in which V max and V min decreased with increased fatty liver disease.

Similar study conducted by the Alizadeh *et al*¹⁵ in 50 patients showed significant association existed between sonography graded fatty liver (SGFL) and fibroscan graded fatty liver (FGFL) (P = 0.006). Portal vein pulsatility index (PI) and phasicity plus the triphasic and monophasic pattern of hepatic veins significantly associated with fatty liver grade evaluated by sonography.

In another study conducted by Ulasan *et al*¹⁶ in 35 patients with nonalcoholic fatty liver disease and 29 normal healthy adults showed the difference in portal venous velocity between the patients with nonalcoholic fatty liver disease and the control group was significant (p < 0.0001) which corresponds to ours study.

From above study we can conclude that there is significant correlation between the portal vein velocity and fatty liver disease and also between obesity and nonalcoholic fatty liver. The alteration of the portal vein hemodynamics due the lower vascular resistance in fatty infiltration is the most probable cause of the low portal vein velocity in fatty liver.

LIMITATION OF STUDY: There are few limitations in our study. The first being the fatty liver evaluation was done by ultrasound of liver, as we did not perform the liver biopsies due to ethical reason. We also did not perform echocardiography to exclude the heart disease.

Conflict of interest: None

Source of research fund: None

REFERENCES

- Ludwig J, Viggiano TR, McGill DB, Oh BJ. Nonalcoholic steatohepatitis: Mayo Clinic experiences with a hitherto unnamed disease. *Mayo Clin Proc* 1980; 55: 434–8.
- Schaffner F, Thaler H. Nonalcoholic fatty liver disease. *Prog Liver Dis* 1986; 8: 283–98.
- Adler M, Schaffner F. Fatty liver hepatitis and cirrhosis in obese patients. *Am J Med* 1979; 67: 811–6.
- Powell EE, Cooksley WG, Hanson R, Searle J, Halliday JW, Powell LW. The natural history of nonalcoholic steatohepatitis: a follow-up study of forty-two patients for up to 21 years. *Hepatology* 1990; 11: 74–80.
- Pinto HC, Baptista A, Camilo ME, Valente A, Saragoça A, de Moura MC. Nonalcoholic steatohepatitis. Clinicopathological comparison with alcoholic hepatitis in ambulatory and hospitalized patients. *Dig Dis Sci* 1996; 41: 1729.
- Angulo P, Keach JC, Batts KP, Lindor KD. Independent predictors of liver fibrosis in patients with nonalcoholic steatohepatitis. *Hepatology* 1999; 30: 1356–62.
- Joseph AE, Saverymuttu SH, al-Sam S, Cook MG, Maxwell JD. Comparison of liver histology with ultrasonography in assessing diffuse parenchymal liver disease. *Clin Radiol* 1991; 43: 26–31.
- Mitchell DG. Focal manifestations of diffuse liver disease at MR imaging. *Radiology* 1992; 185: 1–11.
- Longo R, Pollesello P, Ricci C *et al.* Proton MR spectroscopy in quantitative in vivo determination of fat content in human liver steatosis. *J Magn Reson Imaging* 1995; 5: 2815.
- Manton ND, Lipsett J, Moore DJ, Davidson GP, Bourne AJ, Couper RT. Non-alcoholic steatohepatitis in children and adolescents. *Med J Aust* 2000; 173: 476–9.
- Dietrich CF, Lee JH, Gottschalk R *et al.* Hepatic and portal vein flow pattern in correlation with intrahepatic fat deposition and liver histology in patients with chronic hepatitis C. *Am J Roentgenol* 1998; 171: 437–43.
- Schneider AR, Teuber G, Kriener S, Caspary WF. Noninvasive assessment of liver steatosis, fibrosis and inflammation in chronic hepatitis C virus infection. *Liver Int* 2005; 25: 1150–5.
- Balci A, Karazincir S, Sumbas H, Oter Y, Egilmez E, Inandi T. Effects of diffuse fatty infiltration of the liver on portal vein flow hemodynamics. *J Clin Ultrasound*; 36: 134–40.
- Erdogmus B, Tamer A, Buyukkaya R *et al.* Portal vein hemodynamics in patients with non-alcoholic fatty liver disease. *Tohoku J Exp Med* 2008; 215: 89–93.
- Alizadeh A, Mansour-Ghanaei F, Roozdar A *et al.* Laboratory Tests, Liver Vessels Color Doppler Sonography, and FibroScan Findings in Patients with Nonalcoholic Fatty Liver Disease: An Observation Study. *J Clin Imaging Sci* 2018; 8: 12.
- Ulusan S, Yakar T, Koc Z. Evaluation of portal venous velocity with Doppler ultrasound in patients with nonalcoholic fatty liver disease. *Korean J Radiol* 2011; 12: 450–5.