

# Prevalence of C-Shaped Root Canal Systems in Mandibular Second Molars in Nepalese Population

Snigdha Shubham,<sup>1</sup> Kriti Shrestha,<sup>1</sup> Sageer Ahmad,<sup>1</sup> Vanita Gautam<sup>1</sup>

<sup>1</sup>Department of Conservative Dentistry and Endodontics, Universal College of Medical Sciences, Bhairahawa, Nepal.

## ABSTRACT

**Introduction:** Detailed diagnosis, treatment planning and successful endodontic treatment require in-depth understanding of the root canal anatomy and its distinguishing features in various ethnic groups.

**Objective:** The aim of this study was to study the C-shaped canal morphology of mandibular second molars in Nepalese population by using clinical and radiographic analysis.

**Methods:** This descriptive cross-sectional study will be designed and implemented using records from dental records from January 2017 to January 2021. Out of 4680 cases, 1800 cases were evaluated as sample based upon inclusion and exclusion criteria. The prevalence of C-shaped root canals according to age, sex, and quadrant were calculated. The morphology of C-shaped root canals were assessed on the basis of radiographic appearance and clinical examination record. Descriptive statistics were presented as numbers and percentage. Chi-square test was used to check any association between variables. Level of significance was kept at 0.05.

**Results:** The prevalence of C-shaped canals was 0.105%(n=162) in second mandibular molar with highest prevalence was in young adult age group (18-25) and slightly higher in male cases than female. Unilateral cases (93.83%) of C-shaped was more prevalent than bilateral (6.17%). Group of age and site(unilateral/bilateral) variables were significantly associated with the prevalence of c-shaped canals.

**Conclusions:** Knowing the anatomical variation and prevalence of population we are treating is utmost important for favorable outcome. In comparison to the prevalence of other Asian countries like China, Korea the prevalence of C-shaped canal was comparatively less.

Keywords: C-shaped canal; morphology; Nepalese population; prevalence; second molar.

## INTRODUCTION

Study of atypical root canal anatomy such as C-shaped might play a roadmap for successful root canal treatment.<sup>1</sup> C-shaped canal configuration was first coined by Cooke and Cox in 1979.<sup>2</sup> The variation of C-shaped root canal system appears to be genetically determined, and it has some relationship with ethnic origin.<sup>3</sup> Manning et al has described the root canal anatomy of mandibular second molars, in which he stated that C-shaped root canals were first

documented in 1908 and 1911, in the skeletal remains of the Neanderthal race, which were predecessors of the Mongoloid race that includes Asian populations.<sup>3</sup> Though most commonly found in mandibular second molars,<sup>4,11</sup> the C-shaped canal configuration may also occur in mandibular premolars,<sup>12-16</sup> maxillary molars,<sup>17,18</sup> and mandibular third molars.<sup>19,20</sup>

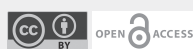
The Nepalese population is generally considered to be a hybrid of several ethnic groups with characteristics of Caucasian, Mongoloid, and Negroid races, which is generally referred to as the Dravidian group.<sup>21</sup>

Although literature shows studies on root canal morphology of molars and premolars in different Asian population, there is scarcity of data on Nepalese population.

### Correspondence

Dr. Snigdha Shubham.

Email: drsnigdhashubham15@gmail.com



### Citation

Shubham S, Shrestha K, Ahmad S, Gautam V. Prevalence of C-Shaped Root Canal Systems in Mandibular Second Molars in Nepalese Population. *Nepal J Health Sci.* 2022 Jan-Jun; 2(1):85-9.

Hence, the aim of this study was to evaluate the prevalence of C-shaped canal morphology of mandibular second molars in Nepalese population by using clinical and radiographic analysis. The result of this study will provide a reliable guidance for endodontic treatment and enhancing its success rate of mandibular second molar.

## METHODS

This cross-sectional retrospective study was approved by the Institutional Review Committee (IRC) of Universal College of Medical Sciences, Bhairahawa, Nepal (UCMS/IRC/158/21). The study was designed and implemented using dental records from record section of the Department of Endodontics, Universal College of Medical Sciences, Bhairahawa, Nepal for the duration of January 2017 to January 2021. Only the full record of the patients who were evaluated by radiographic and clinical examination, respectively and data entered appropriately were taken as sample. Identity of all the patients in sample were strictly kept confidential.

The patients within the age group of 18-60 years were included in sample size with the pulpal diagnosis of irreversible pulpitis and symptomatic or asymptomatic apical periodontitis of second molar. Whereas, the patients were excluded on the basis of: cases with open apices, root resorption or calcification, previous root canal treated teeth and improper radiographic images and incomplete clinical records.

The sample size was calculated by,

$$\begin{aligned} \text{Sample size (n)} &= z^2 \times p(1-p) / e^2 \\ &= 2.6^2 \times 0.05(1-0.05) / 0.02^2 \\ &= 4225 \end{aligned}$$

where,

Z= 2.6 at 99% Confidence Interval

p= 50% assumed prevalence of C- shaped canal

q= 0.5 (1-p)

e= 0.02 at 2% margin of error

The prevalence of C-shaped root canals according to age, sex, and quadrant were calculated. The morphology of C-shaped root canals was assessed on the basis of radiographic appearance and clinical examination record. To evaluate the radiograph, two endodontists independently evaluated the images twice, with a week interval between the assessments. If there were disagreements between them, a radiologist with endodontic experience was asked to perform a third evaluation and then reached a final consensus. All the evaluators were calibrated by analyzing 20 random cases of mandibular premolars based on the same criteria and variants. The clinical evaluation was done based on architecture of floor of access cavity by using magnifying loupes (Zumax Medical Co, Ltd, China). The radiographic assessment was done at three different angulations; perpendicular, mesial and distal angulations.

Descriptive statistics were presented as numbers and percentage. Chi-square test was used to check any association between variables. Level of significance was kept at 0.05.

## RESULTS

Out of 4680 cases evaluated for root canal treatment only 1800 cases were included in the study after taking into consideration of inclusion and exclusion criteria. The prevalence of C-shaped canals was 0.105% (n=162) in second mandibular molar. Among which highest prevalence was in young adult age group (18-25) as shown in (Table 1) and slightly higher in male cases than female as shown in (Table 2). Unilateral cases (93.83%) of C-shaped was more prevalent than bilateral (6.17%) as shown in (Table 3). Table 4 suggested prevalence of C-shaped canal is significantly associated with age group and site whereas gender type was not associated.

**Table 1: Prevalence of C-shaped canal in different age groups.**

Age Group	Cases	Percentage
18-25	62	38.27%
25-44	58	35.80%
44-60	42	25.93%
Total	162	100%

**Table2: Prevalence of C-shaped canal gender wise.**

Gender	Cases	Percentage
Male	84	51.85%
Female	78	48.15%
Total	162	100%

**Table 3: Prevalence of C-shaped canals site wise.**

Side	Cases	Percentage
Right	86	53.09%
Left	66	40.74%
Both	10	6.17%
Total	162	100

**Table 4: Association of variables with C-shaped cases**

Variables	Categories	C- Shaped Count		p-value
		Absent	Present	
Gender	Male	857	84(51.85%)	0.9
	Female	781	78(48.15%)	
Age Group	18-25	589	62 (38.27%)	<0.05
	25-44	813	58 (35.80%)	
	44-60	236	42 (25.93%)	
Site	Unilateral	1402	152(93.83%)	0.003
	Bilateral	236	10(6.17%)	

Chi-square test at 0.05 level of significant

## DISCUSSION

Recognition of variations in root canal anatomy is an essential prerequisite for successful endodontic diagnosis and treatment. The complexities of internal anatomy are often masked by the external surfaces, which have a relatively simple and uniform anatomy. C-shaped canal is a single ribbon-

shaped orifice with a 180° arc (or more), which, in mandibular molars, starts at the mesiolingual line angle and sweeps around the buccal to the end at the distal aspect of the pulp chamber.<sup>22</sup> Below the orifice level, the root structure can harbor a wide range of anatomic variations. These can be classified into two basic groups: (1) those with a single, ribbon-like, C-shaped canal from orifice to apex and (2) those

with three or more distinct canals below the C-shaped orifice.<sup>22</sup> C-shaped canals with a single belt of canal are generally fortunate finding.<sup>22</sup> The configuration presents with variations in both the number and location of the canal(s), as the canal(s) courses from the coronal to the apical third.<sup>23</sup> The complexity of this canal configuration such as presence of a fin or web connecting the individual root canals proves to be a challenge with respect to debridement and obturation and possibly the prognosis during root canal therapy.<sup>23,24</sup> Hence, recognition of a C-shaped canal configuration before treatment can facilitate effective management, which will prevent irreparable damage that may put the tooth in severe jeopardy.

The C-shaped canal is more common in the Asian population specifically in Korean with its reported prevalence ranging from 31% to 44.5%.<sup>25, 26</sup> But in the current study, the prevalence of C-shaped canals were observed only 0.105%. Differences between populations in the prevalence of C-shaped root canal systems emphasize the influence of ethnicity on the root canal anatomy of mandibular second molars.

C-shaped root canals were significantly less prevalent in the age group of 44-60 years than in the 25-44 years age group, and patients in the over 51 age group were less likely to have C-shaped root canals than those in other age groups which was consistent with previous studies.<sup>27,28</sup> It is our conjecture that as C-shaped canals are anatomically complex and more difficult for performing root canal treatment than other types of root canals, the incidence of extraction of teeth with C-shaped canals increases with age, resulting in a decreased prevalence with increasing age.

In this study, frequency of C-shaped roots in the mandibular second molars were unaffected by gender, the result was similar to the other studies<sup>25,27</sup> whereas few studies<sup>29,30</sup> show women had a significantly higher prevalence of C-shaped roots than men. These discrepancies may reflect differences in sample size and participants' ethnic background.

In present study, unilateral (93.83%) presence of C- shaped canal was higher than bilateral (6.17%) which is in contrast to the study done by Sung Eun et al<sup>30</sup> which showed higher bilateral prevalence. This discrepancy might be due to variable ethnic background and uniform large sample size. As our sampling frame is amalgamation of mixed community, culture and race.

Limitation of the study: Data were totally relied upon record book. The configuration type of C-shaped could not be assessed as it was retrospect. And moreover, the radiographic data were simple radiovisiography record and clinical assessment record was based upon loupes and naked eye. For more accurate and precise analysis cone beam computed tomography (CBCT) and Operating microscope would have been better tools. Indeed it would add extra cost and radiation exposure burden to the patients.

In light of the present study results, clinicians should consider age, sex, and ethnicity when determining root canal morphology prior to root canal treatment. The results of this study furnish useful information for C-shaped canal anatomy for effective endodontic treatment, serving as a valuable diagnostic tool in endodontics.

## CONCLUSIONS

Understanding the prevalence of morphologic variation of root canal system of the any locality is baseline requirement for any clinician for better presumptive visualization and successful treatment outcome. The present study will certainly instigate the clinician to study the prevalence of C- shaped canals in different regions of Nepal.

**Conflict of Interest:** None

NJHS

## REFERENCES

1. Vertucci FJ. Root canal anatomy of the human permanent teeth. *Oral surgery, oral medicine, oral pathology*. 1984 Nov 1;58(5):589-99.[PubMed: [6595621](#)] [https://doi.org/10.1016/0030-4220\(84\)90085-9](https://doi.org/10.1016/0030-4220(84)90085-9) | DOI: [10.1016/0030-4220\(84\)90085-9](#)
2. Jerome CE. C-shaped root canal systems: diagnosis, treatment, and restoration. *Gen Dent*. 1994;42:424–7.[ PubMed: [7489874](#)]
3. Manning SA. Root canal anatomy of mandibular second molars. Part II. C-shaped canals. *Int Endod J*. 1990;23:40–5.[PubMed: [2391180](#)] | DOI: [10.1111/j.1365-2591.1990.tb00801.x](#)]
4. Manning SA. Root canal anatomy of mandibular second molars. Part I. *Int Endod J*. 1990;23:34–9. [PubMed: [2391179](#)] | DOI: [10.1111/j.1365-2591.1990.tb00800.x](#)]
5. Rahimi S, Shahi S, Lotfi M, Zand V, Abdolrahimi M, Es'haghi R. Root canal configuration and the prevalence of C-shaped canals in mandibular second molars in an Iranian population. *J Oral Sci*. 2008;50:9–13. [PubMed: [18403877](#)] DOI: [10.2334/josnusd.50.9](#)]
6. Weine FS. The C-shaped mandibular second molar: Incidence and other considerations. Members of the Arizona Endodontic Association. *J Endod*. 1998;24:372–5. [PubMed: [9641116](#)] DOI: [10.1016/s0099-2399\(98\)80137-4](#) ]
7. Yang ZP, Yang SF, Lin YC, Shay JC, Chi CY. C-shaped root canals in mandibular second molars in a Chinese population. *Endod Dent Traumatol*. 1988;4:160–3. [PubMed: [3267526](#)] | DOI: [10.1111/j.1600-9657.1988.tb00315.x](#)]
8. Haddad GY, Nehme WB, Ounsi HF. Diagnosis, classification, and frequency of C-shaped canals in mandibular second molars in the Lebanese population. *J Endod*. 1999;25:268–71. [PubMed: [10425954](#)] [https://doi.org/10.1016/S0099-2399\(99\)80157-5](https://doi.org/10.1016/S0099-2399(99)80157-5) | DOI: [10.1016/S0099-2399\(99\)80157-5](#)]
9. Gulabivala K, Aung TH, Alavi A, Ng YL. Root and canal morphology of Burmese mandibular molars. *Int Endod J*. 2001;34:359–70. [PubMed: [11482719](#)] <https://doi.org/10.1046/j.1365-2591.2001.00399.x> | DOI: [10.1046/j.1365-2591.2001.00399.x](#)]
10. Gulabivala K, Opananon A, Ng YL, Alavi A. Root and canal morphology of Thai mandibular molars. *Int Endod J*. 2002;35:56–62. [PubMed: [11853239](#)] <https://doi.org/10.1046/j.1365-2591.2002.00452.x> | DOI: [10.1046/j.1365-2591.2002.00452.x](#)]
11. Seo MS, Park DS. C-shaped root canals of mandibular second molars in a Korean population: Clinical observation and in vitro analysis. *Int Endod J*. 2004;37:139–44. [PubMed: [14871181](#)] <https://doi.org/10.1111/j.0143-2885.2004.00772.x> | DOI: [10.1111/j.0143-2885.2004.00772.x](#)]
12. Velmurugan N, Sandhya R. Root canal morphology of mandibular first premolars in an Indian population: A laboratory study. *Int Endod J*. 2009;42:54–8. [PubMed: [19125980](#)] <https://doi.org/10.1111/j.1365-2591.2008.01494.x> | DOI: [10.1111/j.1365-2591.2008.01494.x](#)]
13. Sandhya R, Velmurugan N, Kandaswamy D. Assessment of root canal morphology of mandibular first premolars in the Indian population using spiral computed tomography: An in vitro study. *Indian J Dent Res*. 2010;21:169–73. [PubMed: [20657082](#)] <https://www.ijdr.in/text.asp/2010/21/2/169/66626>]
14. Fan B, Ye W, Xie E, Wu H, Gutmann JL. Three-dimensional morphological analysis of C-shaped canals in mandibular first premolars in a Chinese population. *Int Endod J*. 2012;45:1035–41. [PubMed: [22698143](#)] <https://doi.org/10.1111/j.1365-2591.2012.02070.x>]
15. Yu X, Guo B, Li KZ, Zhang R, Tian YY, Wang H, et al. Cone-beam computed tomography study of root and canal morphology of mandibular premolars in a western Chinese population. *BMC Med Imaging*. 2012;12:18. [PubMed: [22817397](#)] DOI: [10.1186/1471-2342-12-18](#) ]
16. Baisden MK, Kulild JC, Weller RN. Root canal configuration of the mandibular first premolar. *J Endod*. 1992;18:505–8. [PubMed: [1289476](#)] [https://doi.org/10.1016/S0099-2399\(06\)81352-X](https://doi.org/10.1016/S0099-2399(06)81352-X) | DOI: [10.1016/S0099-2399\(06\)81352-X](#)]
17. Sidow SJ, West LA, Liewehr FR, Loushine RJ. Root canal morphology of human maxillary and mandibular third molars. *J Endod*. 2000;26:675–8. [PubMed: [11469300](#)] <https://doi.org/10.1097/00004770-200011000-00011> | DOI: [10.1097/00004770-200011000-00011](#)]
18. Cleghorn BM, Christie WH, Dong CC. Root and root canal morphology of the human permanent maxillary first molar: A literature review. *J Endod*. 2006;32:813–21. [PubMed: [16934622](#)] <https://doi.org/10.1016/j.joen.2006.04.014> | DOI: [10.1016/j.joen.2006.04.014](#)]
19. Sidow SJ, West LA, Liewehr FR, Loushine RJ. Root canal morphology of human maxillary and mandibular third molars. *J Endod*. 2000;26:675–8. [PubMed: [11469300](#)] <https://doi.org/10.1097/00004770-200011000-00011> | DOI: [10.1097/00004770-200011000-00011](#)]
20. Kuzekanani M, Haghani J, Nosrati H. Root and canal morphology of mandibular third molars in an Iranian population. *J Dent Res Dent Clin Dent Prospects*. 2012;6:85–8.[PubMed: [22991643](#)] DOI: [10.5681/joddd.2012.018](#)]
21. Giri H. An exploration of ethnic dynamics in Nepal. *Journal of Population and Development*. 2020; 27(1):71-8.[DOI: <https://doi.org/10.3126/jpd.v1i1.33106>]
22. Cohen S, Burns RC. *Pathways of the pulp*. 8th ed. St. Louis: Mosby, 2002;196–229.
23. Melton DC, Krell KV, Fuller MW. Anatomical and histological features of C-shaped canals in mandibular second molars. *J Endod*. 1991;17:384–8. [PubMed: [1809802](#)] [https://doi.org/10.1016/S0099-2399\(06\)81990-4](https://doi.org/10.1016/S0099-2399(06)81990-4) | DOI: [10.1016/S0099-2399\(06\)81990-4](#) ]
24. Chai WL, Thong YL. Cross-sectional morphology and minimum canal wall widths in C-shaped roots of mandibular molars. *J Endod*. 2004;30:509–12. [PubMed: [15220648](#)] <https://doi.org/10.1097/00004770-200407000-00012> | DOI: [10.1097/00004770-200407000-00012](#)]
25. M. S. Seo and D. S. Park, “C-shaped root canals of mandibular second molars in a Korean population: clinical observation and in vitro analysis,” *International Endodontic Journal*. 2004;37(2):139–144.[<https://doi.org/10.1111/j.0143-2885.2004.00772.x>] | DOI: [10.1111/j.0143-2885.2004.00772.x](#)]
26. G. C. Jin, S. J. Lee, and B. D. Roh, “Anatomical study of C-shaped canals in mandibular second molars by analysis of computed tomography,” *Journal of Endodontics*. 2006;32(1):10–13.[ <https://doi.org/10.1016/j.joen.2005.10.007>] | DOI: [10.1016/j.joen.2005.10.007](#)]
27. D. Helvacioğlu-Yigit and A. Sinanoğlu, “Use of cone-beam computed tomography to evaluate C-shaped root canal systems in mandibular second molars in a Turkish subpopulation: a retrospective study,” *International Endodontic Journal*. 2013;46(11):1032–1038.[ <https://doi.org/10.1111/j.1365-2591.2011.01904.x>] | DOI: [10.1111/j.1365-2591.2011.01904.x](#)]
28. Q. Zheng, L. Zhang, X. Zhou et al., “C-shaped root canal system in mandibular second molars in a Chinese population evaluated by cone-beam computed tomography,” *International Endodontic Journal*. 2011;44(9):857–862.[ <https://doi.org/10.1111/j.1365-2591.2011.01896.x>] | DOI: [10.1111/j.1365-2591.2011.01896.x](#)]
29. S. Y. Kim, B. S. Kim, and Y. Kim, “Mandibular second molar root canal morphology and variants in a Korean subpopulation”. *International Endodontic Journal*. 2016;49(2):136–144.[ <https://doi.org/10.1111/iej.12437>] | DOI: [10.1111/iej.12437](#)]
30. Yang SE, Lee TY, Kim KJ. Prevalence and Morphology of C-Shaped Canals: A CBCT Analysis in a Korean Population. *Scanning*. 2021 May 29;2021. [<https://doi.org/10.1155/2021/9152004>] | DOI: [10.1155/2021/9152004](#)]