

## Sphenopalatine Ganglion Block versus Conservative Management for Post Dural Puncture Headache in Cesarean Section

Chetan Bohara,<sup>1</sup> Rajesh Maharjan,<sup>1</sup> Subi Regmi,<sup>1</sup> Gunjan Regmi,<sup>2</sup> Amresh Kumar Singh,<sup>1</sup> Anup Shrestha<sup>3</sup>

<sup>1</sup>Department of Anesthesiology and Critical Care, Lumbini Medical College and Teaching Hospital, Pravas, Palpa, Nepal;

<sup>2</sup>Department of Anesthesiology and Critical Care, Birat Medical College, Biratnagar, Nepal;

<sup>3</sup>Department of Surgery, Chitwan Medical College and Teaching Hospital, Chitwan, Nepal.

### ABSTRACT

**Introduction:** Post dural puncture headache is one of the frequently encountered and inevitable post-operative complications of subarachnoid block. The primary treatment is always considered as a conservative management in such instance. However, epidural blood patch remains an invasive gold standard treatment. Sphenopalatine ganglion block is propounded as minimally invasive with prompt and better outcome.

**Objective:** To assess the efficacy of Sphenopalatine ganglion block (SPGB) when compared to conservative management based on onset of analgesia and its duration.

**Methods:** This is a prospective study performed in 40 obstetrics patients who underwent Lower segment cesarean section in Lumbini Medical College and Teaching Hospital (LMCTH) who complained of Post dural puncture headache within 7 days. All the parturients are categorized into Group A, those who are treated with sphenopalatine ganglion block and Group B, where post dural puncture headache was treated with conservative management. Independent t-test and Fischer's test were used for statistical analysis.

**Results:** The patients in group A showed positive outcome where all of them were relieved of post dural puncture headache within 10 mins after Sphenopalatine ganglion block ( $p < 0.001$ ) and mean pain score, based on numerical pain rating scale was less or equal to 4 for first 8 hours.

**Conclusions:** Sphenopalatine ganglion block (SPGB) could be used as an effective first line treatment modality in the management of post dural puncture headache with compared to conservative management.

**Keywords:** Cesarean section; pain; post-dural puncture; sphenopalatine ganglion block.

### INTRODUCTION

Subarachnoid block (SAB) remains the best option for lower limbs, perineal and obstetrics surgery since its discovery. Post-dural puncture headache (PDPH) was the first clinical concern for anesthesiologists, and it remains so today.<sup>1,2</sup>

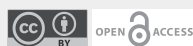
The incidence and severity of PDPH varies according to the types, bores of needle and number of attempts.<sup>3</sup> The first response to PDPH in the clinical practice is conservative management which fails to show prompt result and it may take up to 7-10 days. However, The gold standard treatment for PDPH is an autologous epidural blood patch (AEBP),<sup>4,5</sup> which has its own set of advantages and disadvantages.<sup>6,7</sup>

The SPGB is simple, easy and can be done at bedside or the out-patient department. It addresses sphenopalatine ganglion mediated compensatory parasympathetic vasodilation of cerebral blood vessels in response to decreased CSF pressure post

#### Correspondence

Dr. Chetan Bohara.

Email: chetan\_bohara@hotmail.com



#### Citation

Bohara C, Maharjan R, Regmi S, Regmi G, Singh AK, Shrestha A: Sphenopalatine Ganglion Block versus Conservative Management for Post Dural Puncture Headache in Cesarean Section. *Nepal J Health Sci.* 2022 Jan-Jun; 2(1): 22-6.

dural puncture which is one of the factors responsible for PDPH. SPGB's effectiveness in the treatment of chronic migraine, cluster headaches, and atypical orofacial pain is well-known. As a result, SPGB provides a beneficial, less invasive treatment option with a low risk of side effects and the potential for numerous uses in such situations.<sup>8,9</sup>

In this study, we compared SPGB with conservative management for PDPH in obstetrics patient who underwent lower section cesarean section (LSCS). We also assessed the onset, duration, in addition to, development of any adverse effects associated with the block.

## METHODS

After approval from the hospital ethical committee of Lumbini Medical College and Teaching Hospital (LMCTH), this prospective comparative study was conducted on 40 obstetric patients from September 2020 to January 2021 as per protocol.

All the parturients provided written informed consent before inclusion. Eligible parturients were adults (aged > 18 years), American society of anesthesiologist Grade II undergoing SAB for cesarean section who developed Post-dural puncture headache (PDPH). PDPH was assessed using numerical pain rating scale (NRS) as a moderate to severe pain score ranging from 4-10 in upright position that developed within 3 days. The head ache must have persisted for at least 1 day accompanied by at least one of these symptoms such as neck stiffness, photophobia, nausea, hypoacusia as per criteria of International Headache Society after dural puncture and must have intractable to treatment with fluids, caffeine and codamol, thus matching our criteria for eligible patient.

Patients were excluded if there are unable to cooperate with study protocols, had a history of allergy to Lidocaine or had received opioids less than 12 hours before study inclusion. Patients with known coagulopathy, nasal septal deviation, nasal

polyp, history of nasal bleeding and allergy to local anesthetics were also excluded in our study.

The patients fulfilling the inclusion criteria were randomized based on computer based randomization numbers into two groups: Group A (Sphenopalatine ganglion block) n=20, Group B (Conservative management) n=20. Neither patients nor the investigators were blinded. Group A received intranasal sphenopalatine ganglion block (SPGB). This minimally invasive procedure was performed in Obstetrics ward by soaking 4% lidocaine in a cotton-tipped applicator which was inserted through both the nares simultaneously directed parallel to the floor of the nose until resistance encountered. Our aim was to place the end of the applicator tips at or near the area superior to the middle turbinate and anterior to the pterygopalatine fossa and sphenopalatine ganglion in supine position. The applicators were kept in place for 5 minutes then removed.

Group B patients were managed conservatively. They were given oral codamol (combination of paracetamol and codeine) 1 tablet thrice a day and advised to increase fluid intake, caffeine, abdominal binder and bed rest.

Pain was assessed prior to procedure using numerical pain rating scale (NRS) (0 – no pain to 10–worst pain imaginable) after 5 min, the patient was asked to sit up and presence of headache was assessed using NRS. Pain was reassessed at 10 mins, 4 and 8 hours after the procedure. Inj. tramadol along with antiemetic was planned as a rescue drug for patients with persistent NRS score of 7 or more.

On the basis of post-dural puncture headache, a sample size of forty patients was calculated and divided into two groups of twenty patients each. The mean and standard deviation were used to express quantitative data. SPSS (Statistical Package for the Social Sciences) version 16 was used to conduct the statistical analysis. To compare the two groups, the independent t-test and Fischer's test were utilized. A p value of 0.05 was judged significant.

**RESULTS**

A total of 40 patients were included in this study. The patients in both the groups were comparable with respect to the age (Table 1) and the difference was not statistically significant ( $p>0.05$ ). Pre-procedural pain scores were also comparable between the groups with a p value of 0.778. In group A, all patients had adequate pain relief (NRS  $<4$ ) in 10 mins after initiation of the treatment, whereas in group B, all patients had not adequate pain relief (NRS $>4$ ). The difference was highly statistically significant ( $p<0.001$ ).

During the same moment, in group A, the mean pain score was  $< 3$  abruptly after 10 minutes which was persistent up to 4 hours and from 4-8 hours the mean pain score remained  $< 4$ . (Figure 1) In group B, after conservative management, the mean pain score was

$< 6$  after 10 minutes which gradually settled up to 5 and after 4 hours increased to  $> 6$  at 8 hours and subsequently it was maintained at  $< 6$  throughout the study period. While comparing the mean pain score, it was found that from 4-8 hours, group A had significantly lower pain score, whereas from 10 minutes to 8 hours, all the patients had significantly lower pain score compare to group B which is highly statistically significant. ( $p$  value  $<0.001$ ).

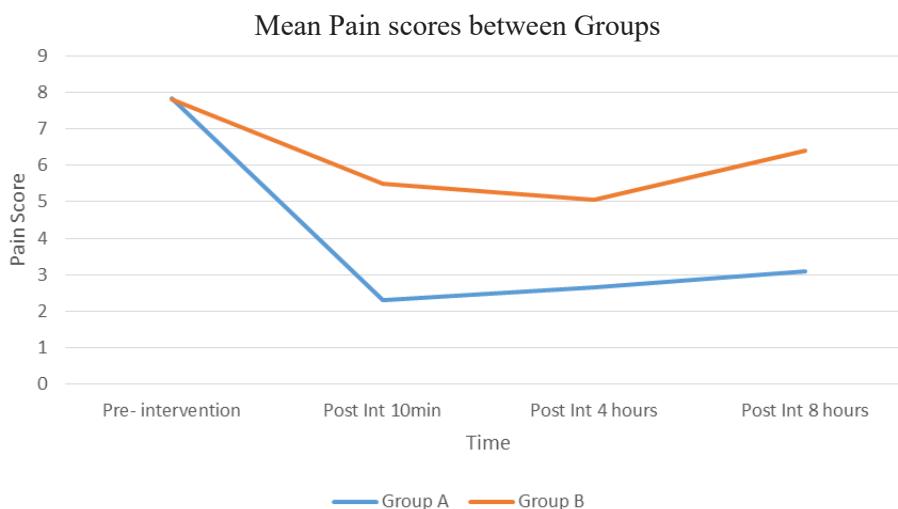
On comparing the two groups, the mean pain score in group B dropped gradually and reached a value  $< 6$  after 4 hours and was not maintained at that level, whereas in group A after the block was performed, the mean pain score was  $\leq 4$  throughout the study period. Onset of analgesia was significantly quicker in group A as compared to group B as the mean pain score illustrates ( $2.30\pm 0.92$  vs.  $5.50\pm 1.10$ ),  $p$  (Table 2)

**Table 1: Comparison of patient characteristics between two groups.**

Patient Characteristic	Group A (Mean $\pm$ SD)	Group B (Mean $\pm$ SD)	p-value
Age	24.1 $\pm$ 3.09	24.25 $\pm$ 2.59	0.869

**Table 2: Comparison of mean pain score ( $<0.001$ ).**

Time	Group A (Mean $\pm$ SD)	Group B (Mean $\pm$ SD)	p-value
Pre- intervention	7.85 $\pm$ 0.58	7.80 $\pm$ 0.52	0.778
Post Int 10min	2.30 $\pm$ 0.92	5.50 $\pm$ 1.10	$<0.001$
Post Int 4 hours	2.65 $\pm$ 1.08	5.05 $\pm$ 1.63	$<0.001$
Post Int 8 hours	3.10 $\pm$ 1.25	6.40 $\pm$ 1.39	$<0.001$



**Figure 1: Mean pain score.**

## DISCUSSION

This study demonstrated that SPGB is more effective than conservative management in the treatment of PDPH. SPGB had faster onset of action and was found to provide adequate pain relief with NRS < 4 throughout the study period compare to conservative management with NRS > 6. And there was no significant difference found in age parameters in both groups. In previous multiple studies done on this similar topic, the researchers had studied the good impact of block in between 24 - 48.<sup>10,11</sup> In our case all the patients in Group A showed immediate and constant relief from PDPH and there were no further complaints. So, duration of our observation was limited to 8 hours and highly statistically significant too.

Despite, Epidural blood patch regarded as the gold standard for the treatment of PDPH, it might bring multiple iatrogenic complications like meningitis, subdural hematoma, hearing loss, horner's syndrome, sensory and motor defecits.<sup>12</sup> Risk of another dural puncture always remains intense and evident even for an experienced anesthesiologist in EDP and need of another EDP if the previous one fails. In such instances, SPGB could be chosen as a good alternative treatment measure which is minimally invasive without any major adverse effects. SPSG via transnasal approach is non invasive, low risk technique, which can be easily performed at bedside without using any imaging tools. It has been widely used in the treatment of migraine headaches, cluster headache, trigeminal neuralgia and orofacial pain.<sup>11</sup>

Sphenopalatine ganglion is a parasympathetic, extracranial neural structure that is triangular in shape and around 5 mm in size. The sphenopalatine ganglion is found in the pterygopalatine fossa's superficial portion, posterior to the middle nasal turbinate and anterior to the pterygoid canal.<sup>2</sup> Pterygopalatine ganglion, Meckel's ganglion, and nasal ganglion are all names for the sphenopalatine ganglion. Sympathetic, parasympathetic, and somatic sensory roots are found in the sphenopalatine

ganglion. Within the ganglion, only the preganglionic parasympathetic fibers synapse. Somatic sensory fibers from the maxillary division of the trigeminal nerve travel via the ganglion, as do postganglionic sympathetic neurons.<sup>8</sup>

To maintain equilibrium, the volume of one element must rise while the amount of another constituent decreases. As a result of Dural tear following Dural puncture, there is a continuous leak of CSF through it. As a result, compensatory vasodilation occurs in an attempt to maintain intracranial volume, resulting in headache.<sup>13</sup> By inhibiting parasympathetic-induced vasodilation, SPGB provides symptomatic relief.

Yang IY et al. had published a paper regarding SPGB as a novel and simple anesthetic technique for the treatment of headache and facial pain.<sup>14</sup> Therefore, SPGB could be done successfully even by a novice and doesn't require any highly skilled and experienced anesthesiologist.

There were numerous case reports found relevant to the management of PDPH, most with an SPGB or greater occipital nerve block. Kent et al. mentioned the efficacy of SPGB in three obstetrics patients. In their case they used 2% lidocaine for 10 minutes and result was immediate, all patients were pain relieved.<sup>15</sup> We administered 4 % lidocaine in 20 parturients and result was same as mentioned in their study. Therefore, there is no significant difference between two same local anesthetics with different concentration. Hany E. Fares et al. had also mentioned about no significant difference while comparing three local anesthetic drugs such as lidocaine 2%, lidocaine 5% and Bupivacaine 0.5% in their study.<sup>3</sup>

Purva Kumrawat et al.<sup>10</sup> mentioned in their study which was done in 18 parturients who underwent C-section under spinal anesthesia that SPGB is more effective than conservative management in the treatment of PDPH in the first 24 hrs. SPGB has faster onset of action versus conservative

management. However, there was no statistical difference between the groups with regard to duration of analgesia. While comparing two groups, each containing 20 parturients in our study for first 8 hours after initiating of SPGB and conservative therapy, SPGB showed the fastest action as well as highly statistically significant.

Cohen and colleagues conducted a retrospective study of 81 patients comparing SPSG block with EBP and found a larger number of patients with significant pain relief at 30 and 60 min after treatment with SPG block than with EBP.<sup>16</sup> However, they were unable to detect significant differences in headache relief at 1, 2 and 7 days after treatment. The treatment administered by us differs somewhat from their study as we did not need to repeat the doses after initial administration and none of the patients complained after the procedure.

## CONCLUSIONS

Transnasal SPSG can be used as first line of treatment for post dural puncture headache with compared to conservative management. It is emerging as a safe option for the treatment of PDPH. Therefore, it can be considered as an efficient, less invasive and cost effective modality. More well-designed studies are needed to further explore the efficacy of this treatment modality and its use as part of a comprehensive PDPH management program.

The limitations of this study are relatively small sample size, no consideration of height, weight, lower patient follow-up duration and were only conducted in obstetric group of patients.

**Conflict of Interest:** None

**NJHS**

## REFERENCES

1. Reynolds F. Dural puncture and headache. *BMJ*. 1993 Apr 3;306(6882):874-6. doi: 10.1136/bmj.306.6882.874. PMID: 8490408; PMCID: PMC1677390.
2. Kwak KH. Postdural puncture headache. *Korean J Anesthesiol*. 2017 Apr;70(2):136-143. doi: 10.4097/kjae.2017.70.2.136. Epub 2017 Feb 3. PMID: 28367283; PMCID: PMC5370299.
3. Mohamed, Salah & Abdelfattah, Khaled & Fares, Hany. (2020). Comparative study between lidocaine 2%, lidocaine 5% and bupivacaine 0.5% in transnasal sphenopalatine ganglion block for the treatment of postdural puncture headache. *Indian journal of applied research*. 1-5. 10.36106/ijar/5620295.
4. Choi YN, Kang SJ, Joo JD, Kim YM, In JH, Park YJ. Targeted Transforaminal Epidural Blood Patch for Postdural Puncture Headache in Patients with Postlaminectomy Syndrome. *Case Rep Neurol Med*. 2019 Jun 19;2019:1968314. doi: 10.1155/2019/1968314. PMID: 31321107; PMCID: PMC6607722.
5. Fournet-Fayard A, Malinovsky JM. Céphalées post-brèches méningées et blood-patch: aspects théoriques et pratiques [Post-dural puncture headache and blood-patch: theoretical and practical approach]. *Ann Fr Anesth Reanim*. 2013 May;32(5):325-38. French. doi: 10.1016/j.annfar.2013.02.014. Epub 2013 Apr 6. PMID: 23566592.
6. Safa-Tisseront V, Thormann F, Malassiné P, Henry M, Riou B, Coriat P, Seebacher J. Effectiveness of epidural blood patch in the management of post-dural puncture headache. *Anesthesiology*. 2001 Aug;95(2):334-9. doi: 10.1097/0000542-200108000-00012. PMID: 11506102.
7. Paech, Michael James. "Epidural blood patch - myths and legends." *Canadian Journal of Anesthesia* 52 (2005): R47.
8. Oluigbo CO, Makonnen G, Narouze S, Rezai AR. Sphenopalatine ganglion interventions: technical aspects and application. *Prog Neurol Surg*. 2011;24:171-179. doi: 10.1159/000323049. Epub 2011 Mar 21. PMID: 21422787.
9. Nagib M, Hood P, Matteo J. Sphenopalatine Ganglion Block: Treatment of Migraine and Trigeminal Neuralgia Associated With Multiple Sclerosis. *Cureus*. 2020 Jun 9;12(6):e8522. doi: 10.7759/cureus.8522. PMID: 32656035; PMCID: PMC7346333.
10. Kumrawat, Purva & P., Krishna & P, Shankaranarayana. (2020). A Comparative Study of Sphenopalatine Ganglion Block versus Conservative Management for the Treatment of Post-dural Puncture Headache. *Journal of Evidence Based Medicine and Healthcare*. 7. 657-660. 10.18410/jebmh/2020/143.
11. Puthenveetil N, Rajan S, Mohan A, Paul J, Kumar L. Sphenopalatine ganglion block for treatment of post-dural puncture headache in obstetric patients: An observational study. *Indian J Anaesth*. 2018 Dec;62(12):972-977. doi: 10.4103/ija.IJA\_443\_18. PMID: 30636799; PMCID: PMC6299770.
12. Marr R, Kapoor A, Redfern N. Epidural blood patch is the gold standard treatment for dural puncture headache. *Br J Anaesth*. 2012 Aug;109(2):288-9; author reply 289. doi: 10.1093/bja/aes240. PMID: 22782983.
13. Mokri B. The Monro-Kellie hypothesis: applications in CSF volume depletion. *Neurology*. 2001 Jun 26;56(12):1746-8. doi: 10.1212/wnl.56.12.1746. PMID: 11425944.
14. Yang IY, Oraee S. A novel approach to transnasal sphenopalatine ganglion injection. *Pain Physician*. 2006 Apr;9(2):131-4. PMID: 16703973.
15. Kent S, Mehaffey G. Transnasal sphenopalatine ganglion block for the treatment of postdural puncture headache in obstetric patients. *J Clin Anesth*. 2016 Nov;34:194-6. doi: 10.1016/j.jclinane.2016.04.009. Epub 2016 May 11. PMID: 27687372.
16. Cohen S, Levin D, Mellender S, Zhao R, Patel P, Grubb W, Kiss G. Topical Sphenopalatine Ganglion Block Compared With Epidural Blood Patch for Postdural Puncture Headache Management in Postpartum Patients: A Retrospective Review. *Reg Anesth Pain Med*. 2018 Nov;43(8):880-884. doi: 10.1097/AAP.0000000000000840. PMID: 30063655.