

# Gross and Micro anatomical Study of Placenta from Normal and Hypertensive Pregnancies

Jyoti Mishal,<sup>1</sup> Chandra Bhushan Jha,<sup>2</sup> Shailaja Chhetri Shrestha,<sup>3</sup>  
Yamuna Agrawal,<sup>4</sup> Archana Chaudhary,<sup>5</sup> Nikky Maharjan<sup>6</sup>

<sup>1</sup>Department of Human Anatomy, BP Koirala Institute of Health Sciences, Dharan, Nepal;

<sup>2</sup>Department of Human Anatomy, BP Koirala Institute of Health Sciences, Dharan, Nepal;

<sup>3</sup>Department of Gynecology and Obstetrics, BP Koirala Institute of Health Sciences, Dharan, Nepal;

<sup>4</sup>Department of Pathology, BP Koirala Institute of Health Sciences, Dharan, Nepal;

<sup>5</sup>National Academy of Medical Sciences (NAMS), Bir Hospital, Kathmandu, Nepal;

<sup>6</sup>Emergency Department, Alka Hospital, Jawalakhel, Lalitpur, Nepal;

## ABSTRACT

**Introduction:** The examination of placenta gives a clear idea of what had happened with fetus, when it was in the mother's womb. The changes in placenta of women with pregnancy induced hypertension and normal pregnancies can be compared.

**Objective:** This study was done to find out differences in gross structure and histology between normal and hypertensive placentas.

**Methods:** Placenta from case and control group was collected from the Gynecology and Obstetrics Department of B.P.Koirala Institute of Health Sciences, Dharan. The histology slides were prepared, examined and parameters was collected.

**Results:** The mean weight of placenta in control group was  $469.5 \pm 148.9$  gm and in case group was  $375.50 \pm 109.08$  gm which was statistically significant. The histological observation of syncytial knot, hyalinized villi, stromal fibrosis, necrosis, hemorrhage and calcification in placenta was significantly higher in case group than that of in normotensive group.

**Conclusions:** It is concluded that, in hypertension complicating pregnancy, with increase of severity, there is decrease in morphology and increase in abnormal histological changes of placenta. So, the reduction in placental morphological parameters and histological changes might be the reason for retarded growth of baby with increased complication of hypertension.

**Keywords:** Gross of placenta; histology of placenta; placenta; pregnancy induced hypertension.

## INTRODUCTION

The placenta is the chief regulator of nutrient supply to the growing embryo during gestation.<sup>1</sup> Pregnancy induced hypertension (PIH) is a sustained rise of blood pressure to 140/90 mm Hg or more on at least two occasions 4 or more hours apart beyond the 20th week of pregnancy or during the first 24 hours after delivery in a previously normotensive woman.<sup>2</sup>

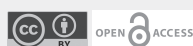The hypertensive disorders complicating pregnancies are quite common. Fetal distress, intrauterine fetal deaths and placental abnormalities are common in pregnancy induced hypertension.<sup>3</sup> It is a leading cause of maternal and perinatal morbidity and mortality.<sup>4</sup> It usually develops after 20 weeks of gestation and resolves after delivery of placenta.<sup>5</sup> The condition complicates 2–8% of pregnancies.<sup>6</sup>

Pregnancy induced hypertension is very common in our country and to the best of my knowledge of investigation, little or no work is done here to evaluate placental changes in this condition. This study was designed to evaluate changes in placenta of women with pregnancy induced hypertension and compare these with placenta of normal pregnancies.

### Correspondence

Jyoti Mishal

Email: [jyoti.mishal@mbahs.edu.np](mailto:jyoti.mishal@mbahs.edu.np)



### Citation

Mishal J, Jha CB, Shrestha SC, Agrawal Y, Chaudhary A. Gross and Micro anatomical Study of Placenta from Normal and Hypertensive Pregnancies. *Nepal J Health Sci.* 2022 Jan-Jun; 2(1):7-11.

## METHODS

This study was a case control study. For this study, sample was collected from Gynecology and Obstetrics Department of B.P. Koirala Institute of Health Sciences, Dharan in one year (August 2014 to August 2015). A total of 100 placentas of 50 from normotensive and 50 from hypertensive pregnant women were collected. For this study, proportional quota sampling of purposive sampling method was used. Inclusion criteria included full term pregnant women (Gestational week 36-40). Exclusion criteria was pregnant women having complication other than pregnancy induced hypertension like gestational diabetes mellitus, acquired immune-deficiency syndrome (AIDS, Hepatitis). The experimental procedures were explained verbally and written informed consent was obtained before enrollment. The study was ethically approved by Institutional Ethics Committee.

The collected specimen was dried. The membrane and umbilical cord was trimmed. The measurement for weight, diameter and thickness were noted. The insertion of umbilical cord was observed. Each specimen was labeled separately and then transferred to 10% formal saline solution for fixation. For histological examination, the permanent slides

of the placental tissues for its histopathological evaluation was prepared; the preserved placentas were processed by fixation, dehydration, clearing and impregnation. Embedding and microtomy was done. The slides were stained by H&E stain and microscopy was done.

The collected data was entered in Microsoft Excel 2010 and converted into SPSS 16.0 for statistical analysis. For Descriptive Statistics, mean, SD % and proportion was calculated along with graphical and tabulated presentation. For inferential statistics, Chi-Square and Independent T-test were applied to find out the significant difference between hypertensive and non-hypertensive placenta at 95% confidence interval where probability value (P) is 0.05.

## RESULTS

Mean weight, diameter, thickness and number of cotyledon were 375.50 gm, 13.86 cm, 1.12 cm and 15.40 in case group and 469.5gm, 14.83cm, 1.69cm and 17.76 in control group respectively. These shows statistically significant value. However, there was no significant difference of insertion of cord between case and control. Table 2 shows that the weight, diameter, thickness and cotyledon of placenta are decreasing with increase of severity of PIH.

**Table 1: Morphology of Placenta.**

Placental morphology	Control Group (Mean ± SD)	Case group (Mean ± SD)	Statistical Significance
Mean Weight of placenta (grams)	469.5±148.9	375.50± 109.08	<0.05
Mean Diameter of Placenta (cms.)	14.83±1.57	13.86 ± 1.49	<0.05
Mean Thickness of Placenta (cms.)	1.69±0.37	1.12 ± 0.22	<0.05
Mean number of Cotyledon	17.76±3.50	15.40± 2.71	<0.05

**Table 2: Relation of morphology of placenta with severity of hypertension.**

Morphology of placenta	PIH (Mean ± SD)	Pre-eclampsia (Mean ± SD)	Eclampsia (Mean ± SD)
Weight of Placenta (gm)	406.73 ± 95.80	344.12 ± 125.48	335.71 ± 89.97
Placental Diameter (cm)	14.10 ± 1.40	13.87 ± 1.62	12.94 ± 1.28
Placental Thickness (cm)	1.18 ± 0.24	1.06 ± 0.17	1.03 ± 0.23
Cotyledon	16.19 ± 2.79	14.71 ± 2.76	14.14 ± 1.22

**Table 3: Histology of Placenta.**

Histology of Placenta	Control (No. of cases)	Case (No. of cases)	Remarks
Syncytial knot	19 (38%)	42 (84%)	< 0.05
Hyalinized Villi	9 (18%)	33 (66%)	< 0.05
Stromal Fibrosis	21 (42%)	46 (92%)	< 0.05
Necrosis	8 (16%)	18 (36%)	< 0.05
Calcification	10 (20%)	29 (58%)	< 0.05
Hemorrhage	12 (24%)	30 (60%)	< 0.05

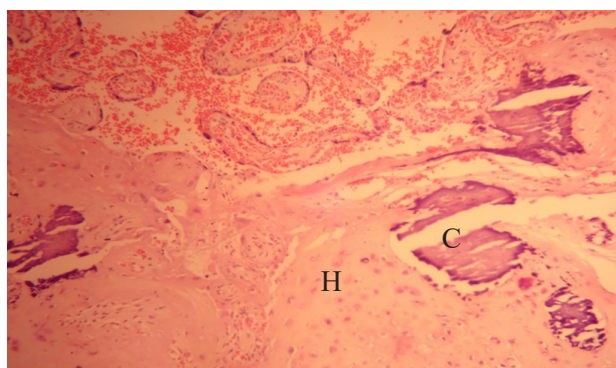
**Table 4: Relation of histology of placenta with severity of PIH.**

Histology of Placenta	PIH	Pre-eclampsia	Eclampsia
Syncytial knot	20 (84.61%)	15 (88.24%)	7(100%)
Hyalinized villi	16 (61.53%)	11 (64.71%)	6 (85.71%)
Stromal Fibrosis	23 (88.46%)	16 (94.11%)	7 (100%)
Necrosis	7 (26.92%)	7 (41.18%)	6 (57.14%)
Calcification	14 (53.85%)	10 (58.82%)	5 (71.43%)
Hemorrhage	14 (53.85%)	11 (64.71%)	5 (71.43%)

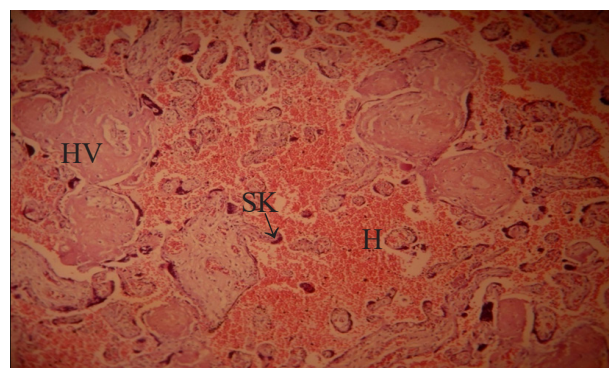
There was significant increase of syncytial knot, hyalinization, stromal fibrosis, necrosis, calcification and hemorrhage (84%, 66%, 92%, 36%, 58% and 60% respectively) in case group than in control group (38%, 18%, 42%, 16%, 20% and 24% respectively) (Table 3).

The severity of PIH has direct relation with the abnormal changes in histology of placenta. Syncytial knot was found 84.61% of total PIH, 88.24% of total Pre-eclampsia and 100% of total eclampsia.

Hyalinized villi was found 61.53% of total PIH, 64.71% of total Pre-eclampsia and 85.71% of total eclampsia. Fibrosis in PIH was 88.46%, in pre-eclampsia was 94.11% and in eclampsia was 100%. Necrosis in PIH was 26.92%, in pre-eclampsia was 41.18% and in eclampsia was 57.14%. Hemorrhage in PIH was 53.85%, in pre-eclampsia was 64.71% and in eclampsia was 71.43%. Calcification in PIH was 53.85%, in pre-eclampsia was 58.82% and in eclampsia was 71.43%. (Table 4)



**Figure 1: Hyalinization (H) and Calcification (C) in histology of hypertensive placenta (H&E; 100X)**



**Figure 2: Histology of villi of hypertensive placenta showing Hyalinised villi (HV), Hemorrhage (H) and Syncytial Knot (SK) (H&E; 100X)**

## DISCUSSION

The anatomical and pathological examinations and assessments are becoming more precise and considered as an indirect or non-invasive method for the study of human placenta.<sup>7</sup> In present study, the mean weight of placenta in control group was  $469.5 \pm 148.9$  gm and in case group was  $375.50 \pm 109.08$  gm which was statistically significant. The mean placental diameter in case group was  $13.86 \pm 1.49$  cm which was statistically reduced than that of control group ( $14.83 \pm 1.57$  cm). Mean placental thickness was  $1.69 \pm 0.37$  cms in control group and  $1.12 \pm 0.22$  cms in hypertensive group.

In control group, mean number of cotyledon was  $17.76 \pm 3.50$  whereas in case group, it was  $15.40 \pm 2.71$ , which showed statistically significant value. Udaina and Jain also found placental weight in control group 495.05 gm and 405.67 in case group which was higher than present study.<sup>8</sup> Similarly, Modi et al. also reported weight  $<400$  gm; volume  $<400$  ml; thickness  $<2$  cm and diameter  $<18$  cm of placenta in PIH<sup>9</sup> which supports the findings of present study.

A similar study by Baloch et al. found that the placental weight and the diameter from hypertensive group were significantly less than that from normotensive group, whereas they found statistically no significant differences in number of cotyledons and central thickness in both groups.<sup>10</sup> which is different from the present study as number of cotyledon and mean thickness of placenta from hypertensive group is significantly reduced than control group.

The histological observation of syncytial knot, hyalinization, stromal fibrosis, necrosis, calcification and haemorrhage (84%, 66%, 92%, 36%, 58% and 60% respectively) in case group placenta was significantly higher than that of in normotensive group. A similar study by Core CR et al. reported calcification 86.7% in case group than 36.7% in control group<sup>11</sup> which is higher than that of present study. A study by Majumdar et al. reported the

same.<sup>12</sup> Another study by Singh and Gugapriya also observed increased frequency of syncytial knots, stromal fibrosis, necrosis, haemorrhage and calcification in hypertensive group.<sup>13</sup>

A study by Ahmed and Daver<sup>14</sup> reported calcification was present in 15.38%, 30% and 50% of the cases of mild, moderate and severe PIH respectively which was less than the present finding 53.85%, 58.82% and 71.43% in PIH, pre-eclampsia and eclampsia respectively.

## CONCLUSIONS

From this study, it is concluded that the weight, diameter and thickness and cotyledon of placenta are significantly reduced in hypertensive group than in normotensive group. In histological finding there are significant increase in syncytial knot, hyalinization, stromal fibrosis, necrosis, hemorrhage and calcification in hypertensive group than that of normotensive group.

The study also concluded that, with increase of severity, there is decrease in morphology and increase in abnormal histological changes of placenta. So, the reduction in placental morphological parameters and increased histological changes might be the reason for fetal growth retardation in preeclampsia. Higher incidence of PIH is mostly due to malnutrition, ignorance, lack of adequate health education, and medical care. If proper medical care is given during antenatal period and labor, then further risk to mother and fetus can be reduced.

## ACKNOWLEDGEMENT

we would like to acknowledge the Department of Human Anatomy, the Department of Obstetrics and Gynecology and the Department of Pathology of B.P.Koirala Institute of Health Sciences, Dharan for permitting to conduct this study.

**Conflict of Interest: None**

**NJHS**

## REFERENCES

1. Woods, Laura et al. Regulation of Placental Development and Its Impact on Fetal Growth-New Insights from Mouse Models. *Frontiers in endocrinology* vol. 9 570. 27 Sep. 2018, doi:10.3389/fendo.2018.00570.
2. Datta DC. *Text book of obstetrics*. 2001;P.234.
3. Chakravorty AP. Fetal and placental weight changes in normal pregnancy and pre-eclampsia. *J Obstet Gynaecol Br Commonwealth*. 1967. PMID: 6022374 DOI: 10.1111/j.1471-0528.1967.tb14868.x.
4. Gohil JT, Patel PK, Gupta P. Estimation of lipid profile in subjects of preeclampsia. *J Obstet Gynecol India*. 2011;61(4):399–403. PMID: 22851820 PMID: PMC3295880 DOI: 10.1007/s13224-011-0057-0.
5. Boyd, P. A. and Scott A. Quantitative structural studies on human placenta associated with preeclampsia, essential hypertension and intrauterine growth retardation. *Br J Obstet Gynaecol*. 1985;714–21. PMID: 4016032 DOI: 10.1111/j.1471-0528.1985.tb01454.x.
6. Dastur Adi E, Tank PD. The pharmacology of preventing preeclampsia. *J Obstet Gynecol India*. December 2010 60(6):486-493 DOI:10.1007/s13224-010-0060-x.
7. Oliveira LH, Xavier CC LA. Alteracoes morfologicas placentarias de recém-nascidos pequenos para a idade gestacional. *J Pediatr*. 2002;78:397–402. PMID: 14647746.
8. Udainia, A., and M. L. Jain. Morphological study of placenta in pregnancy induced hypertension with its clinical relevance. *J Anat Soc India* 50.1 (2001): 24-27.
9. Modi H H, Umaraniya Y N, Prajapati H K, Rathod J B, Chauhan H M. Morphological study of placenta in pregnancy induced hypertension. *IJSR - Int J Sci Res*. 2013;2(9). Volume: 2 | Issue: 9 | September 2013 • ISSN No 2277 – 8179.
10. Baloch AH, Memon SF, Ansari AK. Comparison of Placentae from Hypertension Associated Pregnancies and Normal Pregnancies. *JLUMHS*. 2012;11(1).
11. CR Gore, Aditi Pandey, Abhinav Shetty, Ruby Rao, Sourabh Paranjape. A study on histopathological changes in placenta in pre-eclampsia/eclampsia: A case-control study in tertiary care centre, western India. *Indian Journal of Pathology and oncology*. Volume: 5, Issue: 3, Year: 2018. DOI: 10.18231/2394-6792.2018.0075
12. Majumdar S, Dasguptha H, Bhattacharya K, Bhattacharya A. A study of placenta in normal and hypertensive pregnancies. *J Anat Soc India*. 2005; 54:34–8.
13. Singh, Sabita, and T. S. Gugapriya. Microanatomical analysis of hypertensive placentae-a retrospective case control study. *National Journal of Clinical Anatomy* 2.1 (2013): 5.
14. Ahmed M, Daver R.G. Study of placental changes in pregnancy induced hypertension. *International Journal of Reproduction, Contraception, Obstetrics and Gynecology*. DOI: 10.5455/2320-1770.ijrcog20131207