

Histopathological spectrum of breast lesions at B.P Koirala Memorial Cancer Hospital

Greta Pandey¹, Asmita Rana², Ranjan Raj Bhatta¹, Suraj Upreti¹, Nandita K. Jha¹, Ishan Dhungana¹.

¹. Department of Pathology, B. P. Koirala Memorial Cancer Hospital, ². Department of Cancer Prevention, Control and Research, B. P. Koirala Memorial Cancer Hospital

Abstract:

Background: Breast lumps are the commonest presentation in surgical outpatient clinics in females. Breast is a complex organ structure. It shows a wide range of pathologies from benign inflammatory lesions to invasive life threatening lesions. Breast cancer has become the commonest cancer in females after cervix cancer also in Nepal. Modern diagnostic facilities have helped a lot for early detection of breast lesions and treatment. The present study was conducted at a tertiary cancer center in Nepal that focused on the identification of histopathological spectrum of breast biopsies received and their relations with epidemiological variables.

Methods: This is a retrospective study of all the breast biopsies which were received, processed and analysed at Department of Pathology at B.P. Koirala Memorial Cancer Hospital from January to December 2019. The data were retrieved from the Department of Pathology. They were entered in Microsoft excel.

Results: A total 216 breast tissues specimen of true-cut biopsy and lumpectomy were examined in the year 2019. The age range was from 18-75 years. There were 37.1% benign cases and 62.9% of malignant. There were 7 male patients in this study. Most of the cases belonged to age group of 40-49 years.

Conclusion: This study shows the burden of breast cancer in Nepal. It also highlights the importance of histopathology in breast lesions not only in diagnosing the lesion but also in

Corresponding Author: Dr Greta Pandey, Department of Pathology, B. P. Koirala Memorial Cancer Hospital, Bharatpur, Chitwan, Nepal. Email: pandeygreta@hotmail.com

predicting the prognosis. Malignant lesions of breast were frequent in this study due to our center being a cancer referral hospital. This retrospective study shows that a variety of lesions are encountered in breast and histopathology helps to differentiate between various benign and malignant lesions.

Key words : Breast lesions, Breast Cancer, pathology, Biopsy

Introduction:

Breast is an anatomical structure under a constant influence of various sex hormones and a common site of neoplasm¹. Breast lumps produce anxiety and worry to patients who present to the clinics. Various diseases affect the breast tissues which arise from the glandular epithelium, stratified squamous epithelium and mesenchymal connective tissue. These sometimes become a diagnostic challenge to us^{2,3}. Histopathological study of the breast lumps is an important aspect for the diagnosis and management of breast diseases. Pathological diagnosis helps us to understand more about prognosis and treatment of the diseases².

Each year the incidence of cancer is increasing, according to 2020 data from GLOBOCAN, breast cancer comprises 9.6% of all the cancers and is the most common cancer after lung and cervical cancer⁴. The purpose of this study is to identify the

spectrum of breast diseases visiting B.P Koirala Memorial Cancer Hospital and to give a clinico-pathological profile.

Methodology

This is a retrospective cross-sectional study of breast tissue specimen of true-cut biopsy and lumpectomy received from January 2019 to December 2019 in the Department of Pathology, B. P. Koirala Memorial Cancer Hospital. Old known cases of malignancy, recurrent cases and inadequate sample with normal parenchyma were excluded from the study. The received specimens were labelled, entered in the data system of the laboratory, and kept overnight for fixation in 10% Formalin. After grossing, it was processed in the tissue processor, making blocks, and cut into sections of 0.5-micron thickness. After staining with hematoxylin and eosin, slides were examined by pathologists. The findings were recorded in the patients' database. The information regarding age, gender, ethnicity

and histopathological diagnosis were retrieved from the database.

Statistical Analysis

The data were entered and cleaned in Microsoft Excel 2016. Descriptive statistics were used to infer the results. The data was presented in frequency distribution tables, bar graph and pie chart.

Results

A total of 216 breast tissue specimens of true-cut biopsy and lumpectomy was examined in the year 2019. The specimens received were from 7 males and 209 females. The age of the patients ranged from 18 to 75 years. The mean age of the patients was 47.4 years. Most of the cases belonged to the age-group of 40-49 years (31.2%) (Table 1).

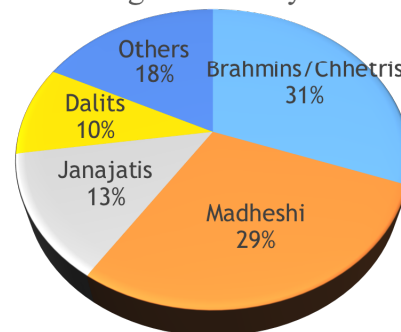
Around 37 percentage of the lesions were benign while the remaining 63 percentage were malignant. Only benign lesions were found in the younger age-group of 10-19 years and only malignant lesions in the older age group of 70-79 years. Most of the malignant lesions were reported in the age-group of 40-49 years (67.2%) (Table 1). Regarding the ethnicity, most of the cases

belonged to Brahmins/Chhetris followed by Madhesi ethnicity (Figure 1).

Table 1: Distribution of benign and malignant lesions according to age (n=216)

Age-group (in years)	Benign lesions	Malignant lesions	Total
10-19	4	0	4 (1.8%)
20-29	12	6	18 (8.3%)
30-39	22	19	41 (18.9%)
40-49	22	45	67 (31.2%)
50-59	12	29	41 (18.9%)
60-69	8	28	36 (16.7%)
70-79	0	9	9 (4.2%)
Total	80 (37.1%)	136 (62.9%)	216 (100%)

Figure 1: Distribution of cases according to Ethnicity



There were 80 benign cases (37%) and 136 malignant cases (63%). Most of the benign lesions were fibroadenoma (37.5% of the benign cases), followed by 17 cases of mastitis (21.2% of the benign), 14 cases of

ductal hyperplasia (17.5% of the benign cases), 4 cases of chronic granulomatous mastitis (5% of the benign cases) and 4 cases of phyllodes tumor (5% of the benign cases). There were 3 cases of fibrocystic disease of breast (3%), single case of myoepithelioma and papilloma. Gynecomastia was present in 2 males. Other benign lesions included duct ectasia and fat necrosis. Among the malignant lesions, the commonest diagnosis was Invasive carcinoma no specific type (90.5% of the malignant cases). There were 5 cases of Invasive lobular carcinoma (3.7% of the malignant lesions), 2 cases of Ductal carcinoma in situ high grade (1.5% of the malignant lesions), 2 cases of squamous cell carcinoma (1.5% of the malignant lesions), single case of metaplastic carcinoma (0.7% of the malignant lesions) , single case of Invasive papillary carcinoma (0.7% of the malignant lesions), mucinous carcinoma and medullary carcinoma (Table 2). Fibroadenoma was commonest in the age-group of 30-39 years while Invasive carcinoma of no specific type was commonest in the age-group of 40-49 years (Table 3).

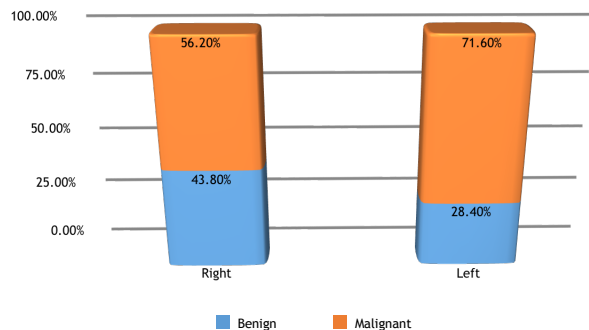
Table 2: Distribution of cases according to histopathological diagnosis

Diagnosis	Histopathology	No. of cases	Percent age (%)
Benign	Fibroadenoma	30	37.5
	Mastitis	17	21.2
	Chronic granulomatous mastitis	4	5.0
	Duct hyperplasia	14	17.5
	Phyllodes tumor	4	5.0
	Fibrocystic disease of breast	3	3.7
	Myoepithelioma	1	1.2
	Papilloma	1	1.2
	Gynecomastia	2	2.5
	Other benign	4	5.0
Total	80	100	
Malignant	Invasive Carcinoma No Specific Type	123	90.5
	Invasive Lobular Carcinoma	5	3.7
	Ductal Carcinoma in situ high grade	2	1.5
	Metaplastic carcinoma	1	0.7
	Squamous cell carcinoma	2	1.5
	Invasive Mucinous carcinoma	1	0.7

Invasive papillary carcinoma	1	0.7
Medullary carcinoma	1	0.7
Total	136	100
Grand total	216	100

Table 3: Distribution of Fibroadenoma and Invasive breast carcinoma No Specific Type (IBC NST) according to age

Fibroade noma	Age-group (in years)	IBC NST
4	10-19	0
7	20-29	4
10	30-39	19
4	40-49	40
5	50-59	29
0	60-69	24
0	70-79	9
30	Total	125



Around 56% of the lesions of the right breast were malignant while 43.8% were benign. In the left breast, about 72% of the lesions were malignant while 28% were benign (Figure 2).

Discussions:

Worldwide the incidence of breast cancer is increasing and it is the most common cancer according to GLOBOCAN 2020.⁴ It is the second most common cancer in females after cervix cancer in Nepal⁵. Its incidence is also increasing in developing countries and often gets diagnosed at late stage. However, recently this has changed a little due to increasing awareness about cancer and advanced technology in diagnostics.⁵

In this study a total 216 cases were studied in which 37% cases were benign and 63% cases were malignant lesions of the breast. This data is different from other studies where there are more benign cases than malignant because our hospital is a tertiary referral center for cancer cases. The age group of 40-60 was the most commonly affected by malignant lesions while benign lesions were common in 30-50 years. This is similar to the study by Rakesh et al where females aged between 41-60 years had higher prevalence of breast cancer. The mean age group for

malignant lesions was 47.4 which was similar to study by Pathak et al and Afsharfard et al.^{6,7} The incidence of male breast cancer was low in our study. Out of 7 cases of male breast lumps; 2 cases were gynaecomastia similar to other studies.⁸ There were 5 cases of malignant breast lesions in male histopathologically compatible with invasive breast carcinoma of no special type. Male breast cancer constituted 3.6% of all breast cancer. It is similar to the other studies where incidence is low in males.⁶ Unilateral involvement of breast was more common when compared to bilateral involvement. Left breast was more affected than right breast in this study group which was comparable to other study.⁴

Chettri (42.73%) was the most frequently affected ethnic community in our hospital where we treat people from whole Nepal. Distribution of cases according to ethnicity, demonstrates that similar to ours, most common were Chhetri's / Brahmins(31%) followed by Madhesi.⁹

In this study, the most common age group for benign lesions was 4th decade while 5th decade for malignant lesions. The most susceptible age group was between 40- 50

years.⁶ Kakarala et al reported a higher incidence of invasive breast carcinoma in Asian Indian/Pakistani women as compared to lobular carcinoma.¹⁰

Fibroadenoma was the most common benign tumour and invasive breast carcinoma of no special type was the most common malignant tumour.¹¹ This was followed by inflammatory diseases of the breast. These lesions are of clinical significance because of their potential for getting confused with cancer.¹² Inflammatory lesions constitute 22.6% in previous study by Rakesh et al⁸ same as in our study which is 21.2% of all benign lesions. Other benign lesions were chronic granulomatous mastitis, ductal hyperplasia, phyllodes tumour, fibrocystic changes, myoepithelioma, papilloma, gynaecomastia and fat necrosis which were similar varieties of pathological diseases seen in other studies.² Granulomatous mastitis is a rare inflammatory condition with chronic progression however their importance lies in their importance of mimicking carcinoma clinically and radiologically.¹³ We have seen few cases of phyllodes tumour (5%) as compared to other studies showing 4.05% in their study.^{14,15}

Regarding the histopathological typing of the malignant lesions, invasive breast carcinoma of no special type were 123 out of 136 cases (90.5%), invasive lobular carcinoma (3.7%), ductal carcinoma in situ were 1.5%. Other cases were squamous cell carcinoma, mucinous carcinoma, invasive papillary carcinoma, mucinous carcinoma and medullary carcinoma. Similar to these finding the most common cancer was invasive breast carcinoma of no special type in other studies as well. There were single cases of metaplastic carcinoma, mucinous carcinoma and papillary carcinoma.^{5,6,16}

There were 2 cases of Squamous cell carcinoma which are of rare occurrences. It is important to distinguish this type from mixed tumours, where some patches of squamous cells can be found in adenocarcinoma of the breast and from metastasis of squamous cell carcinoma that originated elsewhere. The etiology and pathogenesis of squamous cell carcinoma of the breast is still unclear¹⁷. We had single case of metaplastic carcinoma. Metaplastic carcinoma are rare type of breast cancer accounting for the 1% of all the invasive breast cancer. Metaplastic Breast carcinoma(MCB) is often misdiagnosed

preoperatively as ordinary breast cancer. Since anticancer agents are not effective for MCB, surgery must be the preferred first choice treatment over preoperative anticancer drug therapy.¹⁸

Conclusion:

This study highlights the burden of breast cancer in Nepal. It is very important for us to undertake preventive measures and create awareness regarding breast cancer. Triple test is very helpful in this regard. Histopathological examination is the gold standard for the diagnosis of the breast lump and also to perform various other immunohistochemical tests including hormonal status in them. This study has given us an overview of the spectrum of breast lesions at BPKMCH. A more comprehensive study with more number of patients is needed in future.

References:

1. Mistry S, Gandhi M, Patel P et al. A study of histopathological assessment of mastectomy specimen. *International Journal of Medical Science and Public Health* (2013) vol 2,issue 3:523-528.
2. Maru A, Menapara C.B. A study of histopathological spectrum of non-malignant breast lesions. *Trop J Path Micro* 2018; 4(6): 439-444.

3. Damjanov I, Linder J. Anderson's Pathology. 10th edi. St. Louis, Mo: Mosby; 1999.
4. <https://gco.iarc.fr/today/data/factsheets/populations/524-nepal-factsheets.pdf>.GLOBOCAN
5. Sasank R, Annapurna P. A histopathological study of malignant lesions of breast in a tertiary care centre .International Journal of Medical Science and Clinical Intervention. 2018 July;5(07):3955-3958.
6. Histopathological evaluation of carcinoma of breast. Pathak R, Jha A, Neupane PR, Chalise S, Basnyat AS. Journal of Pathology of Nepal (2016)vol 6, 922-927.
7. Afsharfard A, Mozaffar M, Orang E et al. Trends in epidemiology, clinical and histopathological characteristics of breast cancer in Iran: results of a 17 year study. Asian Pac J Cancer Prev 2013;14:6905-11.
8. A clinicopathologic study of breast lumps in Bhairahwa, Nepal. R.Kumar. Asian Pacific J Cancer Prev 11, 855-858.
9. Devkota H, Menyangbo S, Amgain K. Spectrum of breast diseases in a rural Himalayan region of western Nepal: a hospital based study. Journal of Chitwan Medical College .2020 ;10(3),95-97.
10. Khan GM, Thapa RK, Adhikari DS et al. Cancer prevention trend in central region of Nepal. Journal of Chitwan Medical college 2013;3:22-5.
11. Histopathological spectrum of breast lesions- A hospital based study. G. Gogoi, D. Borgohain. IJHRMLP, vol:02 No: 01 January, 2016.
12. Fine needle aspiration cytology versus tru cut biopsy in the diagnosis of breast cancer-A comparative study. C.A Shashirekha, R.R. Singh, H.R. Ravikiran, Krishna Prasad and PN Sreeramulu. Indian Journal of Biomedical Research 2017;8(09):497-500.
13. Benign breast diseases. Profile at a teaching hospital. OB Karki, D Kunwar, A. De. American journal of public health research vol3, no 4A (2015):83-86.
14. Hafiz MA, Shafaq S, Hiba A et al. Clinicopathological profile of patients with breast diseases .Diagnostics path 2013:8:77.
15. Rosai J, Masciadri N, Ferranti C. Benign breast lesions :ultrasound .J Ultrasound 2011;14(2);55-65.
16. An institutional review of tumour biology of breast in young Nepalese women. B. Nepal, Y. Singh , P. Sayami .Journal of Society of Surgeons of Nepal 2015 ;18(2).
17. Kshirsagar AY, DShmukh S.J, Jagtap SV et al. Squamous cell carcinoma of breast. Am J Case Report (2013);14:188-190.
18. Keiichi Takahash .A rare case of metaplastic carcinoma of the breast that could be diagnosed with preoperative core needle biopsy and the improbability of skin invasion. International Journal of Surgery Open.2018; The Author. Published by Elsevier Ltd on behalf of Surgical Associates Ltd.