

Case Report

Patient with False Negative RT-PCR for COVID-19 referred to Cancer Hospital for Lung Cancer Screening

^{1,2}Yadav Ajay Kumar, ¹Gnawali Suman, ¹Mandal Sandip Kumar, ¹Shrestha Gyan Bahadur, ²Yuan Gangbiao

¹Department of Radio-diagnosis, Imaging and Nuclear Medicine, BP Koirala Memorial Cancer Hospital, Bharatpur, Nepal, ²Department of Nuclear Medicine, The Second Affiliated Hospital of Chongqing Medical University, PR China

Abstract

Background: To describe the characteristics and outcomes of patients with a clinical diagnosis of COVID-19 and false-negative SARS-CoV-2 reverse transcription-PCR (RT-PCR), and develop and internally validate a diagnostic risk score to predict risk of COVID-19 (including RT-PCR-negative COVID-19) among medical treatment.

Case presentation: Herein, we report a 42-year-old male patient from myagdi district Nepal presenting with high grade fever, dry cough, headache and dizziness on the August 10, 2021 during second phase of COVID-19 pandemic. There is no history of hypertension and diabetes. He went for RT-PCR test at local COVID-19 screening center and reported as negative for RT-PCR test. After that he referred to Lumbini Zonal hospital for further evaluation. RT-PCT swab test was performed again and reported negative. On the chest X-Ray, there was opacity on both lungs and the patient was referred to cancer hospital for lung cancer screening. The patient underwent for HRCT chest and biochemical laboratory tests for further evaluation. The chest High Resolution Computed Tomography (HRCT) indicated ground glass opacity (GGO) with crazy paving a typical COVID-19 interstitial pneumonia. In the biochemical laboratory test, there were elevation in Leukocyte (Total WBC count), Neutrophil, Glucose, Bilirubin Direct, Bilirubin Total, SGOT/AST, SGPT/ALT and Lactate Dehydrogenase (LDH). There was low count found in Lymphocyte, Eosinophil and Monocyte. These laboratory parameters findings are typical sign of COVID-19 patients. Then patient was isolated and treatment of given according to COVID-19 treatment guidelines. On September 12, 2021, all diagnostic tests showed that patient recovered from COVID-19.

Conclusion: It is safe to suggest that a symptomatic patient with typical chest HRCT and lab findings for COVID-19 should be quarantined or isolated even with 2 negative RT-PCR tests.

Keywords: COVID-19, RT-PCR, Pneumonia and HRCT

Introduction

First identified case of COVID-19 (named by WHO of Corona Virus Disease 2019) was found in Wuhan China which is an infectious disease caused by severe acute respiratory syndrome corona virus (SARS-CoV-2). The global pandemic of Covidid19, caused by the infection with Thesscov2, brought an unprecedented number of infectious and infectious patients who require admission to the hospital. The symptoms of the Covid19 can be non-specific, so the diagnostic confirmation in the hospital is often sought after detecting SARSCOV2

RNA sequences by reverse transcription (RTPCR) of a clinical sample.

According to the different world official guidelines, patients infected with SARS-COV-2 virus must be went for nasopharyngeal or oropharyngeal RT-PCR swab test and Chest X-ray imaging for first step and for the further detail evaluation, HRCT chest and biochemical laboratory test are recommended in case of discrepancy between clinical and radiographic characteristics [1]. There are several studies which have reported that the sensitivity of nasopharyngeal or oropharyngeal

Address of Correspondence: Yadav Ajay Kumar, 1Department of Radio-Diagnosis, Imaging and Nuclear Medicine, BP Koirala Memorial Cancer Hospital, Bharatpur, Chitwan, Nepal

RT-PCR swab test applied to respiratory tract specimens are only 60% to 70% due to different technical reasons (reagents, sample transport conditions, etc.), intrinsic limitations like viral load in different anatomic sites and sampling procedures [2].

Herein we report a COVID-19 suspect case with two-time negative RT-PCR test for COVID-19, finally diagnosed as interstitial COVID-19 pneumonia and treated according to COVID-19 treatment protocol and totally recovered.

Case Report

According to history taken by patients and their reports, we report a 42-year-old male patient from rural myagdi district Nepal presenting with high grade fever, dry cough, headache and dizziness on the August 10, 2021 during second phase of COVID-19 pandemic. The patient had no history of diabetes and hypertension in past. He underwent for RT-PCR test at local COVID-19 screening center at his home district and reported as negative in RT-PCR test. After that he referred to Lumbini Zonal hospital for further evaluation and treatment. Patient underwent for RT-PCR test and Chest X-Ray at Zonal Hospital and again reported negative RT-PCR test. On the chest X-Ray (figure-1), there was opacity on both lungs and the patient was referred to cancer hospital for lung cancer screening.

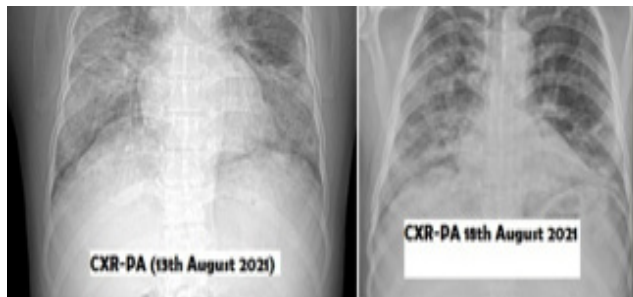


Figure-1 Showing Chest X-Ray of 42 years male RT-PCR negative patient bilateral opacity seen in both lungs (13th August) and decrease of infection seen on 18th August 2021

At BP Koirala Memorial Cancer hospital, the patient underwent for HRCT chest and biochemical laboratory tests for further evaluation. The chest High Resolution Computed Tomography (HRCT) indicated ground glass opacity (GGO) with crazy paving a typical COVID-19 interstitial pneumonia

on August 15, 2021 (figure-2).

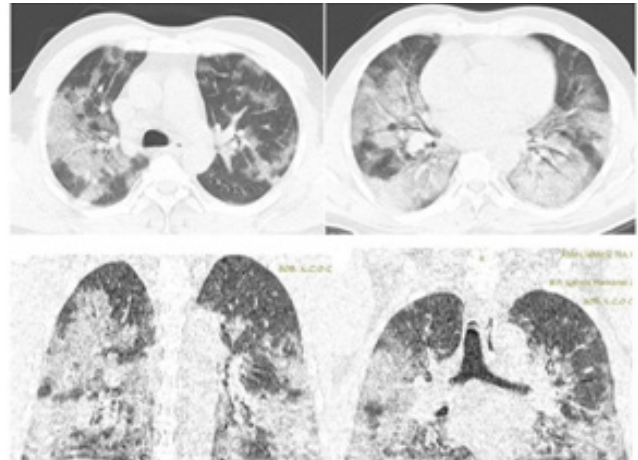


Figure-2, Showing HRCT of 42 years male RT-PCR negative patient with CT severity score was 21 reported as Severe, GGO appearance with crazy paving on August 15, 2021. Patient totally recovered from COVID.

In the biochemical laboratory test (August 15, 2021), there were elevation in Leukocyte (Total WBC count), Neutrophil, Bilirubin Direct, Bilirubin Total, SGOT/AST, SGPT/ALT and LDH. There was Lymphocytopenia noted. We followed up with regular laboratory tests of that patient with regular interval of time period. On August 18, 2021, there was elevation of random glucose level in spite of there was no history of diabetes in past. On August 25, 2021, there was low count found in eosinophil and monocyte. The laboratory parameters of the patients on deferent date during prognosis are summarized in table-1.

Table-1 Laboratory parameters of COVID-19 patient on different date during prognosis

Date (2021)	Aug-15	Aug-18	Aug-21	Aug-25	Sep-12
Hemoglobin	15 (N)	12.9 (L)	13 (L)	13.5 (L)	14.5 (N)
Leucocyte (WBC)	112000 (H)	79300 (H)	57000 (H)	8100 (N)	5500 (N)
Neutrophil	41 (N)	90 (H)	90 (H)	85 (H)	67 (N)
Lymphocyte	08 (L)	05 (L)	08 (L)	10 (L)	29 (N)
Eosinophil			01 (N)	00 (L)	03 (N)
Monocyte			01 (L)	01 (L)	02 (N)
Glucose R	123 (N)	171 (H)	145 (H)		
Bilirubin Total	1.94 (H)				
Bilirubin Direct	0.51 (H)				
SGOT/AST	62 (H)				
SGPT/ALT	41 (H)				
LDH	538 (H)	458 (H)	412 (H)	318 (H)	213 (N)

Abbreviations; N=Normal count, H=High count and L=Low count

These laboratory parameters findings are typical sign of COVID-19 patients. Then patient was isolated and treatment was given according to

COVID-19 treatment guidelines. On September 12, 2021, all diagnostic tests were normal and showed that patient recovered from COVID-19.

Discussion

There are several research studies which concluded that there is chance of false negative of RT-PCR dual swab test. There is one study which concluded that most False Negative results were due to low amounts of SARS-CoV-2 virus concentrations in patients with multiple specimens collected during different stages of infection. It is recommended to the subsequent clinical evaluation of each patient to ensure that RTPCR results are not the only factor to exclude Covid19 [3]. Disease control and prevention centers reported that “BinaxNOW antigen test performance compared to the real-time RTPCR was better for such specimens with a positive viral culture than all samples, with a sensitivity of the 92.6% for samples of symptomatic people and 78.6% for those of asymptomatic people “[4].

The decreased number of lymphocytes and the increased levels of LDH, neutrophil and liver function test levels are associated with SARS-COV-2 related pneumonia [5]. This can be useful as an additional diagnostic tool in patients with a highly suspicious double-tested and highly suspicious clinics and SARS-COV-2 virus infected characteristics COVID-19 patient should be isolate in a pandemic period [5].

In our case study, it showed that typical COVID-19 features in HRCT chest (ground glass opacity (GGO) with crazy paving). There were there was elevation in Leukocyte, Neutrophil, Liver Function Test (LFT) and LDH with Lymphocytopenia. One additional feature also found during prognosis i.e., elevation of random glucose level. There is induced diabetes has been noted, in case reports, to occur simultaneously with acute SARS-CoV-2 infection or in the weeks to months following recovery from the infection [6].

Conclusion

We concluded that it is in safe hands to advise that a symptomatic patient with chest HRCT with typical COVID-19 pneumonia features in lung and some altered laboratory findings i.e. elevation in Leukocyte, Neutrophil, Liver Function Test (LFT) and LDH with Lymphocytopenia should be quarantined or isolated even with 2 negative RT-PCR tests.

Advances in knowledge

SARS-COV-2 virus infection may develop diabetes.

Acknowledgments:

All the authors contributed equally to this article.

References

1. Kooraki S, Hosseiny M, Myers L, Coronavirus (COVID-19) outbreak: what the department of radiology should know. *J Am Coll Radiol* [Internet] 2020; 17:447–51.
2. Yang Y, Yang M, Shen C, et al. Evaluating the accuracy of different respiratory specimens in the laboratory diagnosis and monitoring the viral shedding of 2019-nCoV infections. *med Rxiv* 2020; doi 10.1101/2020.02.11.20021493.
3. Kanji et al. “False negative rate of COVID-19 PCR testing: a discordant testing analysis” *Virology* (2021) 18:13 <https://doi.org/10.1186/s12985-021-01489-0>
4. Evaluation of Abbott BinaxNOW Rapid Antigen Test for SARS-CoV-2 Infection at Two Community-Based Testing Sites — Pima County, Arizona, November 3–17, 2020, <https://www.cdc.gov/mmwr/volumes/70/wr/mm7003e3.htm>
5. Orlacchio, Antonio et. al. Correlations between chest-CT and laboratory parameters in SARS-CoV-2 pneumonia, *Medicine*: April 09, 2021 - Volume 100 - Issue 14 - p e25310 doi: 10.1097/MD.00000000000025310
6. Athish T, Kapoor N, Cao Y, Tapp R, Zimmet P, Proportion of newly diagnosed diabetes in COVID-19 patients: a systematic review and meta-analysis. *Diabetes Obes Metab*. 2020; 23: 870-874