

Case report

Melanoma of Urinary Bladder presented as acute urine retention.

Nirmal Lamichhane¹, Hari P Dhakal²¹Department of Surgical Oncology and ²Pathology, B. P. Koirala Memorial Cancer Hospital, Bharatpur, Chitwan, Nepal.**ABSTRACT**

This report is of a 50-year-old man with a rare urinary bladder melanoma. He presented with hematuria followed by bladder outlet obstruction at the time of presentation. Ultrasonogram of the pelvis revealed a mass in the bladder outlet, suggestive of enlarged prostate. Suprapubic cystostomy was then performed. Subsequent transvesical exploration revealed a dark coloured mass at the outlet of bladder, which on histopathology confirmed to be melanoma. After ruling out other possible primary sites, he underwent radical cysto-urethrectomy with urinary diversion. Disease was confirmed with immunohistochemistry. Patient died after 3 months with bilateral lung metastasis.

Keywords: Melanoma, Urinary bladder, Cystectomy, Prognosis.**INTRODUCTION**

Malignant melanoma of urinary bladder is a very rare entity and scantily reported in medical literature. Wheelock was the first to report a primary melanoma of the urinary bladder in 1942, and Su et al. reported the next case in 1962.^{1, 2} Approximately 50 patients with this tumour have been reported in the literature shown by Medline search. This is a nonurothelial /mesenchymal tumour of the urinary bladder. These tumors are accounting for 1% to 5% of all bladder tumours. The percentage of melanoma among this is not well reported.^{3, 4} The skin is the commonest site for melanoma and common site for visceral/mucosal melanoma is gastrointestinal tract. This patient is the first to present with this disease at the B. P. Koirala Memorial Cancer Hospital among the operations of urinary bladder performed till this date.⁵ Though the treatment was aggressive, prognosis is not comparable with commonest skin melanoma.

CASE PRESENTATION

A 50- years old male presented with total hematuria and difficulty in passing urine for two and half months and unable to pass urine for one day. Catheterization at local hospital was failed. At the time of presentation at emergency room, the urinary bladder was full up to umbilicus. The urinary catheterization was re-tried

but was not successful. Sonography was performed which showed enlarged prostate and distended bladder. Suprapubic cystostomy was performed that comforted the patient.

On asking, he had voiding type lower urinary tract symptoms for 2 and half months, but had no haematuria or fever. He had lost four kilograms of weight in this period. He had decreased appetite but was moving normal bowel motions. He was a smoker and social drinker. There was no history of trauma to the lower abdomen or perineum. He also had not got any skin or ocular lesions. The patient was not allergic to any medication. His family history was noncontributory. On examination he was well oriented, average in built and cooperative. Pallor was present. No superficial lymphadenopathy was present. Supra-pubic catheter was in situ and draining clear urine. There were some clots at the urethral meatus. On digital rectal examination, the prostate was enlarged, firm in consistency and non-tender to touch. No obvious skin or ocular lesions were visible.

His hemoglobin was 9.9 gm/dl. Ultrasound of the abdomen showed enlarged median lobe of prostate. Considering an enlarged prostate, transurethral resection was planned. Intra-operative findings revealed

Correspondence

Nirmal Lamichhane, Department of Surgical Oncology, BP Koirala Memorial Cancer Hospital
Bharatpur, Chitwan, Email: nlamichhane@hotmail.com

a black coloured mass at bladder neck, major bulk of which is arising at the trigone and growing towards prostatic urethra. Bilateral ureteric orifices were above the tumour and looking normal. The tumour was resected, the mucosa of the prostatic urethra also looked dark in colour and lumen was narrowed. As the findings were unusual, the tissue removed was sent for frozen section histopathology analysis which was suggestive of melanoma. We concluded the surgery with a urinary catheter.

The diagnosis later in conventional H & E stain was melanoma (Figure 1). Immunohistochemistry performed in the same tissue was positive for HMB-45 (Figure 2) and S-100 (Figure 3) confirming the diagnosis. (Immunohistochemistry by Courtesy Prof. Jahn M Nesland, Norwegian Radium Hospital, Oslo, Norway).

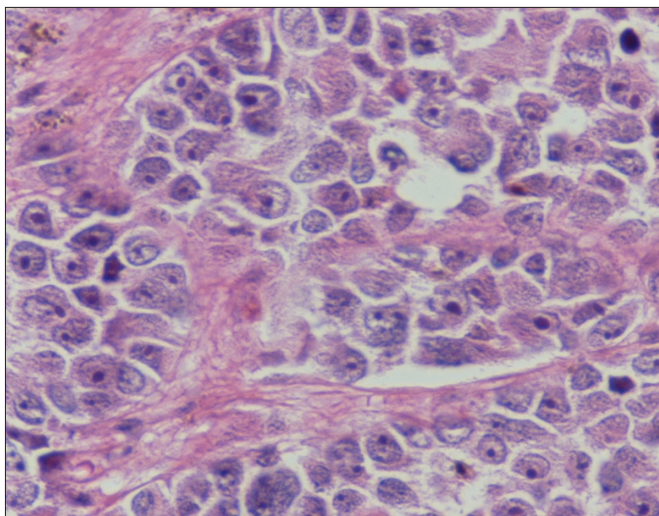


Figure 1: H&E stain of the tumour tissue. X 40 magnification.

We retrospectively examined the patient for any skin lesions. Metastatic workup with CT scan of the whole body did not reveal any other visceral lesions. After multi-disciplinary discussion, the disease was considered to be primary urinary bladder melanoma and underwent radical cystectomyprostatectomy and urethrectomy with bilateral pelvic lymph node dissection and ileo-caecal continent pouch urinary diversion. Post-operative recovery was uneventful. In final pathology, the primary bladder neck lesion was melanoma with muscle invasion and the iliac nodes were also harbouring the metastatic melanoma cells. Patient developed extensive bilateral pulmonary metastasis and survived only 3 months after

diagnosis.

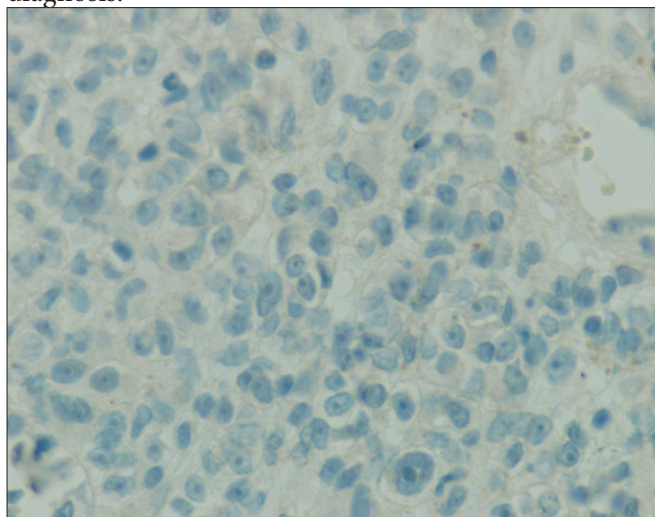


Figure 2: Immune-stain showing HMB 45 expression in tumour tissue. X 40 magnification

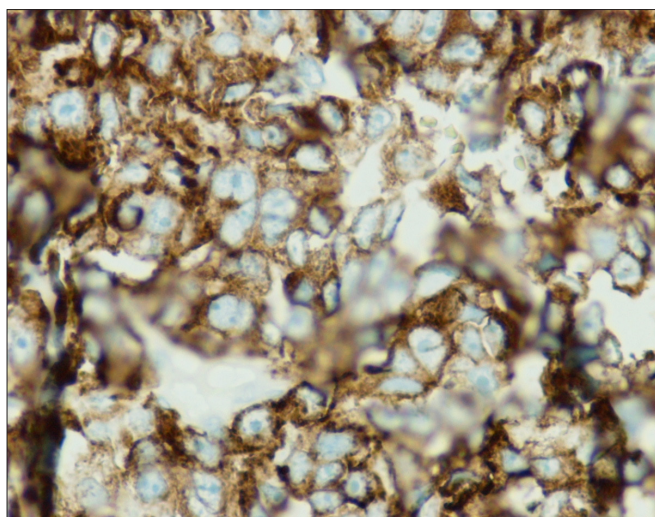


Figure 3: Immuno-stain showing strong S100 expression in tumour tissue. X 40 magnification

DISCUSSION

Primary melanoma of urinary bladder is a rare neoplasm. The histogenesis of primary bladder melanoma is uncertain, and an origin from cells of the neural crest has been proposed.³ To diagnose a case as primary melanoma, very strict criteria apply. In 1976, Ainsworth and associates were the first observers to carefully delineate criteria for defining primary malignant melanoma of the urinary bladder.³ These include (1) careful physical examination including the skin with Wood's light together with detailed history to

exclude cutaneous melanoma, (2) exclusion of visceral melanoma following exhaustive evaluation, (3) pattern of recurrence consistent with primary melanoma of the urinary bladder, and (4) histologically proved primary atypical melanocytes. This index patient of melanoma of the urinary bladder was the first of its type seen in B.P. Koirala Memorial Cancer Hospital.⁽⁵⁾

The symptoms caused by this tumour were varied, nonspecific and, in most of instances, depend on the location (intravesical, intramural or extramural).^{4, 6, 7} In this patient, the tumour was intravesical and at the outlet of bladder, causing bladder outlet obstruction. As the patient was a male in his fifties, it was considered to be a benign enlargement of prostate. Some authors have reported their patients having recurrent urinary tract infections.⁸

In this patient, the growth form of the tumour was involving mucosal as well as deeper layers, that is the most common form reported. However, some of the patients have an extravesical growth form.^{4, 7} Ultrasonography, CT scan, and cystoscopy can clearly delineate the exact position of the tumour most of the time, although transvaginal or transrectal ultrasonography may show better delineation.⁹ In addition, magnetic resonance images will clarify the position and size of the lesion.¹⁰ In this men, though USG and CT were done and both showed disease but we needed transuterhtal visualization to suspect the disease. Some authours have advocated the use of urine cytology in diagnosis as well.¹⁰

Reports show that surgical removal is the mainstay of treatment of melanoma in any site of the body. Melanoma is bad disease, have bad treatment options with grave prognosis. So it is crucial to evaluate metastatic workup before commencing aggressive treatment option. After proper evaluation; the surgical approach is chosen according to the site and size of the tumour. Transurethral resection of the lesion, partial cystectomy, radical cystectomy, chemotherapy, and radiation therapy had been used to treat melanoma of the urinary bladder.^{6, 11, 12} It was stated by some authors that, in all patients with localised tumour, radical surgery seemed to be the therapy of choice, although to date none of the patients survived more than three years despite cystectomy characterizing the poor prognosis of the tumour.^{13, 14} TUR is a good option for treatment of small tumours, but always not adhering to the surgical principle of wide local

excision.^{15, 16} In our patient, as the lesion was at bladder outlet, invading into deeper layer, cysto-urethrectomy with urinary diversion was performed. Though there are new promising therapies are upcoming, none of them have definitive role.^{17, 18} Tarhini et al., suggested the use of neoadjuvant chemotherapy and or immunotherapy in addition to surgery to improve the outcome of management.¹⁹ Kounalakis N in the analysis of 153 stage III melanoma found even aggressive systemic treatment prior to lymph node dissection does not significantly impact surgical outcomes.²⁰

In conclusion, malignant melanomas are aggressive diseases. Our patient died in 3 months due to extensive pulmonary metastasis. We report this case for the sake of its rarity. Individualization of treatment and multidisciplinary approaches are highlighted.

ACKNOWLEDGEMENTS

We thank Dr Min Chu Lee for his help with arrangement of frozen section biopsy of the tissue.

REFERENCES

1. Wheelock MC. Sarcoma of the urinary bladder. *The Journal of Urology*. 1942; 48: 628
2. Su CT, Prince CL. Melanoma of the bladder. *J Urol*. 1962; 87: 365-7.
3. Ainsworth AM CW, Mastrangelo M, Conger KB. Primary malignant melanoma of the urinary bladder *Cancer*. 1976; 37(4): 1928-36.
4. Goldschmidt P PJ, Kostakopoulos A, Jacqmin D, Grosshans E, Bollack C. Primary malignant melanomas of the urinary bladder. *Br J Urol*. 1988; 61(4): 359-61.
5. Thakur B. Annual Report BPKMCH 2014. Bharatpur: B P Koirala Memorial cancer hospital, Nepal, Urology; 2014.
6. Van Ahlen H, Nicolas V, Lenz W, Boldt I, Bockisch A, Vahlensieck W. Primary melanoma of urinary bladder. *Urology*. 1992; 40(6): 550-4.
7. Kojima T TT, Yoshimi N, Mori H. Primary malignant melanoma of the urinary bladder. *Arch Pathol Lab Med*. 1992; 116(11): 1213-5.
8. Lund L, Storgard L, Noer H. Primary malignant melanoma of the urinary bladder. Case report. *Scand J Urol Nephrol*. 1992; 26(2): 205-6.
9. Willis AJ, Huang AH, Carroll P. Primary melanoma of the bladder: a case report and review. *J Urol*. 1980; 123(2): 278-81.



10. Akbas A, Akman T, Erdem MR, Antar B, Kilicarslan I, Onol SY. Female urethral malignant melanoma with vesical invasion: a case report. *The Kaohsiung journal of medical sciences*. 2010; 26(2):96-8.
11. Khalbuss WE, Hossain M, Elhosseiny A. Primary malignant melanoma of the urinary bladder diagnosed by urine cytology: a case report. *Acta cytologica*. 2001; 45(4): 631-5.
12. El Ammari JE, Ahallal Y, El Fassi MJ, Farih MH. Primary malignant melanoma of the urinary bladder. *Case reports in urology*. 2011. 2011:932973.
13. deKernion JB GS, Gupta RK, Silverstein M, Morton DL. Successful transurethral intralesional BCG therapy of a bladder melanoma. *Cancer*. 1975; 36(5): 1662-64.
14. Dahm P GJ. Malignant non-urothelial neoplasms of the urinary bladder: a review. *Eur Urol*. 2003;44(6):672-80.
15. Venyo AK. Melanoma of the urinary bladder: a review of the literature. *Surgery research and practice*. 2014; 2014:605802.
16. Khan M, O'Kane D, Du Plessis J, Hoag N, Lawrentschuk N. Primary malignant melanoma of the urinary bladder and ureter. *The Canadian journal of urology*. 2016; 23(1): 8171-5.
17. Siroy AE, MacLennan GT. Primary melanoma of the bladder. *J Urol*. 2011; 185(3): 1096-7.
18. Schindler K, Schicher N, Kunstfeld R, Pehamberger H, Toepker M, Haitel A, et al. A rare case of primary rhabdoid melanoma of the urinary bladder treated with ipilimumab, an anti-CTLA 4 monoclonal antibody. *Melanoma research*. 2012; 22(4): 320-5.
19. Tarhini AA, Pahuja S, Kirkwood JM. Neoadjuvant therapy for high-risk bulky regional melanoma. *J Surg Oncol*. 2011; 104(4): 386-90.
20. Kounalakis N , Gao DX, Gonzalez R, Becker M,³ Lewis K , Poust J , et al. A neoadjuvant biochemotherapy approach to stage III melanoma; analysis of surgical outcomes. *Immunotherapy*. 2012 Jul; 4(7): 10.2217/imt.12.62.