

Original Investigation

Functional and Radiological Outcome after Anatomic Coracoclavicular Ligament Reconstruction for Type III to Type V Acromioclavicular Joint Dislocation Using Semitendinous Autograft

Rajiv Sharma* | Bibek Basukala² | Bikash Parajuli¹ | Jagadish Thapa¹ | Rabindra Regmi³ | Sandeep Sharma⁴

¹Department of Orthopaedics, Dhulikhel Hospital, Dhulikhel, Nepal; ²Department of Orthopaedics, B & B Hospital, Lalitpur, Nepal

³Department of Orthopaedics, National Trauma Center, Kathmandu, Nepal; ⁴Department of Orthopaedics, Janaki Medical College, Janakpur, Nepal

ARTICLE INFO

Article history:

Received: 17 August 2022

Revised: 02 October 2022

Accepted: 1 November 2022

*Correspondence:

Dr. Rajiv Sharma

Department of

Orthopaedics, Dhulikhel Hospital, Dhulikhel, Nepal.

E-mail:

razivsharma555@gmail.com

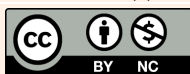Citation:

Sharma R, Basukala B, Parajuli B, Thapa J, Regmi R, Sharma S. Functional and Radiological Outcome after Anatomic Coracoclavicular Ligament Reconstruction for Type III to Type V Acromioclavicular Joint Dislocation Using Semitendinous Autograft. MedS. J. Med. Sci. 2022;2(4):1-6.

ABSTRACT

INTRODUCTION: Acromioclavicular joint dislocation is a commonly encountered shoulder injury. Various surgical methods are available for the treatment of complete ACJ dislocation (type III to VI), however, optimal surgical treatment is still controversial. The purpose of this study was to evaluate the radiological and functional outcome of anatomic coracoclavicular reconstruction (ACCR) using semitendinosus autograft with suture augmentation for type III to V ACJ dislocation. **MATERIALS AND METHODS:** It was a single centered, cross sectional, observational study conducted at Department of Orthopedics and Traumatology, Dhulikhel Hospital. Twenty-three consecutive patients who underwent ACCR with semitendinosus autograft from Jan 2017 to Dec 2019 were included in the study. Patients below 18 years of age and patients with previous ipsilateral shoulder injury were excluded. The radiological outcome was assessed using coracoclavicular (CC) distance and functional outcome using DASH score and Constant score. Paired t-test and Pearson correlation were used for inferential analysis. **RESULTS:** Mean age of the patient was 33.83 ± 7.08 years. Mean duration of follow up was 28.17 ± 6.19 months. Mean CC distance at final follow up was 9.93 ± 1.12 mm. Mean DASH score was 5.60 ± 5.35 and mean Constant score was 88.04 ± 12.13 . There were 12 (52.17%) excellent outcomes, 6 (26.08%) good outcomes, 2 (8.69%) fair outcomes and 3 (13.04%) poor outcomes based on Constant scores. **CONCLUSIONS:** ACCR with suture augmentation is an effective method for management of type III to V acromioclavicular joint dislocation.

Keywords: Acromioclavicular dislocation, Anatomical coracoclavicular ligament reconstruction, Functional outcome.



This is an open access article distributed under the terms of the Creative Commons Attribution License, which permits unrestricted use, distribution, and reproduction in any medium, provided the original author and source are credited.

<https://doi.org/10.3126/mjmms.v2i4.53468>

INTRODUCTION

Acromioclavicular joint (ACJ) dislocations are commonly encountered shoulder injuries. More than 150 techniques are described in the literature for surgical management of AC joint dislocation [1]. Mazzocca et al. described anatomic coracoclavicular ligament reconstruction (ACCR) using semitendinosus allograft which was found to be biomechanically more superior than other techniques [2-5]. This technique involves graft fixation in the bone tunnel using an interference screw [2]. We have been using an alternative method of fixation of the graft by tying the

free ends of the graft together in a knot after the passage of the graft through the clavicle tunnel, and the graft is passed beneath the coracoid. Advantages of this technique include lower cost, less graft injury from the screws and decreased rate of clavicle and coracoid fracture. Very limited study of ACCR without interference screw is found in the literature [6]. The purpose of this study was to evaluate the radiological and functional outcome of ACCR using semitendinosus autograft for ACJ dislocation.

MATERIALS AND METHODS

Study design and setting

This is a single centered, cross sectional observational study conducted at Dhulikhel Hospital in the Department of Orthopaedics and Traumatology from February 2021 to July 2021. Data from the hospital's electronic medical records and physical records were collected for all patients who underwent ACCR for acromioclavicular joint dislocation from January 2017 to December 2019.

Participants and procedure

Patients with acromioclavicular joint dislocation (type III- type V) for <4 weeks who underwent ACCR with semitendinosus autograft were included while patients <18 years and ipsilateral shoulder injury were excluded from the study. Twenty-six consecutive patients with acromioclavicular joint dislocation who underwent ACCR during this 3 years period were reviewed. All patients were contacted by phone and informed about the study and were invited to participate. Three cases could not be contacted. Thus a cohort of 23 patients who fulfilled the criteria was included in the study. All the patients were operated on by the same surgical technique as described below.

Surgical technique:

All patients were operated under general anaesthesia. A rolled sheet was placed beneath the scapula on the involved side and the head end of the operating table was raised 30 degrees to improve access to the clavicle. An incision was made 3 cm medial to the AC joint beginning at the posterior edge of the clavicle and extending toward the coracoid process. Deltotrapezial fascia was dissected using electrocautery and elevated off the clavicle as a full-thickness flap. Distal 5 mm of clavicle was excised using a saw. Reduction was performed by pushing the

elbow upward and clavicle downward. Reduction was maintained by provisional fixation with k-wire. Two bone tunnels were drilled into the clavicle. A 4.7 mm posteromedial tunnel was made 4.5 cm medial to the AC joint along with the insertion of the conoid ligament. Another 4.7mm tunnel was made 2.5 cm medial to the AC joint along with the insertion of the trapezoid ligament. Semitendinosus autograft was harvested by giving 2 cm oblique incision over the pes anserinus.

Sartorial fascia was opened horizontally overlying the semitendinosus and gracilis. Semitendinosus was isolated and the tendon was detached from the bone. The tendon was harvested using a closed tendon stripper. Ends of the graft were secured with whipstitches by using a non-absorbable suture (NO 5 Ethibond). Graft was passed beneath the coracoid from medial to lateral direction using curved vascular clamp. Two ends of the graft were crossed before shuttling into the bone tunnel. A NO 5 Ethibond suture was passed with the graft to provide additional non-biological fixation. Cyclical load of graft was done to remove any slack. Graft was arranged such that shorter limb exited conoid tunnel and longer limb exited trapezoid tunnel.

First, the suture was tied over the clavicle. Then the two limbs of the graft were tied on themselves and were sewn together with non-absorbable suture (NO 2 Ethibond). The AC joint capsule and ligaments were repaired with the figure of eight stitches using absorbable sutures. This repair was supplemented with the long limb of the graft exiting trapezoid tunnel thus recreating superior and posterior AC ligaments. Tight closure of deltotrapezial fascia was done by interrupted stitches.

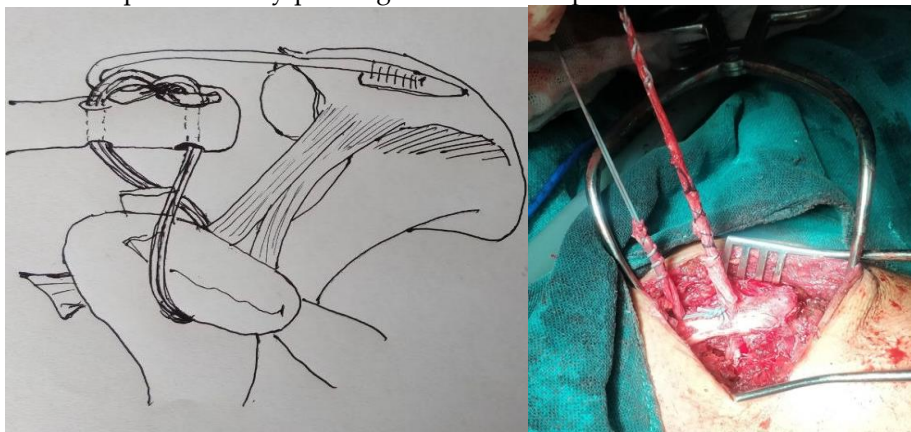


Figure 1 | AC joint reconstruction using a hamstring tendon autograft looped under coracoid and brought up through 2 bone tunnels in the clavicle and tied in a knot over the clavicle augmented with NO 5 Ethibond. The larger limb of the graft exiting the trapezoid tunnel is brought up to the acromion to recreate superior and posterior AC ligament.

Postoperative Rehabilitation:

Shoulder was immobilized in a sling for 4 weeks allowing pendulum and elbow, wrist, and hand range of motion exercise. Then restricted ROM exercise was initiated up to 90 degrees for another 8 weeks. Full range of motion was given only after 3 months.

Follow-up:

Patients were evaluated using x-ray, both true AP view and axillary lateral view of shoulder. Coracoclavicular (CC) distance was calculated in AP view, as the perpendicular distance between the uppermost point of superior cortex of coracoid and undersurface of clavicle and CC difference was calculated by measuring CC distance of normal side. The finding of CC distance on the affected side greater than 25% as compared to the normal side was considered radiological failure [7]. Clinically, patients were evaluated using DASH score and Constant score at final follow up [8,9]. Functional outcome was graded according to Constant score. Constant score difference between the normal side and abnormal side, if less than 11, it was graded as excellent, if 11-20, it was graded as good, if 21-30, it was graded as fair and if more than 30, it was graded as poor.

Statistical analysis and data management

All data were recorded in a Microsoft excel chart. Data analysis was done using the SPSS version 23. Descriptive statistics in the form of mean and standard deviation were used for continuous variables and proportion for categorical variables to characterize the study sample. Paired t-test, Pearson correlation, and Spearman correlation were used for inferential analysis. Statistical significance was set at $p < 0.05$.

Ethical considerations

Ethical clearance was taken from IRC, Dhulikhel Hospital (Reference No: IRC-KUSMS 13/21). Informed consent was taken from all the patients.

RESULTS

Out of total 23 patients, there were 14 males (60.86%) and 9 females (39.13%). The mean age of the patient in this study was 33.83 ± 7.08 years. Mean duration of follow up was 28.17 ± 6.19 months (Range 19 - 42) (Table 1).

The mean pre-operative CC distance was 17.88 ± 3.86 mm. The mean post-operative CC distance decreased to 9.31 ± 0.95 mm which was statistically significant. The mean CC distance at final follow up was 9.93 ± 1.12 mm which was slightly more as compared to immediate post-operative CC distance and was statistically significant. The mean CC difference at final

Table 1| Demographic characteristics of patients (n=23)

| Age in years (Mean \pm SD) | Number (%) |
|---------------------------------|-----------------|
| Gender | |
| Male | 14 (60.86%) |
| Female | 9 (39.13%) |
| Side | |
| Right | 15 (65%) |
| Left | 8 (35%) |
| Mode of injury | |
| RTA | 13 (57%) |
| Fall | 10 (43%) |
| Type of dislocation | |
| Type III | 10 (43%) |
| Type IV | 1 (4%) |
| Type V | 12 (53%) |
| Injury surgery interval | |
| Mean \pm SD | 4.91 ± 2.82 |
| Range | 2-12 days |

Table 2| Comparison of CC distance between pre-operative vs post-operative and post-operative vs final follow up

| Characteristics | CC distance (mm) | p-value |
|-----------------|------------------|---------|
| Pre-operative | 17.88 ± 3.86 | 0.0001 |
| Post-operative | 9.31 ± 0.95 | |
| Post-operative | 9.31 ± 0.95 | 0.0001 |
| Final follow up | 9.93 ± 1.12 | |

follow-up which is the difference between injured and non-injured side was 1.13 ± 0.82 mm (Table 2).

At the final follow up, mean DASH score was 5.60 ± 5.35 and the constant score was 88.04 ± 12.13 . There were 12 (52.17%) excellent outcomes, 6(26.08%) good outcomes, 2(8.69%) fair outcomes, and 3(13.04%) poor outcomes based on constant scores. There was no statistically significant correlation between final CC distance and clinical scores; DASH score ($p = 0.652$), Constant score ($p = 0.897$). Similarly, there was no significant correlation between CC difference and clinical scores; DASH score ($p = 0.255$), Constant score ($p = 0.440$). Also, there was no correlation between the type of dislocation and clinical scores; DASH score ($p = 0.707$), Constant score ($p = 0.665$) (Table 3).

There was more than 25% loss of reduction as compared to normal shoulder in 3 (13.04%) cases suggesting radiological failure. Post-operative wound

complication occurred in 2 cases in the form of superficial infection which eventually healed with regular dressing. Two patients developed adhesive

capsulitis accounting for an overall complication rate of 30.43%. There was no case of clavicular fracture or coracoid fracture.

Table 3 | Correlation of CC distance, CC difference and type of dislocation with clinical scores at final follow up.

| Variables | | DASH score | Constant score |
|---------------------|---------------------|------------|----------------|
| CC distance | Pearson correlation | 0.099 | -0.028 |
| | Sig. (2 tailed) | 0.652 | 0.897 |
| CC difference | Pearson correlation | 0.248 | -0.169 |
| | Sig. (2 tailed) | 0.255 | 0.440 |
| Type of dislocation | rho coefficient | 0.083 | -0.096 |
| | Sig. (2 tailed) | 0.707 | 0.665 |

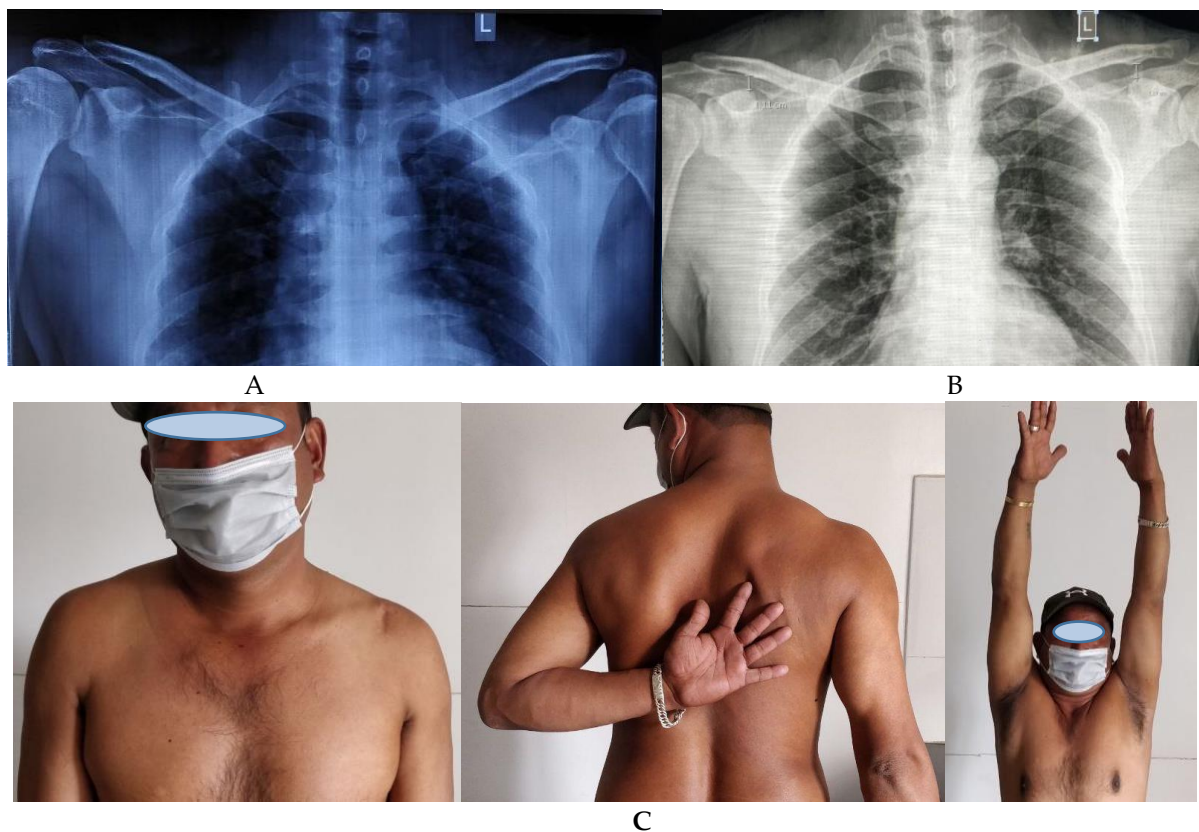


Figure 2 | A. Pre-operative AP radiograph showing type V AC joint dislocation of left side; B. Final follow up (19 months) AP radiograph showing reduced CC distance to normal level as compare to normal side; C. Functional outcome showing loss of clinical step-off on the affected side and full range of motion 19 months following ACCR

DISCUSSION

Many techniques for surgical treatment of AC joint dislocation have been evolved. There have been more than 150 different techniques described in the literature which have evolved. This suggests that there is no consensus regarding optimal management. Various methods of fixation such as trans-articular Kirschner wire, TBW, Bosworth screw, Hook plate were used historically, however, due to complications

like hardware migration, loss of reduction, hardware failure and low functional outcomes, these techniques are rarely used these days. Subsequently, various soft tissue procedures replicating the function of CC and/or AC ligaments were described. The first reported ligament reconstruction procedure was by Weaver and Dunn in 1972 [10]. The non-anatomic reconstruction, Weaver and Dunn, was the most frequently used procedure to treat AC joint dislocation. However, due

to the high rate of re-dislocation and inferior results these procedures have been abandoned nowadays. Mazzocca et al. described anatomic coracoclavicular ligament reconstruction (ACCR) using semitendinosus allograft replicating coracoclavicular ligament in its anatomic location [2]. This technique along with other anatomic reconstruction techniques is biomechanically more superior and has more favourable clinical and radiological outcomes than other non-anatomic techniques like Weaver-Dunn procedure [3-5].

In our study, we used an alternative technique of ACCR using semitendinosus autograft without interference screw and passing the graft beneath the coracoid without drilling hole in the coracoid with additional high strength suture augmentation. Majority of the patient in our study demonstrated good to excellent functional outcomes with few complications as reported in other series using interference screws or without interference screws as reported by Nicholas et al. [11], Tauber et al. [12], Mazzocca et al. [3], and Baran et al. [6]. Hence, there is a biomechanical rationale to support this technique. Tashjian et al. found superior ultimate strength with the square knot technique as compared to grafts fixed with interference screws [13].

In our study, there was a statistically significant increment of CC distance at final follow-up as compared to immediate post-operative CC distance. This may be due to graft stretch over a while. However, radiological failure occurred in only 3 cases (13.04%). This finding is similar to previous studies of ACCR [14]. We did not observe a significant correlation between maintenance of reduction and functional outcome inferred from the side to side difference of coracoclavicular distance at final follow up suggesting anatomic reduction is not required for the functional outcome as reported in other literatures. Bostrom Windhamare suggested that even elongated reconstructed ligament improves the stability of the clavicle sufficient to improve shoulder function [15]. Studies with large sample size and longer duration of follow-up are needed to determine to what extent loss of reduction may impair functional outcomes.

Also, there was no significant correlation between the type of dislocation and functional outcome however, soft tissue disruption is more in type IV and type V injury as compared to type III injury. A similar finding was reported by Tauber et al. [12]. This may be due to the small sample size of our study.

We routinely performed distal clavicle excision (DCE) in all cases as it gives rise to a possible AC joint

arthritis and possible source of pain generation. No case of AC joint arthritis was seen in our study which may be due to routine use of DCE. The literature is divided regarding DCE with some authors favouring DCE and others refuting it [16-18]. A recent biomechanical study showed that resection of distal clavicle lead to increased horizontal translation, therefore, only sparing resection of distal clavicle should be performed only if strictly indicated [19].

Our study has an overall complication rate of 30.43% with 3 cases of significant loss of reduction, 2 cases of superficial surgical site infection and 2 cases of adhesive capsulitis which is similar to other studies of ACCR [20]. There was no case of clavicle or coracoid fracture which has been reported with various ACCR techniques [21]. This may be due to looping the graft beneath the coracoid instead of drilling a hole in the coracoid. Also, fixing the graft in the clavicle bone tunnel using a knot without interference screw may have minimized the risk of clavicular fracture. Baran et al. also used a similar technique of fixation of the graft without interference screw did not report any case of clavicle and coracoid fracture [6]. Dumont et al. demonstrated no difference in clavicle load to failure for 5 mm tunnel with and without 5.5 mm PEEK interference screws in sawbones model [22]. Similarly, Mazzocca et al. did not report any clavicle fractures in their study with the use of interference screw fixation [3]. In our study we used 4.7 mm tunnels in the clavicle and this is at the lower end of the spectrum of tunnel size that has been associated with clavicle fractures according to multiple studies.

Recently there is an increasing trend of arthroscopic tight rope fixation for acute injuries. Biomechanically these techniques have shown to be equivalent to native ligaments. However, there is still concern of button failure as well as suture fatigue resulting in loss of reduction. The long-term result of these techniques in a large cohort is still not available [23].

This was a retrospective study with a small sample size. Three patients were lost to follow-up. All these factors may bias our findings. Various techniques and different outcome measures reported in the literature for AC joint injuries makes it difficult to compare with other studies. Also small sample size limits statistical comparison.

CONCLUSIONS

ACCR with hamstring tendon autograft with suture augmentation is an effective method for management of type III to type V AC joint dislocation with the

majority of patients reporting good to excellent clinical outcomes. Additionally, graft fixation without interference screw employed in this technique may offer a decrease in cost and produce a comparable

clinical result with techniques employing interference screw. However, a larger, prospective, randomized comparative study with long term follow up is required to validate this statement

ADDITIONAL INFORMATION AND DECLARATIONS

Acknowledgements: None.

Competing Interests: The authors declare no competing interests.

Funding: No funding was received for this research.

Author Contributions: Concept and design: R.S., B.B., and BP; Statistical analysis: R.S., B.B.; Writing of the manuscript: R.S., B.B., B.P., J.T., R.R., and S.S.; Data collection: R.S., B.B., and B.P.; Revision

and editing: R.S., B.B., B.P., J.T., R.R., and S.S. All authors have contributed equally for the concept and design, statistical analysis, writing of the manuscript, data collection, revision and editing. All authors have read and agreed with the contents of the final manuscript towards publication.

Data Availability: Data will be available upon request to corresponding authors after valid reason.

REFERENCES

- Beitzel K, Cote MP, Apostolakis J, Solovyova O, Judson CH, Ziegler CG, et al. Current concepts in the treatment of acromioclavicular joint dislocations. *Journal of Arthroscopic and Related Surgery*. 2013;29(1):387-97. [PubMed | Full Text | DOI]
- Carofino BC, Mazzocca AD. The anatomic coracoclavicular ligament reconstruction: Surgical technique and indications. *Journal of Shoulder and Elbow Surgery*. *J Shoulder Elbow Surg*. 2010;19:37-46. [PubMed | Full Text | DOI]
- Mazzocca AD, Santangelo SA, Johnson ST, Rios CG, Dumonski ML, Arciero RA. A biomechanical evaluation of an anatomical coracoclavicular ligament reconstruction. *Am J Sports Med*. 2006;34(2):236-46. [PubMed | Full Text | DOI]
- Costic RS, Labriola JE, Rodosky MW, Debski RE. Biomechanical rationale for development of anatomical reconstructions of coracoclavicular ligaments after complete acromioclavicular joint dislocations. *Am J Sports Med*. 2004;32(8):1929-36. [PubMed | Full Text | DOI]
- Hegazy G, Safwat H, Seddik M, Al-shal EA, El-Sebaey I, Negm M. Modified Weaver-Dunn Procedure Versus The Use of Semitendinosus Autogenous Tendon Graft for Acromioclavicular Joint Reconstruction. *Open Orthop J*. 2016;10(1):166-78. [PubMed | Full Text | DOI]
- Baran S, Belisle JG, Granger EK, Tashjian RZ. Functional and Radiographic Outcomes After Allograft Anatomic Coracoclavicular Ligament Reconstruction. *J Orthop Trauma*. 2018;32(4):204-10. [PubMed | Full Text | DOI]
- Bearden JM, Hughston JC, Whatley GS. Acromioclavicular dislocation: Method of treatment. *Am J Sports Med*. 1973;1(4):5-17. [PubMed | Full Text | DOI]
- Kc S, Sharma S, Ginn K, Almadi T, Subedi H, Reed D. Cross-cultural adaptation and measurement properties of the Nepali version of the DASH (disability of arm, shoulder and hand) in patients with shoulder pain. *Health Qual Life Outcomes*. 2019;17(1). [PubMed | Full Text | DOI]
- Constant CR, Murley AHG. A clinical method of functional assessment of the shoulder. *Clin Orthop Relat Res*. 1987;214(214):160-4. [PubMed | Full Text | DOI]
- Weaver JK, DH. Treatment of acromioclavicular injuries, especially complete acromioclavicular separation. *J Bone Jt Surg Am*. 1972;54:1187-94. [PubMed | Full Text]
- Nicholas SJ, Lee SJ, Mullaney MJ, Tyler TF, McHugh MP. Clinical outcomes of coracoclavicular ligament reconstructions using tendon grafts. *Am J Sports Med*. 2007;35(11):1912-7. [PubMed | Full Text | DOI]
- Tauber M, Gordon K, Koller H, Fox M, Resch H. Semitendinosus tendon graft versus a modified Weaver-Dunn procedure for acromioclavicular joint reconstruction in chronic cases: A prospective comparative study. *Am J Sports Med*. 2009;37(1):181-90. [PubMed | Full Text | DOI]
- Tashjian RZ, Southam JD, Clevenger T, Bachus KN. Biomechanical evaluation of graft fixation techniques for acromioclavicular joint reconstructions using coracoclavicular tendon grafts. *J Shoulder Elb Surg*. 2012;21(11):1573-9. [PubMed | Full Text | DOI]
- Weinstein DM, Mccann PD, Mclveen SJ, Flatow EL, Bigliani LU. Surgical Treatment of Complete Acromioclavicular Dislocations. *Am J Sports Med*. 1995;23(3):324-31. [PubMed | Full Text | DOI]
- Boström Windhamre HA, von Heideken JP, Une-Larsson VE, Ekelund AL. Surgical treatment of chronic acromioclavicular dislocations: A comparative study of Weaver-Dunn augmented with PDS-braid or hook plate. *J Shoulder Elb Surg*. 2010;19(7):1040-8. [PubMed | Full Text | DOI]
- Browne JE, Stanley RF, Tullos HS. Acromioclavicular joint dislocations: Comparative results following operative treatment with and without primary distal clavisectomy. *Am J Sports Med*. 1977;5(6):258-63. [PubMed | Full Text | DOI]
- Park JP, Arnold JA, Coker TP, Harris WD, Becker DA. Treatment of acromioclavicular separations: A retrospective study. *Am J Sports Med*. 1980;8(4):251-6. [PubMed | Full Text | DOI]
- Weinstein DM, Mccann PD, Mclveen SJ, Flatow EL, Bigliani LU. Surgical Treatment of Complete Acromioclavicular Dislocations. *Am J Sports Med*. 1995;23(3):324-31. [PubMed | Full Text | DOI]
- Beitzel K, Sablan N, Chowanec DM, Obopilwe E, Cote MP, Arciero RA, et al. Sequential resection of the distal clavicle and its effects on horizontal acromioclavicular joint translation. *Am J Sports Med*. 2012;40(3):681-5. [PubMed | Full Text | DOI]
- Millett PJ, Horan MP, Warth RJ. Two-Year Outcomes after Primary Anatomic Coracoclavicular Ligament Reconstruction. *Arthrosc - J Arthrosc Relat Surg*. 2015;31(10):1962-73. [PubMed | Full Text | DOI]
- Milewski MD, Tompkins M, Giugale JM, Carson EW, Miller MD, Diduch DR. Complications related to anatomic reconstruction of the coracoclavicular ligaments. *Am J Sports Med*; 2012;40(1):1628-34. [PubMed | Full Text | DOI]
- Dumont GD, Russell RD, Knight JR, Hotchkiss WR, Pierce WA, Wilson PL, Robertson WJ. Impact of tunnels and tenodesis screws on clavicle fracture: a biomechanical study of varying coracoclavicular ligament reconstruction techniques. *Arthroscopy: The Journal of Arthroscopic & Related Surgery*. 2013;29(10):1604-7. [Full Text | DOI]
- Walz L, Salzmann GM, Fabbro T, Eichhorn S, Imhoff AB. The anatomic reconstruction of acromioclavicular joint dislocations using 2 Tight Rope devices: A biomechanical study. *Am J Sports Med*. 2008;36(12):2398-406. [PubMed | Full Text | DOI]

Publisher's Note

MJMMS remains neutral with regard to jurisdictional claims in published materials and institutional affiliations.



CCREACH will help you at every step for the manuscript submitted to MJMMS.

- We accept pre-submission inquiries.
- We provide round the clock customer support
- Convenient online submission
- Plagiarism check
- Rigorous peer review
- Indexed in NepJOL and other indexing services
- Maximum visibility for your research
- Open access

Submit your manuscript at:
Website: www.medsprit.org
e-mail: editormjmms@gmail.com

