

Case Report**"A RARE ENCOUNTER: PNEUMOPAROTID IN CLINICAL PRACTICE" A CASE REPORT****Rajesh Rimal , Umesh Kumar Sharma ,Suraj Thapaliya , Manmohan Bir Shrestha , Jayanti Limbu , Saujan Shrestha**Department of Radiology, B & C Medical College Teaching Hospital and Research Centre , Birtamode , Jhapa , Nepal**Submitted: 20th-April-2024 Revised: 3rd-May-2024 Accepted: 20th-May-2024**DOI: <https://doi.org/10.3126/mjen.v3i01.67451>***ABSTRACT**

Pneumoparotid is a rare condition which is frequently observed in the patients with parotid gland infection or during maneuver leading to increase in intraoral pressure. The common maneuver being performed is puff-cheek technique for diagnostic computed tomography (CT). It is always important to distinguish the etiology of pneumoparotid being pathological or due to maneuver to proceed for further management. Here we present a case of a 56 year old man with suspicion of carcinoma of tongue evaluated by CT using puff cheek technique. On evaluating the images, a finding of bilateral pneumoparotid a case report was made.

Keywords : Computed Tomography (CT), Pneumoparotid

©Authors retain copyright and grant the journal right of first publication. Licensed under Creative Commons Attribution License CC - BY 4.0 which permits others to use, distribute and reproduce in any medium, provided the original work is properly cited.

Corresponding Author**Rajesh Rimal**Email: rajeshrimal16@gmail.comORCID: <https://orcid.org/0000-0003-1080-9842>**Citation**

Rimal R, Sharma U K, Thapaliya S, Shrestha M B, Limbu J, Shrestha S, "a Rare Encounter: Pneumoparotid In Clinical Practice" A Case Report Mjen. 2024 January-June; 1(5):50-52



INTRODUCTION

Pneumoparotid arises from retrograde airflow into Stenson's duct, triggered by elevated intraoral pressure. This phenomenon is normally prevented by the mucosal flap and contraction of buccinator muscle. Any malfunction of these barriers allows air to enter, leading to pneumoparotid.^{1,2}

Several factors contribute to its occurrence: Firstly, heightened intraoral pressure, such as during dental procedures, positive pressure ventilation in anesthesia, or playing wind instruments. Secondly, psychological conditions like nervous ties and adolescent adjustment disorder. Lastly, pneumoparotid can result from imaging procedures for buccal malignancies utilizing the puff cheek technique in CT scans.^{2,4}

In 1865, Hyrtl initially documented this condition among musicians who were in the process of learning to play wind instruments.^{1,3}

CASE REPORT

We report the case of 56 years old male referred to the radiology department of B & C teaching hospital for the evaluation of suspected Carcinoma of tongue. Computed Tomography (CT) with puff cheek technique was being done.

After the CT scan was done the images were evaluated which showed air attenuation foci within the Stenson's ducts of bilateral parotid glands (Fig. 1a,b). The findings were suggestive of pneumoparotid. No other imaging changes were seen in the bilateral parotids to suggest alternate diagnosis.

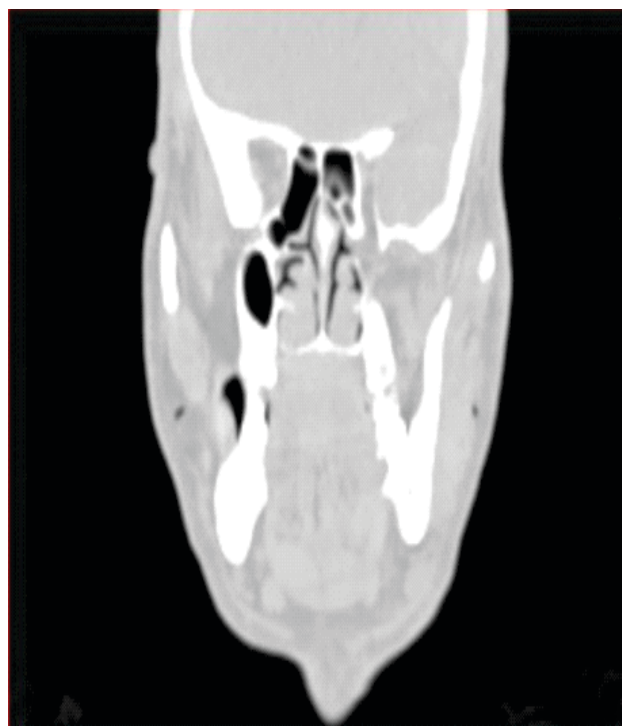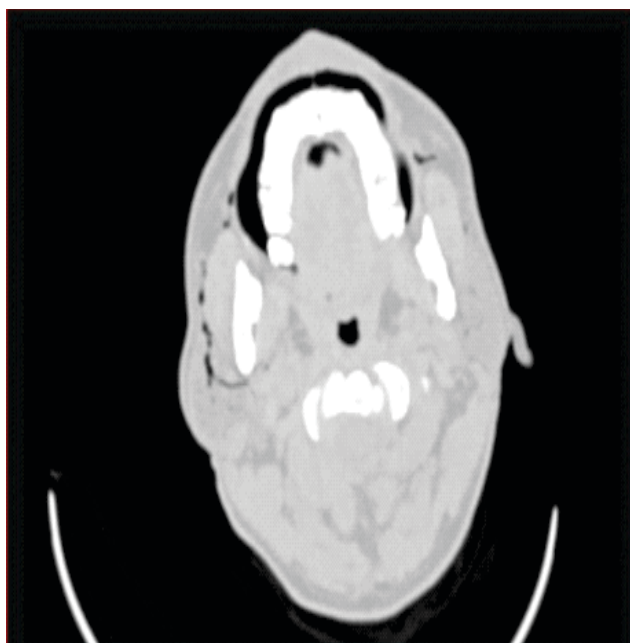


Figure 1a,b : Axial and Coronal CT scan of face and neck : Multiple air foci are seen in bilateral stenson's ducts and parotid glands.

DISCUSSION

Under normal physiological circumstances, the parotid duct and gland are safeguarded against the backflow of air and oral secretions through several anatomical mechanisms. These include the contraction of the buccinator muscle, a duct orifice diameter smaller than that of the duct itself, a slit-shaped duct orifice sealed by mucosal folds during intraoral pressure elevation, and the expansion of the cheek which increases the angle of the duct, both within the oral submucosa and alongside the buccinator and subcutaneous tissue adjacent to the masseter muscle.^{2,4,5}

When intraoral pressure escalates from its typical range of 2–3 mm Hg during regular breathing to as high as 140–150 mm Hg during activities like glass-blowing and playing wind instruments, there's a risk of air being forced into the parotid glands, potentially resulting in pneumoparotid.^{2,3}

Additional triggers for pneumoparotid include dental procedures employing air-powered equipment, coughing in patients with COPD and cystic fibrosis, vigorous nose blowing, balloon inflation, the Valsalva maneuver, positive pressure ventilation, and anatomical irregularities such as a patulous Stensen's duct, hypertrophy of the masseter muscle, and weakness in the

buccinator muscle.^{2,3,6}

Individuals affected by pneumoparotid commonly exhibit painless swelling and tenderness in the parotid region, which can manifest unilaterally or bilaterally. About half of cases demonstrate crepitus over the parotid gland. During gland massage, frothy saliva filled with air may be observed flowing from the parotid duct orifice.^{4,5,6}

To make the diagnosis of pneumoparotid, careful history taking and thorough physical examination are the key factors. CT is the gold standard imaging technique to know its extensions associated other pathologies. However, other imaging modalities like Sialography,

Ultrasonography and Magnetic resonance imaging are also helpful.^{2,5,6,7,8}

Pneumoparotid usually resolves spontaneously. If there is no spontaneous resolution, conservative management can be done to eliminate the precipitating factors. Surgical intervention is done in rare causes.^{3,8}

CONCLUSION

Pneumoparotid, while uncommon, is a thoroughly documented factor contributing to the swelling of the parotid gland. A meticulous approach to history-taking stands as a vital diagnostic tool in this regard.^{5,7,8}

REFERENCES

1. Yoshida K. Etiology of pneumoparotid: a systematic review. *Journal of Clinical Medicine*. 2022 Dec 24;12(1):144.
2. Aljeaid D, Mubarak A, Imarli Y, Alotaibi O. Pneumoparotid: a rare but well-documented cause of parotid gland swelling. *The Egyptian Journal of Otolaryngology*. 2020 Dec;36:1-3.
3. Huang PC, Schuster D, Misko G. Pneumoparotid: a case report and review of its pathogenesis, diagnosis, and management. *Ear, nose & throat journal*. 2000 Apr; 79(4):316-7.
4. Martín-Granizo R, Herrera M, García-González D, Mas A. Pneumoparotid in childhood: report of two cases. *Journal of oral and maxillofacial surgery*. 1999 Dec 1;57(12):1468-71.
5. Greisen O. Pneumatocele glandulae parotis. *The Journal of Laryngology & Otology*. 1968 May;82(5):477-80.
6. Ahuja CK, Yadav MK, Gupta V, Khandelwal N. Incidental pneumoparotid detected on computed tomography: Should it raise an alarm?. *Oral surgery, oral medicine, oral pathology and oral radiology*. 2012 Dec 1;114(6):792-5.
7. Van Gool H, Vermeulen F, Toelen J. Facial swelling caused by pneumoparotid: a case report and review of the literature.
8. Potet J, Arnaud FX, Valbousquet L, Ukkola-Pons E, Donat-Weber G, Thome A, Peroux E, Teriitehau C, Baccialone J. Pneumoparotid, a rare diagnosis to consider when faced with unexplained parotid swelling. *Diagn Interv Imaging*. 2013 Jan 1;94(1):95-7.