

Case Report**DOUBLE OUTLET RIGHT VENTRICLE WITH PENTALOGY PHYSIOLOGY IN ADULT WOMEN: A CASE REPORT***R. Vijaya Lakshmi, *Umesh Yadav, Pritam Gacchhadar, Vasant Kumar, Jay Mandal**Department of Cardiology B & C Medical College Teaching Hospital and Research Center, Birtamode, Jhapa, Nepal**Submitted: 2nd-March-2023, Revised: 10th-May-2023, Accepted: 2nd-June-2023**DOI: <https://doi.org/10.3126/mjen.v2i01.56220>***ABSTRACT**

Double right ventricle outlet (DORV) is a rare cardiac abnormality, especially in adult life. DORV is a rare and complex congenital heart disease that has a high rate of genetic anomalies and extracardiac pathologies. Echocardiography plays an important and cost-effective role in the diagnosis of complex congenital cardiac diseases and assists in surgical planning. Here, we present a case of 38 years old woman who came to our outpatient department with shortness of breath which was progressive during exertion but relief on rest. Clinical examination showed low oxygen saturation of 70% without clubbing of fingers and toes. Holosystolic murmur and diastolic regurgitant murmur were audible along the left Sternal border. Chest X-ray showed cardiomegaly and enlarged pulmonary trunks. Electrocardiography showed right axis deviation and biventricular hypertrophy. After the echocardiogram, it turned out she had DORV. The study emphasizes the role of echocardiography in evaluating DORV.


Keywords: Complex Congenital, Dorv, Pentalogy**INTRODUCTION**

Double outlet right ventricle (DORV) is cyanotic complex congenital heart disease which occurs 1-3% of individuals with congenital heart defects¹. Echocardiography is a preferred method of detecting complex congenital abnormalities in most cases is sufficient for diagnosis and surgical planning. Double outlet right ventricle (DoRV) is a heart disease that is aorta connects to the right ventricle (RV, the chamber of the heart that pumps oxygen-poor blood to the lungs), instead of to the left ventricle (Lv, the chamber that normally pumps oxygen-rich blood to the body)². Both the pulmonary artery (which carries oxygen-poor blood to the lungs) and aorta (which carries oxygen-rich blood from the heart to the body) come from the same pumping chamber. No arteries are connected to the left ventricle (the chamber that normally pumps blood to the body)³.

CASE PRESENTATION

A 38 years old female patient came to our cardiology OPD

at the B & C Medical College Teaching Hospital and Research Center Birtamode, Jhapa on date 22.8.2022 with complaints of shortness of breath in recent time which was progressive in nature during exertion and relief at rest. She was mildly symptomatic earlier and was treated like seasonal asthma and was on Rota inhalers. A routine lab examination was carried out and the results were within normal range. Her ECHO Findings Were: Large Sub-Aortic Vsd With Inlet Extension. (Predominantly Right to Left Shunt), Severe Valvular Ps with 114 Mmhg of Peak Gradient. No RVOTO(right ventricular outflow tract obstruction), more than 50% aortic override, both the great arteries arising from morphological RV only, large Ostium Secundum ASD with left right shunt, dilated RA & RV with adequate biventricular function. Dilated ivc (24mm in size) with reduced inspiratory collapse. Suprasternal view imaging shows large mapcas (Major aortopulmonary collateral arteries). The finding was suggestive of DORV with pentalogy physiology.

	<p>©Authors retain copyright and grant the journal right of first publication. Licensed under Creative Commons Attribution License CC - BY 4.0 which permits others to use, distribute and reproduce in any medium, provided the original work is properly cited.</p>	<p>*Corresponding Author: Umesh Yadav Email: Umy492006@gmail.com, Umy492006@yahoo.com Orchid number: https://orcid.org/0000000182028733</p>
---	---	--

Citation

Lakshmi RV, Yadav U, Gacchhadar P, Kumar V, Mandal J, Double Outlet Right Ventricle with Pentalogy Physiology in Adult Women: A Case Report, MJEN. 2023 June; 2(1):41-43.



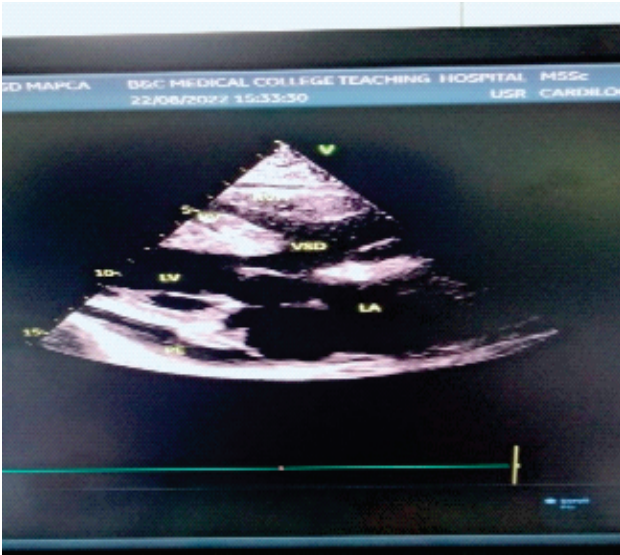


Figure 1: Shows Large VSD, RVH, LVH and Trace PE

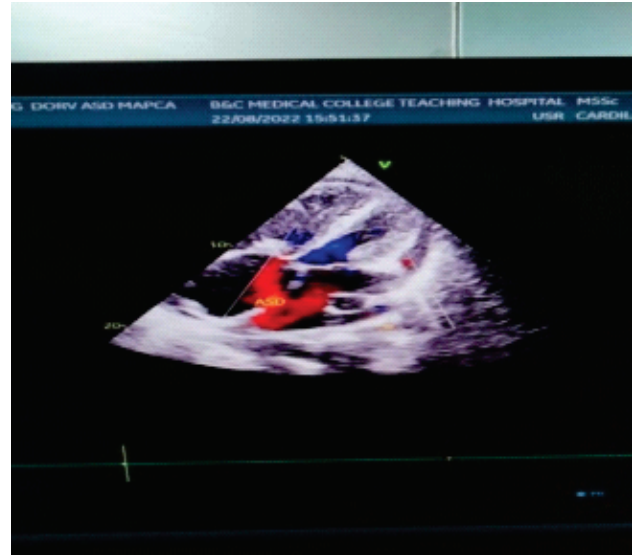

Figure 4: Large ASD with L-R Shunt

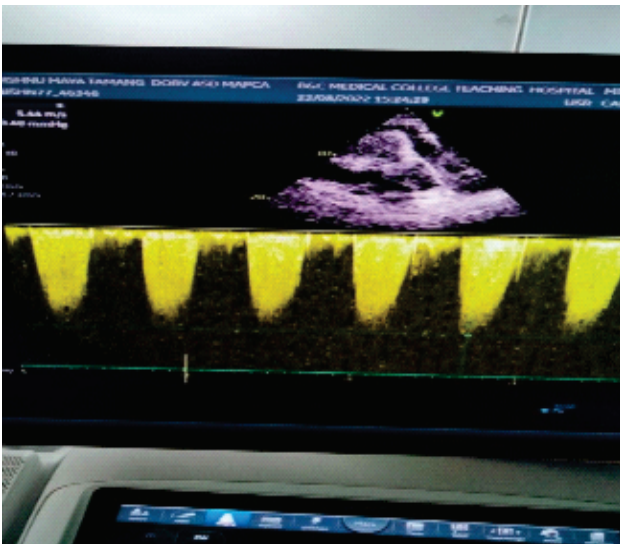


Figure 2: Severe Pulmonary Stenosis With 114, MMHG

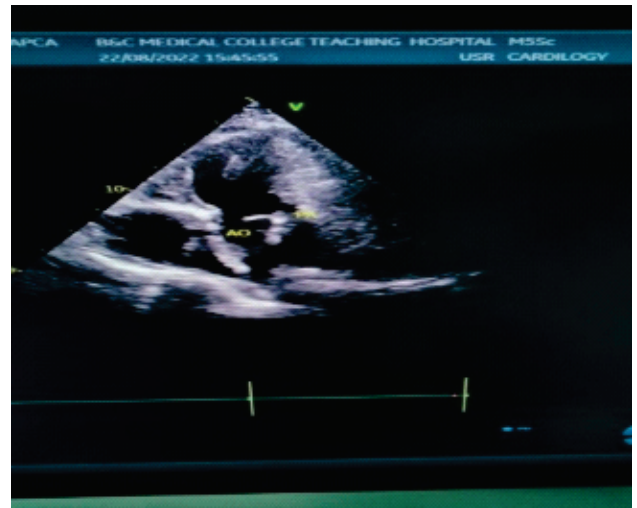

Figure 5: Shows Morphology Aorta Rising From Rv Overriding More Than 50%, Valvular Pulmonary Stenosis

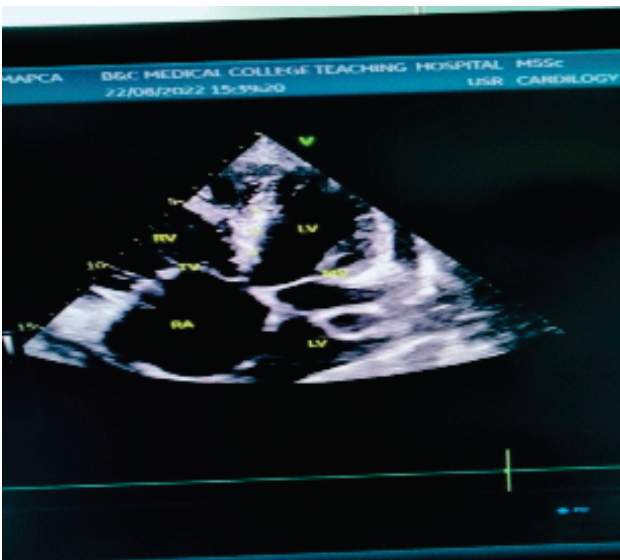

Figure 3: Shows RA and RV Hypertrophy with Large VSD and ASD.

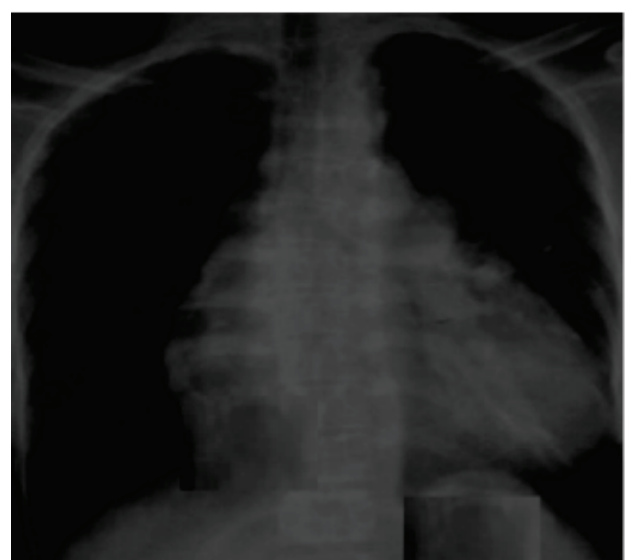

Figure 6: chest x-ray PA view shows cardiomegaly with right broncho pneumonia, without sign of pulmonary congestion

DISCUSSION

Hearts with double outlet right ventricle are a heterogeneous group of malformations involving right ventricular outflow tract (RVOT) in which a comprehensive diagnostic approach is required for surgical management. Based on previous data DORV defines the connection at the ventriculoarterial junction, it does not account for morphology and relationships⁴. Hearts with DORV are an extremely heterogeneous group with a variety of morphological characteristics, connections and relationships at each level of cardiac segments and intersegmental junctions. It can happen as a single condition or in combination with other cardiac or non-cardiac anomalies. It is rare and represents only 1% to 1.5% of all congenital heart disease^{4,5}. Several chromosomal abnormalities such as trisomy 13, trisomy 18, and the deletion of chromosome 22q11 are also associated with DORV⁶. The 2D echocardiogram demonstrates both great vessels arising from the right ventricle and mitral-aortic valve discontinuity^{6,7}. The relationships between the aorta and pulmonary artery and VSD may be defined, and the presence of pulmonary or aortic obstruction may be

evaluated. Cardiac catheterization is not necessarily required if the echocardiogram conforms the diagnosis⁷. She was able to tolerate her pregnancy during the delivery of a low birth weight infant. The echo of her baby boy was done at our B&C hospital, which shows there was no congenital abnormalities, her symptoms which may be due to large ASD with left to right shunt with valvular Pulmonary stenosis & MAPCAS (Major Aortopulmonary Collateral Artery) abnormality. Due to recent time symptoms she was under heart failure medications. If she had echocardiography earlier, she would have operated at a young age, before failure, and managed to lead a good life.

CONCLUSION

DORV is a complex pattern of congenital heart disease which does not have definite treatment yet when it is left or misdiagnosed at a younger age that is better understood by knowing intraventricular anatomy with an echocardiography role and preparing for surgical correction.

REFERENCES

1. Pang KJ, Meng H, Hu SS, Wang H, Hsi D, Hua ZD, et al. Echocardiographic Classification and Surgical Approaches to Double-Outlet Right Ventricle for Great Arteries Arising Almost Exclusively from the Right Ventricle. *Tex Heart Inst J*. 2017 Aug 1;44(4):245-251. <https://doi.org/10.145-03/THIJ-16-5759>
2. John Simpson, Leo Lopez, Philippe Acar, Mark Friedberg, Nee Khoo, Helen Ko, Jan Marek, Gerald Marx, Jackie McGhie, Folkert Meijboom, David Roberson, Annemien Van den Bosch, Owen Miller, Girish Shirali, Three-dimensional echocardiography in congenital heart disease: an expert consensus document from the European Association of Cardiovascular Imaging and the American Society of Echocardiography, *European Heart Journal - Cardiovascular Imaging*, Volume 17, Issue 10, October 2016, Pages 1071-1097, <https://doi.org/10.1093/ehjci/jew172>
3. Goo HW. Double Outlet Right Ventricle: In-Depth Anatomic Review Using Three-Dimensional Cardiac CT Data. *Korean J Radiol*. 2021 Nov;22(11):1894-1908. DOI: 10.3348/kjr.2021.0248. Epub 2021 Sep 13. PMID:3456-4964; PMCID: PMC8546142.
4. Mathew P, Bordoni B. Embryology, heart. 2020. In: StatPearls [Internet]. Treasure Island (FL): StatPearls Publishing. Available from: <https://www.ncbi.nlm.nih.gov/books/NBK537313/>
5. Gu H, Alghamdi AA, van Arsdell GS. Double-outlet right ventricle. In: *Diagnosis and Management of Adult Congenital Heart Disease: Third Edition*. Elsevier Inc.; 2018. p. 553-61. DOI:10.1016/B978-0-7020-6929-1.00054-X.
6. Waldman JD, Wernly JA. Cyanotic congenital heart disease with decreased pulmonary blood flow in children. *Pediatr Clin North Am*. 1999 Apr;46(2):385-404. DOI: 10.1016/s0031-3955(05)70125-5. PMID: 10218082.
7. Robert M. Kliegman MD, in Nelson Textbook of Pediatrics. Cyanotic Congenital Heart Disease : Lesions Associated With Decreased Pulmonary Blood Flow, 2020