

## Case Report

### A RARE CASE REPORT OF URINARY BLADDER PARAGANGLIOMA.

\*Ujwal Rai<sup>1</sup>, Amit Kumar Shah<sup>2</sup>, Umesh Kumar Sharma<sup>3</sup>

<sup>1</sup>Department of Pathology, <sup>2</sup>Department of Urology, <sup>3</sup>Department of Radiology, B&C Medical College Teaching Hospital and Research Center, Birtamode, Jhapa, Nepal

\*Correspondence: Ujwal Rai

Email: [ujwal1235@gmail.com](mailto:ujwal1235@gmail.com)

ORCID: <https://orcid.org/0000-0002-0945-002X>

Submitted: 14-Feb-2022

Revised: 25-Feb-2022

Accept: 03-March-2022

#### ABSTRACT

Paragangliomas are extra-adrenal tumors of the autonomic nervous system which is termed pheochromocytoma in adrenal gland. These tumors are found within the skull base, neck, mediastinum and periaortic region. Paragangliomas of the urinary bladder are rare, and non-functioning bladder paraganglioma is even rarer and not easily recognized. Histopathological examination of the tumor is essential to establish the diagnosis of paraganglioma. This is a case report of 67-year-old male patient presenting with hematuria and passage of blood clots per urethra in emergency department. Cystoscopic examination revealed an exophytic growth in upper posterior wall of his bladder with areas of hemorrhagic blood clots within the vicinity of growth. His blood pressure was found 120/75 mm of Hg with normal serum sodium and potassium levels. Bipolar transurethral resection of the bladder mass was performed. Intraoperative procedure was uneventful and no rise in blood pressure during resection was found. Histopathological examination with immunohistochemistry confirmed diagnosis paraganglioma, urinary bladder. Patient is doing well and is kept on follow up.

**Keywords:** Paraganglioma, Pheochromocytoma, Bladder tumor, non-functional, histopathology.

#### INTRODUCTION

Paraganglioma is extra-adrenal chromaffin cell-related tumor. In adrenal site it is termed as pheochromocytoma. Paragangliomas are rare tumors that arise from extra-adrenal paraganglia consisting of catecholamine-secreting chromaffin cells derived from neural crest cells. Paraganglioma in the urinary bladder is a very rare disease and accounts for only 0.06% of all urinary bladder tumors(1,2).

We report a case of non-functional UBP after transurethral resection of bladder tumor (TUR-Bt) which was found on cystoscopic examination after patient presented with gross hematuria. His blood pressure was normal during presentation and intraoperatively. There is a higher probability of UBP to be misdiagnosed as urothelial carcinoma even in histopathology due to its rarity, invasion of the muscle layer and morphology suggesting urothelial carcinoma and failure of pathologists to include paraganglioma in differential diagnosis(9). Tests for urinary vanillyl mandelic acid should be performed in 24-hour urinary

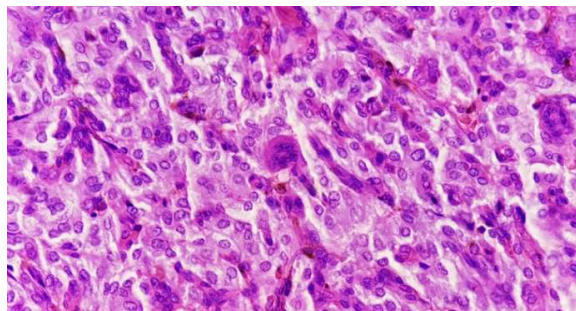
sample whenever paraganglioma is suspected. However, in the absence of characteristic symptoms of catecholamine excess, non-functional UBP is more likely to be misdiagnosed as urothelial carcinoma(10). Thus nonfunctioning paraganglioma is a big diagnostic challenge for clinicians and pathologists.

#### CASE REPORT

A 67-year-old man came in emergency department with complaint of hematuria and passage of blood clots per urethra. His blood pressure was found 120/75 mm of Hg with normal serum sodium and potassium levels. The patient had no complaint of headache and no history of hypertension. Cystoscopic examination revealed a highly vascular tumor protruding on the posterior wall of his bladder along with areas of hemorrhagic blood clots within the vicinity of growth. Bipolar transurethral resection of the bladder tumor was performed with removal of blood clots. Intraoperative procedure was uneventful and no rise in

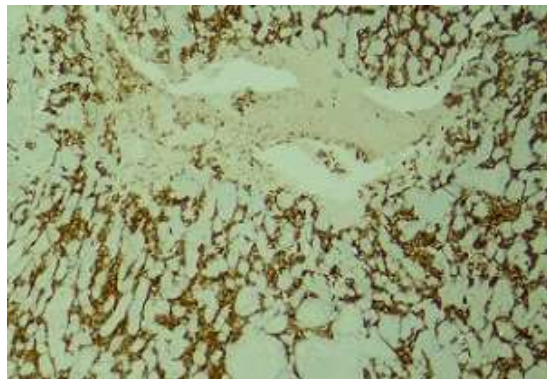
blood pressure during resection was found. The growth was submitted for histopathological evaluation with clinical diagnosis of urothelial carcinoma.

On histopathological examination, H&E sections examined revealed multiple tissue bits lined by transitional epithelium. Subepithelium showed proliferation of tumor cells arranged in nests and lobules surrounded by delicate capillary networks forming Zellballen pattern (Fig. 1).



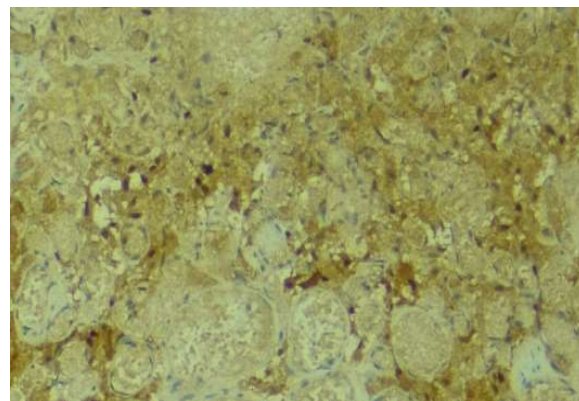
**Fig 1: H&E showing tumor cells in Zellballen pattern surrounded by delicate capillary network.**

These tumor cells were uniform round to polygonal having central round to ovoid nuclei with finely stippled chromatin and inconspicuous nucleoli. Cytoplasm of these cells were finely granular and amphiphilic to eosinophilic. Few cells with clear cytoplasm and multinucleated giant cells were observed. Some cells with elongated hyperchromatic nuclei were seen. These tumor cells were seen infiltrating the underlying muscular layer. Mitosis and necrosis were not seen. With these histological findings possibility of Paraganglioma was made. Serum catecholamine level was performed on 3<sup>rd</sup> post-operative day after histomorphological suspicion of paraganglioma which were found to be within normal limit. Immunohistochemistry was performed which showed positive staining for Synaptophysin (Fig. 2)



**Fig 2: Synaptophysin positive chief cells.**

and chromogranin A confirming chief cells and scattered hyperchromatic sustentacular cells were positive for S100 (Fig. 3).



**Fig 3: S100 positive sustentacular cells**

Uroplakin and GATA3 were negative. Immunohistochemistry findings were compatible with diagnosis of Paraganglioma urinary bladder infiltrating muscular layer.

Post-operative recovery was good and three months follow-up was advised. Written consent was obtained from the patient.

## DISCUSSION

In genitourinary tract, the most common site for paraganglioma is urinary bladder (79.2%), followed by the urethra (12.7%), pelvis (4.9%) and ureter (3.2%)(3,4). Zimmerman et al in 1953 reported the first case of urinary bladder paraganglioma(5). Urinary bladder paraganglioma (UBP) is classified into functional and nonfunctional types based on catecholamine secretion(6). Majority of UBPs are functional type and secrete catecholamines exerting sympathetic actions resulting to paroxysmal hypertension, palpitation, micturitional syncope and headache(7). Non-functional types constitute only 17% of all UBPs and lack symptoms related to catecholamine excess and, therefore, often misdiagnosed as urothelial carcinoma during preoperative evaluation(8,9).

There is high probability of UBPs to be misdiagnosed as urothelial carcinoma even in histopathology due to its rarity, invasion of the muscle layer and morphology suggesting urothelial carcinoma and failure of pathologists to include paraganglioma in differential diagnosis(9). Tests for urinary vanillyl mandelic acid

should be performed in 24-hour urinary sample whenever paraganglioma is suspected. However, in the absence of characteristic symptoms of catecholamine excess, non-functional UBP is more likely to be misdiagnosed as urothelial carcinoma(10). Radiologically there have been reported that MRI and MIBG scintigraphy may be useful for the diagnosis of Paraganglioma with low intensity in MRI-T1-W1 and high intensity in T2-W1, but not in all cases (11). Thus nonfunctioning paraganglioma is a big diagnostic challenge for clinicians and pathologists where biochemical tests and symptoms are not helpful.

## CONCLUSIONS

We report a case of non-functional paraganglioma of urinary bladder, which was incidentally found during

cystoscopic examination following patient's complaint of hematuria and passage of blood clots per urethra. Intraoperatively there was no increase in blood pressure and patient had no symptoms related to catecholamine excess. Transurethral resection of the bladder tumor served therapeutic purpose. Histopathological examination and immunohistochemistry is mandatory in diagnosing nonfunctional paraganglioma and to prevent misdiagnosing this rare tumor for urothelial carcinoma both clinically and histopathologically. Regular three months follow-up by cystoscopy examination is required to rule out recurrence in these patients.

*Funding: None*

*Conflict of interest: None*

*Ethical approval: Ye*

## REFERENCES

1. Ranaweera M. Bladder paraganglioma: A report of case series and critical review of current literature. *World J Clin Cases*. 2014;2(10):591.
2. Iwamoto G, Kawahara T, Tanabe M, Ninomiya S, Takamoto D, Mochizuki T, et al. Paraganglioma in the bladder: a case report. *J Med Case Rep* [Internet]. 2017;11(1):306. Available from: <https://doi.org/10.1186/s13256-017-1473-2>
3. Das S, Lowe P. Malignant pheochromocytoma of the bladder. *J Urol*. 1980;123:282–4.
4. Hanji A, VS R, Patel J, Tankshali R. Pheochromocytoma of the urinary bladder: a rare cause of severe hypertension. *Saudi J Kidney Dis Transpl*. 2012;23(4):813–6.
5. Zimmerman I, Biron R, Macmohan H. Pheochromocytoma of the urinary bladder. *N Engl J Med*. 1953;249:25–6.
6. Heinrich E, Gattenloehner S, Mueller-Hermelink H, Michel M, Schoen G. Paraganglioma of urinary bladder. *Urol J*. 2008;5:57–9.
7. Gupta V, Sharma J, Sangwaiya A, Kaira V, Samal S, Sen R. Nonfunctioning paraganglioma of the urinary bladder: A rare entity. *Clin Cancer Investig J* [Internet]. 2015 Mar 1;4(2):268–70. Available from: <http://www.ccij-online.org/article.asp?issn=2278-0513>
8. Lai Y, Chen D, Yu Z, Ni L, Yang S. *Oncol Lett*. 2014;7:891–3.
9. Zhou M, Epstein J, Young R. Paraganglioma of the urinary bladder: a lesion that may be misdiagnosed as urothelial carcinoma in transurethral resection specimens. *Am J Surg Pathol*. 2004;28:94–100.
10. Katiyar R, Dwivedi S, Trivedi S, Patne SCU, Dwivedi US. Non-functional paraganglioma of the urinary bladder treated by transurethral resection: Report of two cases. *J Clin Diagnostic Res*. 2016;10(2):XD01–3.
11. Wong-You-Cheong JJ, Woodward PJ, Manning MA, Sesterhenn IA. From the Archives of the AFIP: neoplasms of the urinary bladder: radiologicpathologic correlation. *Radiographics*. 2006;26(2):553–80.