

## CASE REPORT

## INTRAPLEURAL STREPTOKINASE IN MANAGEMENT OF MULTILOCULATED PLEURAL EFFUSION AS A COMPLICATION OF FREQUENT RELAPSE NEPHROTIC SYNDROME - A CASE REPORT

Manoj Kumar Gupta,<sup>1\*</sup> Md. Ashfaque Ansari,<sup>1</sup> Sijan Kharel,<sup>1</sup> Priyanka Shrestha,<sup>1</sup> Roshan Maharjan,<sup>1</sup> Anjana KC<sup>2</sup><sup>1</sup> Department of Pediatrics and Adolescent Medicine, National Medical College and Teaching Hospital, Birgunj, Parsa, Nepal.<sup>2</sup> Department of Pathology, National Medical College and Teaching Hospital, Birgunj, Parsa, Nepal.**Date of Submission** : Apr 14, 2023**Date of Acceptance** : July 14, 2023**Date of Publication** : July 28, 2023**\*Correspondence to:**

Manoj Kumar Gupta, Department of Pediatrics and Adolescent Medicine, National Medical College and Teaching Hospital, Birgunj, Parsa, Nepal.

Phone:+977-9864043162

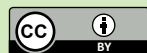
Email: manuu126@gmail.com

**Citation:**

Gupta MK, Ansari MA, Kharel S, Shrestha P, Maharjan R, KC A. Intrapleural Streptokinase in Management of Multiloculated Pleural Effusion as a Complication of Frequent Relapse Nephrotic Syndrome - A Case Report. Medphoenix. 2023;8(1):89-91

**DOI:** <https://doi.org/10.3126/medphoenix.v8i1.53871>**Conflict of interest:** None, **Funding:** None**Publisher:** National Medical College Pvt. Ltd.**MedPhoenix - Journal of National Medical College (JNMC); 2023,8(1), available at [www.jnmc.com.np](http://www.jnmc.com.np)**

ISSN:2631-1992 (Online); ISSN:2392-425X (Print)



This work is licensed under a Creative Commons Attribution 4.0 International License.

**ABSTRACT**

Treatment of pleural effusion with intrapleural administration of fibrinolytic drugs has proven to be efficient and secure. Patients with pleural effusion who receive streptokinase instillations in conjunction with chest tube draining avoid surgery and have better outcomes. Its application in multiloculated pleural effusion, which develops as a nephrotic syndrome consequence, has only occasionally been documented. We describe a case of multiloculated pleural effusion that did not react to conventional chest tube drainage but resolved completely and dramatically in response to intrapleural streptokinase.

**Keywords:** Chest Tube Drainage, Pleural effusion, Streptokinase**INTRODUCTION**

The morbidity and death from pulmonary infections with subsequent pleural involvement are significant.<sup>1</sup> A simple exudative parapneumonic effusion can quickly develop into a multiloculated purulent empyema due to bacterial and white cell metabolism. Changes in fibrin turnover are involved in this gradual process, which causes fibrinous deposits and membranes to develop and sequester infected fluid.<sup>2</sup>

Systemic antibiotics and pleural cavity draining, accomplished either surgically or with a medical chest tube, make up the accepted course of treatment. The optimal drainage in cases of substantial empyema or loculated effusions is achieved by open thoracotomy or videoassisted thoracoscopic surgery (VATS), although these procedures are constrained by surgical risk, cost, and local accessibility.<sup>3</sup> Fibrinolytic medicines can be safely and effectively administered intrapleurally for the treatment of hemothorax, pleural empyema, and

multiloculated parapneumonic effusion.<sup>4</sup>

**CASE SUMMARY**

A 10 yrs old male, known case of frequent relapse of Nephrotic Syndrome came with the complaints of fever and cough for 5 days. There was no history of dyspnea, chest pain, nausea and vomiting and other systemic symptoms. On physical examination patient had pallor and tachypneic. Examination revealed decreased air entry on left side.

X-Ray chest PA view reveals massive left sided pleural effusion without mediastinal shift. Pleural aspiration tried, 300ml of fluid could be aspirated with difficulty. Ultrasonography (USG) and High-Resolution Computed Tomography (HRCT) of the chest at this stage revealed

multiloculated pleural effusion on left side. [Figure 1]

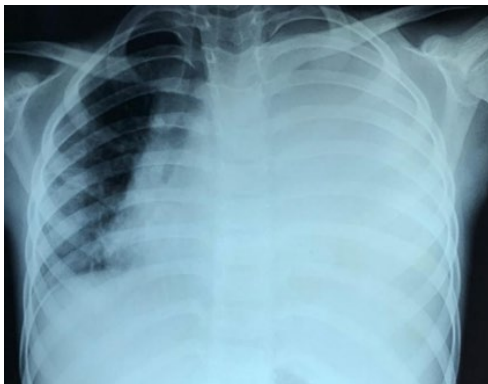


Figure 1: Skigram chest showing opaque left hemithorax without mediastinal shift

USG guided aspiration could aspirate 100ml of fluid. Pleural fluid was exudative with lymphocytic predominance. (Protein 1.2gm/dl, Glucose 100 mg/dl, Cell count: 1020 cells/Cumm, DLC- lymphocyte 80%, polymorphs- 20%). Smear microscopy did not reveal any pathological organisms including Acid Fast Bacilli (AFB). Pleural fluid was negative of malignant cells. In view of multiloculated pleural effusion fibrinolytic therapy was planned, as there was no contraindication to such therapy. Streptokinase 15000 units/kg (Total 3,00,000 units) in 50ml normal saline was instilled into pleural space through chest tube. Position of patient was changed frequently to allow even distribution of the drug in the pleural space. Clamp was removed after one hour and drainage was subsequently collected and measured to be 300ml, 25ml and 25ml every day for next 3 days. The same dose of streptokinase was repeated after 72 hours. This time the drainage was 335ml, 75ml, 75ml and 45 ml every day for next 4 days. Serial chest x-ray and ultrasound chest were done to evaluate the treatment response. The adjunctive fibrinolytic treatment resulted in complete resolution of empyema in 10 days post pigtail insertion (Figure 2).

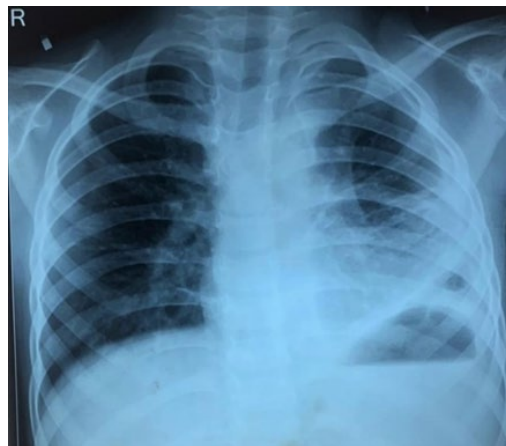

Figure 2: Skigram chest showing resolution after streptokinase treatment

His symptoms resolved and patient was discharged on antibiotics and steroid for nephrotic syndrome. X-ray chest PA view shows marked improvement [Figure 2]. A repeat USG of pleural space revealed resolution. Patient became asymptomatic and discharged after 10 days

## DISCUSSION

Tillent & Sherry used an intrapleural fibrinolytic substance for the first time in 1949. It is regarded as a workable substitute to help with lung expansion and drainage when a chest tube is insufficient to address a pleural effusion.<sup>5</sup> Numerous studies revealed that using intrapleural streptokinase as soon as 3–4 weeks after the start of the illness, before the pleural fluid is completely organized, made the condition of multiloculated pleural effusion more manageable. Streptokinase injections are safer, but a very small percentage of cases of hypersensitivity and hemorrhages have been reported<sup>6</sup>. However, there are few reports of this strategy being used to treat multiloculated pleural effusion occurring as a complication of frequent relapse nephrotic syndrome. Nissar Khan et al. discovered a success rate of over 86% in a study, involving 15 patients. Almost all studies done used a dose of streptokinase of 2,50,000 units but ours was however 3,00,000 units and the saline instillation volume was between 50 and 100 cc. Additionally, tube closure times ranged from 30 minutes to 6 hours. It worked well to seal the tube for 60 minutes. In our instance, the treatment lasted 7 days, but a study found that it could take up to 6 days to complete the treatment.<sup>7</sup>

## CONCLUSION

To improve the draining of fluid that is too viscous or loculated to be drained by tube thoracotomy alone, intrapleural streptokinase should be used early in the drainage of loculated pleural effusion. In patients with pleural effusion, intrapleural streptokinase is therefore an adjunct to chest tube drainage, which lowers the need for surgery and increases the clinical therapy success.

## REFERENCES

1. Davies W, Kearney S, Gleeson F, Davies R. Predictors of outcome and long-term survival in patients with pleural infection. *Am J Respir CritCare Med.* 2003;160:1682-6.
2. Strange C, Allen ML, Harley R, Lazarchick J, Sahn SA. Intrapleural streptokinase in experimental empyema. *Am Rev Respir Dis.* 1993;147:962-6.
3. Sahn SA. Management of complicated parapneumonic effusions. *Am Rev Respir Dis.* 1993;148:813-81.
4. Kemper P, Kohler D. Current value of intrapleural fibrinolysis in the treatment of exudative fibrinous pleural effusions, pleural empyema and hemothorax. *Pneumologie.* 1999; 53:373-84.
5. Dixit R, Dixit K, Bansal R. Intrapleural Streptokinase in multiloculated malignant pleural effusion. *Indian J Chest Dis Allied Sci.* 2004; 46:59-62.
6. Lim TK, Chin NK. Streptokinase for empyema. *The Lancet.* 1997; 350:1491-2.
7. SH Talib, GR verma, M Arshad, BO Tayade. Utility of intrapleural Streptokinase in management of chronic empyema. *JAPI.* 2003;52:464-8.