

## FUNCTIONAL AND RADIOLOGICAL OUTCOMES WITH INTRAMEDULLARY INTERLOCKING NAILING OF TIBIAL SHAFT FRACTURE

Mukesh Prasad Kushwaha,<sup>1\*</sup> Vandana Mourya<sup>2</sup>

<sup>1</sup> Department of Orthopedics, National Medical College and Teaching Hospital, Birgunj, Parsa, Nepal.

<sup>2</sup> Department of Radiology, National Medical College and Teaching Hospital, Birgunj, Parsa, Nepal

**Date of Submission** : July 20, 2022

**Date of Acceptance** : Aug 15, 2022

**Date of Publication** : Aug 19, 2022

**\*Correspondence to:**

Mukesh Prasad Kushwaha, Department of Orthopedics, National Medical College and Teaching Hospital, Birgunj, Parsa, Nepal.

Email: mouryavandana@gmail.com

Phone: +977 9841799861

**Citation:**

Khushwaha MP, Mourya V. Functional and radiological outcome with intramedullary interlocking nailing of tibial shaft fracture. Medphoenix. 2022;7(1):83-87.

**DOI:** [10.3126/medphoenix.v7i1.47176](https://doi.org/10.3126/medphoenix.v7i1.47176)

**Conflict of interest:** None, **Funding:** None

**Publisher:** National Medical College Pvt. Ltd.  
**MedPhoenix - Journal of National Medical College (JNMC); 2022,7(1), available at [www.jnmc.com.np](http://www.jnmc.com.np)**

ISSN:2631-1992 (Online); ISSN:2392-425X (Print)



This work is licensed under a Creative Commons Attribution 4.0 International License.



### ABSTRACT

**Introduction:** Tibia is the most common long bone involved in fracture during Road Traffic Accident (RTA) because of its subcutaneous location. Intramedullary nail fixation remains the treatment of choice for unstable and displaced tibial shaft fractures in the adult. The goals of surgical treatment are to achieve osseous union and to restore length, alignment, and rotation of the fractured tibia. Intramedullary nailing carries the advantage of minimal surgical dissection with appropriate preservation of blood supply to the fracture site.

**Materials and Methods:** This is a prospective observational study conducted in the Department of Orthopedics, National Medical College and Teaching Hospital, Birgunj, Parsa, Nepal for the 1 year duration. Patients included in this study were above 16 years with Tibia shaft fracture with or without fibula fracture which includes Type I, II and IIIA of Gustilo-Anderson fracture. Patients with tibia shaft fracture were treated surgically by using intramedullary interlocking nail then follow up done in OPD at regular intervals during which radiographs was taken in appropriate views and diagnosis is established by functional and radiological means.

**Result:** Out of 53 patients, 45 patients with Tibia shaft fracture are treated by closed intramedullary interlocking nailing in the National Medical College, Birgunj. Eight patients are lost during follow-up. In our study tibia shaft Fracture was more common in male (77.8%) than female which mostly involved 18-30 years of age group (62.2%) and most common cause was Road Traffic Accident (82.2%). Thirty cases (66.7%) had excellent and 10 cases (22.2%) had good healing and complication were seen in eight patients (17.7%).

**Conclusion:** Closed interlocking tibia nailing allows earlier fracture union with less morbidity. Because of the high union rate and low infection rate, we consider closed interlocking nailing as the best mode of treatment for diaphyseal tibial fractures.

**Keywords:** Fracture, Functional and radiological outcome, Intramedullary nailing, Tibial shaft.

### INTRODUCTION

Tibia is the most common long bone involved fracture in Road Traffic Accident (RTA) because of its subcutaneous location. It occurs in approximately two tibial shaft fracture per 1000 individuals per year.<sup>1</sup>

Tibial shaft fracture is caused by high energy trauma

and it commonly occurs in young adults due to RTA and it is also associated with other injuries. Fracture can be closed or open. Close fracture is more common than open fracture. Trivial injury gradually do well with nonsurgical management and severe injury require

surgical management.<sup>2</sup>

Tibial shaft fracture is classified according to the AO classification system of long bone fracture. Fracture was placed in nine main groups, each with three subgroups according to location in the proximal, middle or distal segment of the shaft. Group A includes all simple fracture, and group B include fracture with butterfly fragments and cortical contact between the main proximal and distal fragments. In Group C there is no such contact. For all degree of comminution, Group 1 includes the spiral fractures and Group 2 & 3 are the non-spiral bending fractures. Group C2 contains segmental and Group C3 includes crush and high velocity projectile fracture.<sup>3</sup>

Gustilo and Anderson categorized open injuries into the familiar three categories, based on wound size, level of contamination, and osseous injury, as follows:<sup>4</sup>

Type I = an open fracture with a wound less than 1 cm long and clean

Type II = an open fracture with a laceration greater than 1cm long without extensive soft tissue damage, flaps, or avulsions

Type III = either an open segmental fracture, an open fracture with extensive soft tissue damage, or a traumatic amputation

Special categories in Type III were gunshot injuries, any open fracture caused by a farm injury, and any open fracture with accompanying vascular injury requiring repair.

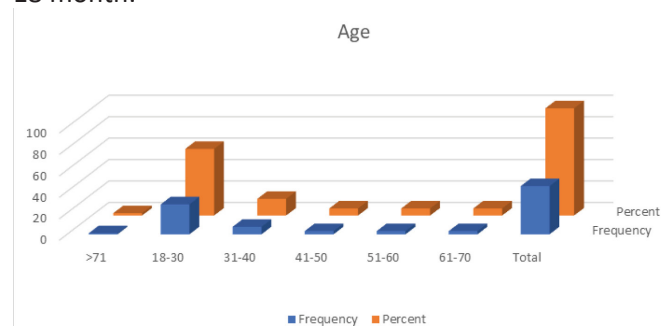
Intramedullary nail fixation remains the treatment of choice for unstable and displaced tibial shaft fractures in the adult. The goals of surgical treatment are to achieve osseous union and to restore length, alignment, and rotation of the fractured tibia. Intramedullary nailing carries the advantage of minimal surgical dissection with appropriate preservation of blood supply to the fracture site.<sup>5</sup> The rationale for operating on closed tibial fractures of moderate and major severity is to prevent disability and morbidity associated with these injuries. However, studies on management of tibial shaft fracture not done in this region of Nepal so we conducted.

## MATERIAL AND METHODS

This is a prospective observational study conducted in the Department of Orthopedics, National Medical College and Teaching Hospital, Birgunj, Parsa, Nepal for the 1 year duration from 1st December 2020 to 30th January 2022. Patients included in this study were above 16 years with Tibia shaft fracture with or without fibula fracture which includes Type I, II and IIIA of Gustilo-Anderson fracture. With ethical clearance from the Institutional Review Committee of National Medical College and after obtaining the informed consent of the patient study was conducted. Patients with tibia shaft fracture were treated surgically by using intramedullary interlocking nail then follow up done in OPD at regular intervals at 8 weeks, 16 weeks and 24 weeks and 1-year during which radiographs was taken in appropriate views and diagnosis is established by functional and radiological means. Functional outcome was assessed by Olerud and Molander scores. Radiographic assessment was done by using radiographic union score for tibia (RUST). The RUST is based on callus formation and visibility of fracture line at 4 cortices observed on AP and lateral radiographs. Data processing and analysis done by using SPSS version 23 and statistical tests applied are Count, Percentage, Mean, Median and Standard Deviation. Findings were presented as tables, bar diagrams and pie-charts.

## RESULT

Out of 53 patients 45 patients were included in this study because we lost 8 patients during follow up. All 45 patients with Tibial shaft fracture were treated by closed intramedullary interlocking nailing in the National Medical College, Birgunj, Parsa was studied from December 2020 to January 2022. All the patients are followed up for 16-18 month.



**Figure 1: Incidence of Tibial shaft fracture according to the age group**

**Table 1: Table showing the mode of injury causing tibial shaft fracture**

Mode	Frequency	Percent
Assault	2	4.4
Fall	6	13.3
RTA	37	82.2
Total	45	100.0

Figure 1 and Table 1 shows most common age group of the tibial shaft fracture which includes 18-30 years with most common mode of injury is RTA that includes 37 patients with 82.2 % of total case of this study.

**Table 2: Frequency of site of tibial shaft fracture**

	Frequency	Percent
Lower	30	66.7
Middle	9	20.0
Upper	6	13.3
Total	45	100.0

Table 2 shows the most frequent site of tibial shaft fracture is lower third in 30 patients with 66.7 % of total case.

**Table 3: Gustilo-Anderson classification of fracture**

Type	Frequency	Percent
I	22	48.9
II	14	31.1
IIIA	9	20.0
Total	45	100.0

**Table 4: Functional vs Radiological healing at 16 weeks**

RUST-1		Radiological Outcome			Total
		RUST-2	RUST-3		
Functional Outcome	EXCELLENT	0	2	28	30
	FAIR	0	3	0	3
	GOOD	0	2	8	10
	POOR	2	0	0	2
Total		2	7	36	45

Table 4 shows both functional and radiological excellent fracture healing in 30 patients (66.7%) at 16 weeks of duration of intramedullary interlocking nailing.

**Table 5: Complications**

	Frequency	Percent
Anterior knee pain	1	2.2
Infection	1	2.2
Pain & Discomfort	4	8.9
Restricted ankle movement	2	4.4
No complication	37	82.2
Total	45	100.0

Table 5 shows very few complications seen in the tibial shaft fracture cases treated by Intramedullary Interlocking nailing, among which most common is pain and discomfort seen in 8.9% cases. In most of cases healing occur without any complications.

## DISCUSSION

Tibia is the most common long bone vulnerable to fracture due to its superficial anatomical location. Fractures of tibia shaft are increasing due to high velocity trauma and industrialization. The management of tibial shaft fractures has always held a particular interest for orthopedic surgeons. Not only are they relatively common but they are often difficult to treat. Until recently surgeons had to rely on non-operative treatment, 'V nailing, "plates and screws" and external fixators but these had their own drawbacks like prolonged immobilization, infection, delayed union, non-union, malunion and cumbersome for patients. With the introduction of reamed intramedullary interlocking nail for tibial shaft fractures has overcome some of these complications and encourages the patient for early mobilization. As fracture hematoma is not disturbed, healing of the fracture is good and the rate of infection is reduced. Due to minimal exposure and minimal soft tissue handling, the rate of infection is reduced. This study has been done to evaluate the result of reamed intramedullary interlocking nail for tibial shaft fracture in Gustilo-Anderson fracture I, II and IIIA.<sup>6</sup>

Current available tools in assessment of fracture healing can be broadly divided into four categories: (1) imaging studies, (2) mechanical assessment, (3) serologic markers, and (4) clinical examination. We used Imaging study and clinical examination to assess the fracture healing in our study. Radiographic assessment has remained a crucial tool in determining fracture healing. This stems from clinicians' familiarity with plain radiography and their widespread availability and accessibility. Bhandari et al. showed in an international survey of 444 orthopedic surgeons in 2002 that 39.7% to 45.8% of surgeons always used radiographic data, including callus size, cortical continuity, and progressive loss of fracture line in assessment of tibial fracture healing.<sup>7</sup>

Despite developments of advanced imaging techniques

to quantitatively and qualitatively assess bone health and fracture healing, plain radiography remains the most commonly used radiographic tool for this purpose. This is due to lower cost, wider availability, and lower radiation exposure of plain radiography compared to other available modalities.<sup>8</sup> In our study tibia shaft Fracture is more common in the male (77.8%) than female which involves 18-30 years age group (62.2%) and most common cause is Road traffic accident (82.2%). Lower third part (66.7%) of right side tibia (66.7%) is more commonly involved in injury.

D Joshi et al in there study founded the average age of 30 years.<sup>9</sup> Chauhan N et al. reported 36.2 years.<sup>10</sup> In our study most common age group of tibial shaft fracture was 18-30 years.

According to Grade of fracture, Jain V et al reported grade 1 fracture in majority of the cases followed by grade 2 and grade 3A.<sup>11</sup>

Larsen et al studied 45 patients with reamed interlock nail in whom average time to fracture healing was 16.7 weeks and had two malunion.<sup>12</sup>

Vidyadharn et al studied the clinico-radiological outcome of interlock nail in tibia in which he found that the average time of fracture healing was 20.1 weeks while in our study it was 16 weeks. He also pointed out that meticulous intramedullary nailing for tibial diaphyseal fracture has excellent clinico-radiological out come and is relatively safe.<sup>13</sup> Chauhan et al reported average radiological union time 20.13 weeks.<sup>10</sup> In our study average healing time was 16 weeks with no malunion.

Kumar et al reported in there study excellent in 75%, good in 14.28% healing<sup>14</sup> and Agarwal A et al reported 18 cases (60%) as excellent outcomes, seven cases (23.4%) as good results.<sup>15</sup> In our study, 30 cases (66.7%) were of excellent outcome and 10 cases (22.2%) were having good healing.

Bonnevialle et al studied intramedullary nailing with reaming (Grosse-kempf nail) in 32 patients in whom only one case (3.12%) developed deep infection while in our study there was only one infection (2.2%).<sup>16</sup>

Steinber and his colleagues studied 54 cases with diaphyseal fracture. They pointed out 11 (20.4%) complications related to the nailing. 3 (5.55%) deep infection, 2 (3.7%) superficial infection, 2 bone shortening of 1 centimeter secondary to nail protrusion in the knee, 1 compartment syndrome, 1 fracture propagation, 1 distal malalignment and 1 delayed union.<sup>17</sup> In Our study total complication seen in 8 patients which included 1(2.2%) anterior knee pain, Deep infection in 1 ( 2.2%) patient, Pain & Discomfort in 4 ( 8.9%) and Restricted ankle movement in 2 ( 4.4%) patients.

## CONCLUSION

In our study we investigated the outcomes of closed interlocking tibia nail in 45 patients with tibia diaphyseal fractures which were followed up for 4 months of time period. The fractures in our study united in an average of about 16 weeks. This onetime procedure of interlocked intramedullary nailing done using image intensifier which lead to union in almost all the cases. This procedure allows earlier fracture union with less morbidity. Because of the high union rate and low infection rate, we consider closed interlocking nailing as the best mode of treatment for diaphyseal tibial fractures.

## REFERENCES

1. Baral, R., J. Khan, and G.J.J.o.U.C.o.M.S. Singh, Pattern of tibial shaft fractures in Universal College of Medical Sciences, Bhairahawa: A review of sixty cases. 2013. 1(3): p. 11-14. [DOI]
2. Kurapati, R.B., et al., Management of fracture shaft of tibia with intramedullary interlocking nail—a clinical study. 2012. 22(22): p. 1-4. [Full Text]
3. Johner, R., O.J.C.o. Wruhs, and r. research, Classification of tibial shaft fractures and correlation with results after rigid internal fixation. 1983(178): p. 7-25. [DOI]
4. Kumar, G. and B. Narayan, Prevention of infection in the treatment of one thousand and twenty-five open fractures of long bones. Retrospective and prospective analyses, in Classic Papers in Orthopaedics. 2014, Springer. p. 527-530. [DOI]

5. Fisher, J.S., et al., Radiologic evaluation of fracture healing. *Skeletal radiology*, 2019. 48(3): p. 349-361. [[DOI](#)]
6. Whittle, A. and I.J.C.s.o.o. Wood, GW. Fractures of lower extremity. 2003. 3: p. 2725-872.
7. Bhandari, M., et al., A lack of consensus in the assessment of fracture healing among orthopaedic surgeons. 2002. 16(8): p. 562-566. [[DOI](#)]
8. Hammer, R., et al., Accuracy of radiologic assessment of tibial shaft fracture union in humans. 1985(199): p. 233-238. [[DOI](#)]
9. Joshi, D., et al., Unreamed interlocking nailing in open fractures of tibia. 2004. 12(2): p. 216-221. [[DOI](#)]
10. Chauhan, N., et al., Interlocking nail in diaphyseal fracture of tibia: A clinical study. 2016. 3(6): p. 1678-1681. [[Full Text](#)]
11. Jain, V., et al., Primary unreamed intramedullary locked nailing in open fractures of tibia. 2005. 39(1): p. 30. [[Full Text](#)]
12. Larsen, L.B., et al., Should Insertion of Intramedullary Nails for Tibial Fractures Be With or Without Reaming?: A Prospective, Randomized Study With 3.8 Years' Follow-up. 2004. 18(3): p. 144-149. [[DOI](#)]
13. Vidyadhara, S. and S.K.J.I. Rao, Prospective study of the clinico-radiological outcome of interlocked nailing in proximal third tibial shaft fractures. 2006. 37(6): p. 536-542. [[DOI](#)]
14. Kumar A. et al. To study outcome of intramedullary nailing in grade I and II (Gustilo-Anderson) compound diaphyseal fractures of Tibia. 2016. 3(8): p. 2473-2476. [[Full Text](#)]
15. Agrawal, A., et al., Primary Nailing in the Open Fractures of the Tibia-Is it worth? 2013. 7(6): p. 1125. [[DOI](#)]
16. Bonnevalle, P., et al., Segmental tibia fractures: a critical retrospective analysis of 49 cases. 2003. 89(5): p. 423-432. [[PubMed](#)]
17. Steinberg, E.L., et al., Intramedullary fixation of tibial shaft fractures using an expandable nail: early results of 54 acute tibial shaft fractures. 2006. 20(5): p. 303-309. [[DOI](#)]