

## OUTCOMES OF ENDOSCOPIC MYRINGOPLASTY

Ram Kumar Pradhan,<sup>1\*</sup> Md. Kamaluddin Rain,<sup>1</sup> Inclub Dhungana,<sup>1</sup> Suman Raut<sup>1</sup><sup>1</sup> Department of ENT, National Medical College and Teaching Hospital, Birgunj, Parsa, Nepal

**Date of Submission** : Jun 27, 2022  
**Date of Acceptance** : Aug 10, 2022  
**Date of Publication** : Aug 19, 2022

**\*Correspondence to:**

Ram Kumar Pradhan, Department of ENT, National Medical College and Teaching Hospital, Birgunj, Parsa, Nepal.  
 Phone No : +977 9861573458  
 Email : www.rampradhan123@gmail.com

**Citation:**

Pradhan RK, Rain MK, Dhungana I, Raut S. Outcomes of endoscopic myringoplasty. Medphoenix. 2022;7(1):77-82.

**DOI:** [10.3126/medphoenix.v7i1.47016](https://doi.org/10.3126/medphoenix.v7i1.47016)

**Conflict of interest:** None, **Funding:** None

**Publisher:** National Medical College Pvt. Ltd.  
 MedPhoenix - Journal of National Medical College (JNMC); 2022,7(1), available at [www.jnmc.com.np](http://www.jnmc.com.np)

ISSN:2631-1992 (Online); ISSN:2392-425X (Print)



This work is licensed under a Creative Commons Attribution 4.0 International License.

**ABSTRACT**

**Introduction:** The endoscope has diagnostic and therapeutic role in different otological surgeries. It has excellent view of images where there are difficult nooks and corners. The use of tragal cartilage in the repair of tympanic membrane perforation has its own benefit in graft uptake and hearing results whether long term or short term. The main purpose of the present study was to evaluate the long-term hearing results in patients who underwent endoscopic sandwich myringoplasty with National Medical college & Teaching Hospital, Birgunj.

**Objective:** To evaluate the graft success rate and postoperative hearing gain for central perforations using endoscopic myringoplasty

**Materials and Methods:** This study is a prospective study in 60 patients with central perforations who underwent endoscopic myringoplasty using tragal cartilage. The hearing was assessed by comparing pre . with post-operative air-bone gap (ABG) and ABG closure in speech frequencies (0.5 kHz, 1 kHz, 2 kHz, and 4 KHz).

**Result:** Of the 60 patients with central perforation included in this study, the graft success rate was 95% (57/60). The graft uptake in 6 months of follow-up. The postoperative ABG ( $13.77 \pm 4.94$ dB) was lesser than preoperative ABG ( $22.38 \pm 6.93$  dB) with statistically significant results.

**Conclusion:** Endoscopic myringoplasty is a safe procedure with high-graft uptake rate and good long-term hearing results.

**Keywords:** Air-bone gap; Endoscopic myringoplasty; Tragal cartilage.

**INTRODUCTION**

Chronic otitis media is defined as a stage of ear disease characterized by chronic infection of middle ear cleft with non-intact tympanic membrane and discharge for at least a period of preceding two weeks.<sup>1</sup> It is one of the most common problems encountered by an otologist in his practice.<sup>2</sup> Though this condition doesn't seem to be common in developed countries with prevalence of less than 2%,<sup>3</sup> but is still a common condition encountered in under developed country like that of ours where prevalence reported is as 7.2%.<sup>4</sup> Factors contributing to high prevalence are overcrowding, poor personal hygiene, poor health, decreased immunity, low education

and limited access to healthcare facilities.<sup>5</sup>

COM is the condition which leads to permanent changes in tympanic membrane and in other middle ear structures.<sup>2</sup> Clinically, it is an inflammatory condition associated with broad and persistent tympanic membrane perforation and otorrhea. Whereas histologically, it has been characterized as an inflammatory process with irreversible tissue alteration.<sup>6</sup> The introduction of endoscope in other area of medical field also finds its role in ear surgery. Endoscopes have better optics and magnification with wide angle of view due to angled lenses and provide the excellent resolution of image. This advantageous

factor increases its role in surgeries having many difficult anatomic nooks and corners.<sup>9</sup> The diagnostic and teaching role of endoscope in otological practice has already been proved. Apart from that, there are lots of other advantages of endoscope in otological surgeries like; it can visualize antero-inferior recess of external auditory canal, middle ear cavity and sinus tympani.<sup>10,11</sup> Various graft materials are skin, vein, perichondrium, temporalis fascia, dura and cartilage.<sup>7,8</sup> Treatment of patients with myringoplasty generally improves the disease, hearing status and prevents complications.

The main aim of our study is to see the graft uptake rate and hearing results after endoscopic cartilage myringoplasty with our own modification.

## MATERIALS AND METHODS

This is cross-sectional study, conducted from 27<sup>th</sup> April 2021 to 27<sup>th</sup> October 2021. The ethical clearance was obtained from institutional Review Board. Informed consent obtained from the patient before conducting the study. There was a total of 60 patients in the 8–55-year age group suffering from the safe type of chronic suppurative otitis media. The inclusion criteria were a dry or no discharging ear for at least three weeks, with a central perforation, and both genders. Exclusion criteria were as follows: graft failure, revision cases, mentally retarded, medical or surgical conditions, or treatment having a chance to influence the outcome. From the patients included in the study, data collection was done preoperatively and then 6 months postoperatively. Clinical examinations (general ear, nose, and throat [ENT] examination, microscopic examination of the ear, and tuning fork tests) also performed preoperatively.

All the selected patients were operated on using the endoscopic myringoplasty technique. Pre- and postoperative pure tone audiometry was performed. The air bone gap of each patient was calculated at the frequencies of 500 Hz, 1,000 Hz and 2,000 Hz, 4000 Hz both pre- and postoperatively, and the average of the three was taken as the average air-bone gap as the three frequencies fall in the speech range. The audiological results were reported according to the American Academy of Otolaryngology-Head-and-Neck Surgery guidelines.<sup>8</sup>

For The Surgery:

Patient Preoperative preparation:

The patient was given oral ciprofloxacin 500 mg 12 hourly from 1 day before surgery and continued till the 7th postoperative day. Since the surgery was performed under local anesthesia, the patient was sedated with pethidine and promethazine intramuscularly as per body weight.

Surgical procedure

The patient was given 5–10 ml of 2% Xylocaine with 1:200,000 adrenalin as per the approach selected for four-quadrant canal wall block and on the tragus. The rigid Hopkins II endoscope (Karl Storz) 0° and 30° with 4-mm diameter and 18 cm in length was passed through the trans canal route to observe and assess the perforation, ossicular chain status, middle ear mucosa, and also the eustachian tube orifice (Figure 2). The margin of perforation was refreshed with the straight needle. When the handle of the malleus was visible, it was well skeletonized (Figure 3). The size of the graft was measured with a round knife. For harvesting the graft, about 2 cm vertical incision was given by number 15 scalpel from the incisura terminalis up to the intratragal notch which was around 5 mm medial to the tip of the tragus. The single stroke skin incision was given up to the tragus cartilage. The assistant held the tissue of the tip of the tragus by non-tooth forceps and cleared the surgical field from blood by suction. Whereas the operating surgeon held the skin with non-tooth forceps, and then, the canal side cartilage along with the perichondrium was dissected with tympanoplasty scissor taking precaution of not penetrating the canal skin. Similarly, cartilage along with the perichondrium from the anterior aspect of tragal cartilage was dissected and made free at the incisura terminalis (Figure 4). The cartilage along with the perichondrium was excised with number 15 scalpel giving incision from the incisura terminalis. The skin was closed with 3/0 prolene interrupted suture. The graft was then kept on the silastic block (figure 5). The attached muscle fiber was cleaned from the cartilage graft. The cartilage graft was then placed around the perforated tympanic membrane by first inserting on the anterior

end of perforation by mounting on the crocodile forceps. Then, the rest of the cartilage was placed in the middle ear with a straight needle(Figure6). The canal was then packed with wet gelatin sponge soaked in ciprofloxacin ear drops and followed by the ribbon pack medicated Myosporin ointment was kept in the canal, and the bandage was applied.

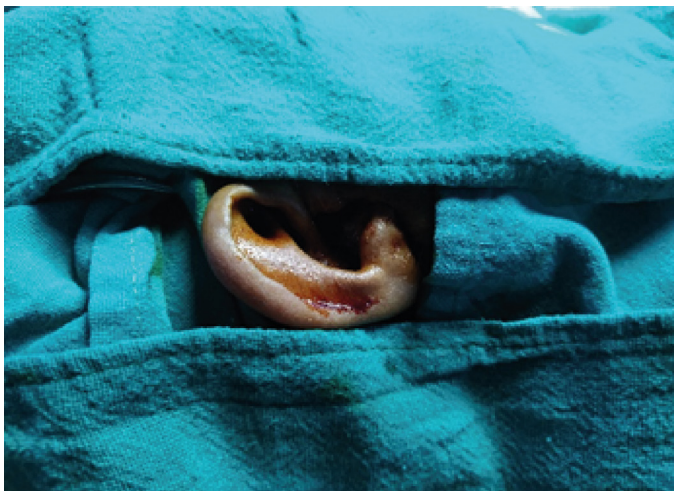

Figure:1 (cleaning and Draping)

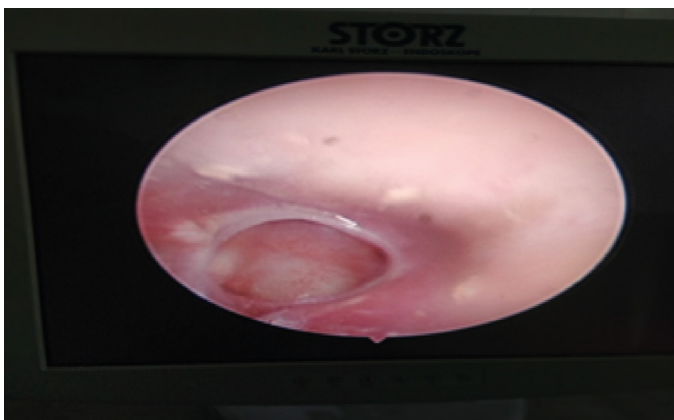


Figure:2(Endoscopic Visualization of TM Perforation)

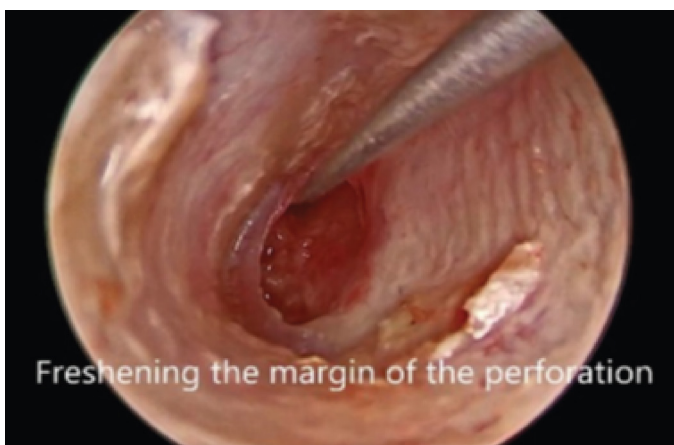


Figure:3(Freshening of Perforated Margin)

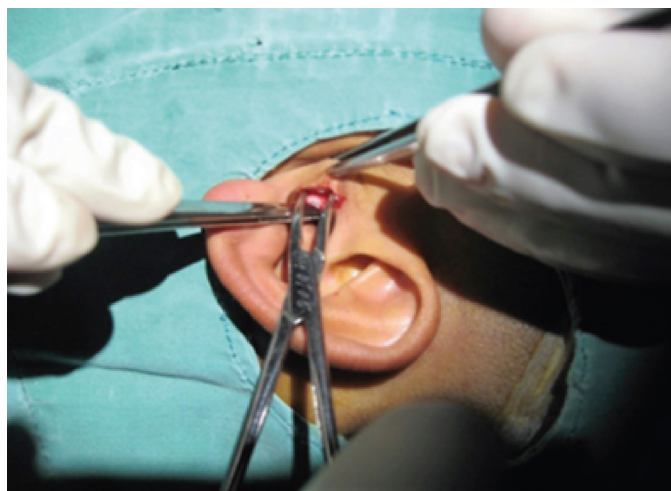

Figure:4(Tragal cartilage harvesting)



Figure:5(Graft kept on Silastic block)

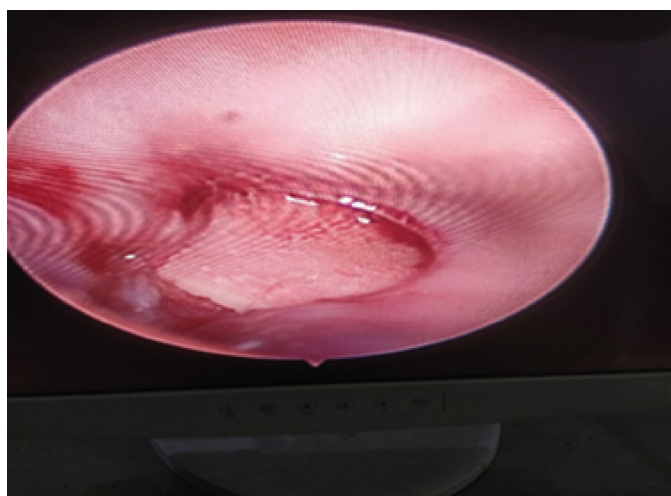


Figure:6(Graft placed in middle Ear)

#### Postoperative care and follow-up

The patient was prescribed tablet ciprofloxacin 500 mg 12 hourly for 7 days. The ribbon gauge pack and the stitch were removed on the 7th postoperative day. The



remaining gelatin sponge was also suctioned on the 7th postoperative day. Then, the patient was prescribed chloramphenicol and dexamethasone ear drops for 6 weeks. The patient was again followed up after 6 weeks and 6 months. The hearing results and graft uptake rate noted on 6 months of follow-up.

## RESULTS

There was a total of 65 patients with 60 ears enrolled in the study. Among them, three cases had perforated tympanic membrane because of infection, and hence, only 60 patients were included in the study. The graft uptake rate was 95% in a 6 month follow-up period. We had not found any cholesteatoma or myringitis of graft during the follow-up period. Regarding the age distribution, it ranges from 8 to 60 years with  $25.87 \pm 10.86$  years. Regarding the gender distribution, 42 were

female and 18 were male with a male-to-female ratio of 2.3:1. Comparison of pre-and post-operative ABG is shown in Table 1, with a statistically significant improvement in the postoperative period. As for the laterality, in 31 (51.7 %) patients the operation was performed on the right side, and in 29 (48.3%) patients the operation was performed on the left side. Most of the patients were undergoing surgery for the 1st time. All of the cases were undergone total endoscopic approach.

Audiometrically, an improvement in the pure tone average (PTA) hearing thresholds were observed from the preoperative to the postoperative period (Table 2 and 3). The preoperative air conduction threshold (ACT) and the airborne gap (ABG) closure were  $42.12 \pm 7.96$  and  $22.38 \pm 6.93$  respectively. Postoperatively, the ACT and the ABG closure were  $31.24 \pm 6.07$  and  $13.77 \pm 4.94$ , respectively. This difference was statistically significant ( $p < 0.001$ ). A total of 53.3% of the cases had a preoperative ABG level of between 11 and 20 dB, and the postoperative ABG had a maximum of 60 %, which fell < between 11 and 20 dB.

## DISCUSSION

The present study focuses on the surgical outcome u audiological improvement after endoscopic Myringoplasty using tragal cartilage.

The use of an endoscope for treating ear diseases has been dated since the 1960s. The procedure proved to be a possible alternative to myringoplasty under microscopic visualization, considering the surgical results and the proportion of audiometric improvement at six months of follow-up. The 1st reported case of endoscopic myringoplasty was by el-Guindy in 1992.<sup>12</sup> There are now numerous studies published on endoscopic ear surgery with graft uptake rate comparable to microscopic ear surgery. Although there are different methods of performing myringoplasty (either microscopic or endoscopic), the endoscope provides good visualization of the anterior end of perforation and 360° view of perforated tympanic membrane as compared to the microscope, and hence the graft can be easily placed using endoscope in our D-HOS technique.<sup>13,14</sup> The main disadvantages with the use of endoscope are; one hand technique, absence of stereoscopic view, potential risk of mechanical and thermal trauma, and along with that the learning curve is also an important factor as seen in Sino nasal and skull base surgery.<sup>14-18</sup>

Regarding the hearing outcome after myringoplasty, the study showed that it depends largely on the incorporation of the graft to the tympanic membrane, the integrity of the ossicular chain, absence of any residual perforation and also the absence of graft medialization or lateralization. Hence, it is irrespective of either endoscopic or microscopic method.<sup>13</sup> We have used the tragal cartilage graft, as the clinical and experimental study showed that the cartilage is well tolerated with minimal resorption time and survives for a long period with good hearing outcome.<sup>19-23</sup>

In our study, we had a graft uptake rate of 95 %. There was a statistically significant improvement in hearing outcome, with ABG improvement of  $13.77 \pm 4.94$ . Almost 54% of the patients had a preoperative ABG ranging between 11 and 20 dB, which resulted in the closure of the ABG (11–20 dB) in 60% of the patients after the surgery.

Several studies reported hearing improvement n ABG gap after surgery. Özgür et al. reported that mean air-bone gain was 9.4 dB on postoperative 6th month for an adult group who had endoscopic butterfly inlay

myringoplasty.<sup>24</sup> Karabulut et al. showed that the mean preoperative ABG was  $24.2 \pm 3.8$  dB, the mean ABG on the 12th postoperative month was  $17.1 \pm 3.5$  dB, and the mean ABG on the 24th postoperative month was  $12.4 \pm 3.1$  dB.<sup>25</sup> Shrestha et al showed uptake rate 93.3%. In this study the mean preoperative ABG was  $27.3 \pm 12.5$  dB, the mean postoperative ABG on the 12th month follow-up was  $17.1 \pm 8.5$  dB with statistically significant results.<sup>26</sup> Shakya et al reported success rate 97.6%. In this study the preoperative air conduction threshold (ACT) and air bone gap (ABG) was  $43.34 \pm 11.53$  and  $24.73 \pm 7.89$ , respectively. Postoperatively, the ACT and ABG closure were  $28.73 \pm 15.75$  and  $11.91 \pm 8.41$ , respectively.<sup>27</sup> Chih-Chiechet al reported 93% success rate. The mean (SD) preoperative and postoperative air-bone gaps were 15.9 (9.4) and 5.4 (7.0) dB, respectively, revealing a significant mean (SD) improvement of 10.3 (7.6) dB.<sup>28</sup>

## CONCLUSION

Endoscopic myringoplasty is a safe and feasible procedure. The endoscopic approach for myringoplasty offers excellent visualization, avoids the post aural approach, enables a faster recovery, and requires a shorter hospital stay, with excellent graft closure rate and improved functional outcome. Being of a low set-up cost, of easy portability and handling, endoscopic surgery holds promising results to be applied in developing countries like ours.

**Table 1. Distribution of the participants**

Parameters	Participants (n=60)
Age in years (Mean±SD)	25.87±10.86
Sex	
Male	18 (30.0%)
Female	42 (70.0%)
Site	
Left	29 (48.3%)
Right	31(51.7%)
Graft uptake	
Success	57 (95%)
Failure	3 (5%)

**Table 2. Air bone gap range**

Air bone gap	Preoperative hearing n=60 (%)	Postoperative hearing n=60 (%)
0-10	0	17 (28.3%)

11-20	32 (53.3%)	36 (60.0%)
21-30	18 (30.0%)	7 (11.7%)
31-40	10 (16.7%)	0

**Table 3. Preoperative and postoperative hearing outcomes**

Parameters	Mean (±SD)	P value
Preoperative ACT	42.12 (±7.96)	<0.001
Postoperative ACT	31.24 (±6.07)	
Preoperative BCT	17.95 (±3.63)	<0.001
Postoperative BCT	16.15 (±2.83)	
Preoperative ABG	22.38 (±6.93)	<0.001
Postoperative ABG	13.77 (±4.94)	

## REFERENCES

1. World Health Organization. WHO/PDH/98.4 <http://www.who.int/pbd/pdh/docs/COMREP-8A.pdf>, 1998.
2. Cabra J, Moñux A. Efficacy of cartilage palisade tympanoplasty: randomized controlled trial. *Otol Neurotol*. 2010 Jun;31(4):589-95. [DOI]
3. Shrivastav RP. Infections of tympanic membrane and middle ear cleft. An illustrated textbook Ear, Nose and Throat and Head and Neck Surgery, 1<sup>st</sup> edition. WPS Pulchowk, Nepal : 2008; p.36.
4. Little P, Bridges A, Guragain R, Friedman D, Prasad R, Weir N. Hearing impairment and ear pathology in Nepal. *J Laryngol Otol*. 1993 May;107(5):395-400. [DOI]
5. Chole RA, Sudhoff HH. Chronic otitis media, mastoiditis and petrositis. *Cumming's Otolaryngology Head and Neck Surgery*, 4<sup>th</sup> edition. United States, Mosby; 2005: 2997-9. [DOI]
6. Fukuchi I, Cerchiari DP, Garcia E, Rezende CE, Rapoport PB. Tympanoplasty: surgical results and a comparison of the factors that may interfere in their success. *Braz J Otorhinolaryngol*. 2006 Mar-Apr;72(2):267-71. [DOI]
7. Berthold E. Uber Myringoplastik. *Med-chir centralbl*. 1879; 14:195- 207.
8. Adkins WY. Composite autograft for tympanoplasty

- and tympanomastoid surgery. *Laryngoscope*. 1990 Mar;100(3):244-7. [DOI]
9. Mattox DE. Endoscopy-assisted surgery of the petrous apex. *Otolaryngol Head Neck Surg*. 2004 Feb;130(2):229-41. [DOI]
10. Patil RN. Endoscopic tympanoplasty - Definitely advantageous (preliminary reports). *Asian J Ear Nose Throat* 2003;25:9-13.
11. Khan I, Jan AM, Shahzad F. Middle-ear reconstruction: a review of 150 cases. *J Laryngol Otol*. 2002 Jun;116(6):435-9. [DOI]
12. El-Guindy A. Endoscopic transcanal myringoplasty. *J Laryngol Otol*. 1992 Jun;106(6):493-5. [DOI]
13. Lade H, Choudhary SR, Vashishth A. Endoscopic vs microscopic myringoplasty: a different perspective. *Eur Arch Otorhinolaryngol*. 2014 Jul;271(7):1897-902. [DOI]
14. Marchioni D, Molteni G, Presutti L. Endoscopic anatomy of the middle ear. *Indian J Otolaryngol Head Neck Surg*. 2011 Apr;63(2):101-13. [DOI]
15. Pollak N, Azadarmaki R, Ahmad S. Feasibility of endoscopic treatment of middle ear myoclonus: a cadaveric study. *ISRN Otolaryngol*. 2014 Mar 10;2014:175268. [DOI]
16. Karchier EB, Niemczyk K, Orłowski A. Comparison of visualization of the middle ear by microscope and endoscopes of 30° and 45° through posterior tympanotomy. *Wideochir Inne Tech Maloinwazyjne*. 2014 Jun;9(2):276-81. [DOI]
17. Tarabichi M. Endoscopic transcanal middle ear surgery. *Indian J Otolaryngol Head Neck Surg*. 2010 Jan;62(1):6-24. [DOI]
18. Smith SJ, Eralil G, Woon K, Sama A, Dow G, Robertson I. Light at the end of the tunnel: the learning curve associated with endoscopic transsphenoidal skull base surgery. *Skull Base*. 2010 Mar;20(2):69-74. [DOI]
19. Dornhoffer JL. Hearing results with cartilage tympanoplasty. *Laryngoscope*. 1997 Aug;107(8):1094-9. [DOI]
20. Zahnert T, Hüttenbrink KB, Mürbe D, Bornitz M. Experimental investigations of the use of cartilage in tympanic membrane reconstruction. *Am J Otol*. 2000 May;21(3):322-8. [DOI]
21. Kerr AG, Byrne JE, Smyth GD. Cartilage homografts in the middle ear: a long-term histological study. *J Laryngol Otol*. 1973 Dec;87(12):1193-9. [DOI]
22. Gerber MJ, Mason JC, Lambert PR. Hearing results after primary cartilage tympanoplasty. *Laryngoscope*. 2000 Dec;110(12):1994-9. [DOI]
23. Kirazli T, Bilgen C, Midilli R, Ogüt F. Hearing results after primary cartilage tympanoplasty with island technique. *Otolaryngol Head Neck Surg*. 2005 Jun;132(6):933-7. [DOI]
24. Özgür A, Dursun E, Terzi S, Erdivanlı ÖÇ, Coşkun ZÖ, Oğurlu M, Demirci M. Endoscopic butterfly cartilage myringoplasty. *Acta Otolaryngol*. 2016;136(2):144-8. [DOI]
25. Karabulut B, Mutlu F, Sahin S, Cirik AA. Anatomical and functional long-term results of endoscopic butterfly inlay myringoplasty. *Eur Arch Otorhinolaryngol*. 2018 Nov;275(11):2653-2658. [DOI]
26. Shrestha BL, Dhakal A, Kiran KC, Shrestha KS, Pradhan A. Long-term hearing results in endoscopic sandwich myringoplasty: An innovative Dhulikhel hospital technique. *Indian J Otol* 2019;25:135-40. [DOI]
27. Shakya D, Kc A, Nepal A, Tamang N. Total Endoscopic Transcanal Cartilage Myringoplasty: A Prospective Study. *Int Arch Otorhinolaryngol*. 2019 Oct;23(4):e440-e444. [DOI]
28. Tseng CC, Lai MT, Wu CC, Yuan SP, Ding YF. Endoscopic Transcanal Myringoplasty for Anterior Perforations of the Tympanic Membrane. *JAMA Otolaryngol Head Neck Surg*. 2016 Nov 1;142(11):1088-1093. [DOI]