

## CASE REPORT

## PLEOMORPHIC ADENOMA OF THE UPPER LIP: A CASE REPORT

Anjana KC<sup>1</sup>, Brijesh Shrestha<sup>2</sup>, Vikash Paudel<sup>3</sup><sup>1</sup> Resident, Department of Pathology, National Medical College, Birgunj<sup>2</sup> Lecturer, Department of Pathology, National Medical College, Birgunj<sup>3</sup> Associate Professor, Department of Dermatology, National Medical College, Birgunj**Date of Submission** : Dec 07, 2021**Date of Acceptance** : Jan 10, 2022**Date of Publication** : Feb 15, 2022**\*Correspondence to:**Dr. Brijesh Shrestha, Department of Pathology,  
National Medical College, Brigunj-15, Nepal.

Email: bshrestha121@gmail.com,

Phone: +977-9845448809

**ORCID ID:** 0000-0001-5389-7286**Citation:**KC A, Shrestha B, Paudel V. Pleomorphic Adenoma  
of the Upper Lip: A case report. Medphoenix.  
2021;6(2):73-75**DOI:** 10.3126/medphoenix.v6i2.42667**Conflict of interest:** None, **Funding:** None**Publisher:** National Medical College Pvt. Ltd.  
**MedPhoenix - Journal of National Medical College  
(JNMC); 2021,6(2), available at www.jnmc.com.np**

ISSN:2631-1992 (Online); ISSN:2392-425X (Print)

This work is licensed under a Creative  
Commons Attribution 4.0 International  
License.**ABSTRACT**

*Pleomorphic adenoma is the most common benign tumour of the major salivary gland presenting as a painless mass gradually increasing in size, usually involving the parotid gland. In the minor salivary gland, it is more common in the palate. Pleomorphic adenoma of the lip is a rare tumour. Thus, we present a case of pleomorphic adenoma originating from the upper lip in a 75 years old male patient. The tumor was completely excised and sent for histopathological examination which showed the microscopic features of pleomorphic adenoma to confirm the diagnosis.*

**Keywords:** minor salivary gland; parotid; pleomorphic adenoma; upper lip**INTRODUCTION**

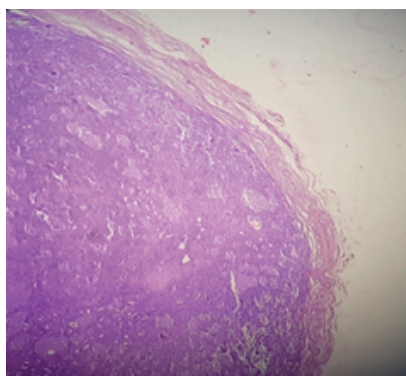
Most common salivary gland tumour is the pleomorphic adenoma accounting for two-thirds, or approximately 60-65% of all salivary gland tumours and 40-70% of all minor salivary gland tumours.<sup>1, 2</sup> Minor salivary gland tumours are uncommon, and the most common intraoral tumour site is the hard and soft palate followed by the lips.<sup>3</sup> Histologically, it is characterized by a wide variety of tissues consisting of epithelial cells arranged in cord-like cell pattern with areas of squamous differentiation or with plasmacytoid appearance myoepithelial cells which are responsible for production of abundant extracellular matrix with chondroid, collagenous, mucoid and osseous stroma.<sup>5</sup>

**CASE REPORT**

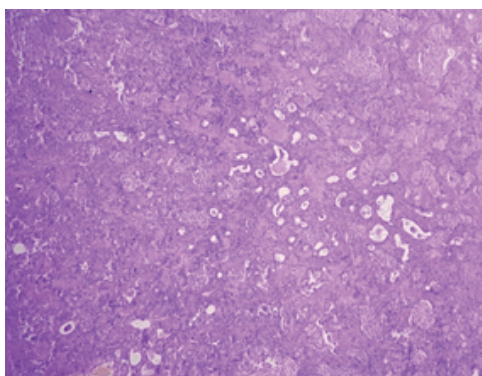
A 75 years old male presented with a history of painless, slowly progressive lump over the upper lip since past six years. There was no history of trauma and the dental history was unremarkable. On clinical examination, the mass was well circumscribed, rubbery in consistency, mobile in the upper lip measuring approximately 2 cm at

its greatest dimension. The overlying mucosa was intact and smooth. There was no pain or bleeding on palpation, no regional lymphadenopathy and his general physical and systemic examination were normal. The differential diagnosis included lipoma and minor salivary gland tumour. Surgery was performed to completely remove the fully encapsulated mass with clinically normal margins and was sent for histopathological examination. A follow-up after three months showed no signs of recurrence.

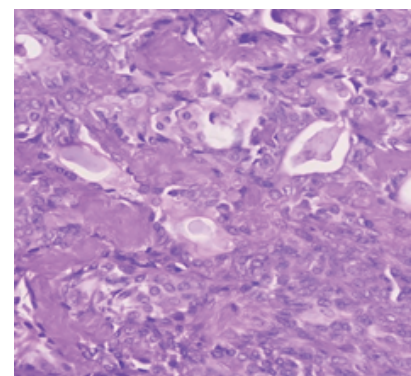
Grossly, a single grey-white, well circumscribed, firm tissue was received measuring 1.7x1.4x0.5 cm. The cut surface of the mass was solid, grey-white in colour with smooth surface. On microscopic examination, section shows encapsulated tumour comprising of islands and sheets of epithelial and myoepithelial cells arranged in duct, acini, tubule and sheets, dispersed within a background of loose myxoid stroma (Figure 1, 2, 3). There was no evidence of malignancy noted. A diagnosis of pleomorphic adenoma was made with these findings.



**Figure1: Tumour with fibrous capsule, Hematoxyline and Eosin (H&E), 4x**



**Figure 2: Tumour cells arranged in ducts, acini and tubule with myxoid stromal component, H&E, 10x**



**Figure 3: Epithelial and myoepithelial cells with myxoid stroma, H&E, 40x**

## DISCUSSION

Pleomorphic adenoma is the most commonly encountered benign tumour of the salivary gland and usually presents in the parotid gland comprising up to 70% of the parotid tumours.<sup>3, 6</sup> Tumours arising from the minor salivary gland account for 22% of all salivary gland neoplasms. Majority of them are malignant with only 18% being benign, of which pleomorphic adenoma is the commonest one.<sup>6</sup> Kroll and Hick reviewed 4042 cases of pleomorphic adenomas of the salivary gland and found that 445 cases originated in the minor salivary glands, where 16.9% of the tumours were located in upper lip and 2.9% in the lower lip ratio being 6:1.<sup>4</sup> The more occurrence of tumour in the upper lip could be due to the fact that the upper lip develops from the fusion of three complex embryonic processes and compared to lower lip, the upper lip has a greater probability of embryonic nests being trapped. This increases the risk of tumour formation in the upper lip.<sup>7</sup> There is a propensity for benign tumour to occur in the upper lip, whereas malignant lesions to predominate in the lower lip.<sup>4</sup>

Females were more commonly affected in other studies,<sup>2, 3</sup> but our case was male. The peak incidence of pleomorphic adenoma of lips was in third to fourth decade of life, with an average age of 33.2 years,<sup>4</sup> but in our case patient's age was 75 years.

Histopathologically, pleomorphic adenoma of lip is not different from the other sites, where it presents as a morphologically complex tumour with the epithelial and myoepithelial cells arranged in diverse patterns and embedded in the mucopolysaccharide stroma. The formation of capsule occurs as a result of fibrosis of surrounding salivary parenchyma, which is compressed by the tumour cells and is referred to as 'false capsule'.<sup>2, 6</sup>

The differential diagnosis of intraoral solid and asymptomatic nodules includes minor salivary gland tumours and mesenchymal tumours such as

neurofibroma, lipoma and rhabdomyosarcoma. The minor salivary gland tumours, myoepithelioma and basal cell adenoma are the primary consideration in the differential diagnosis.<sup>6</sup> The surgical treatment for pleomorphic adenoma is a complete wide surgical excision with adequate safety margins. An inadequate resection or rupture of the capsule or tumour spillage during excision can lead to local recurrence.<sup>2</sup> Vicente et al. observed an increased risk of recurrence with incomplete excision.<sup>8</sup> Furthermore, the possibility of malignant transformation of the tumour should also be taken into consideration and periodic evaluation of the patient is necessary.

## CONCLUSION

Pleomorphic adenoma of the lip is a rare tumour, and thus clinicians should have a high index of suspicion. A complete wide surgical excision is the treatment modality. Recurrence and malignant transformation can be a complication even after the surgical excision of the tumour. Therefore, long term follow-up of the patients is needed.

## REFERENCES

1. Adiyodi NV, Sequeira J, Mehra A. Twinning of Pleomorphic Adenoma: A Case Report. *Cureus*. 2020;12(1). [DOI]
2. Taiwo AO, Akinshipo A, Braimah RO, Ibikunle AA. Pleomorphic Adenoma of the Upper Lip: A Case Report. *Saudi J Med Med Sci*. 2018 Jan-Apr;6(1):32-35 [DOI]
3. Gbotolorun OM, Arotiba GT, Effiom OA, Omitola OG. Minor salivary gland tumours in a Nigerian hospital: a retrospective review of 146 cases. *Odontostomatol Trop*. 2008 Sep;31(123):17-23. [Full Text]

4. Shrestha A, Reddy NS, Ganguly SN. Pleomorphic adenoma of the upper lip: A case report. *J Coll Med Sci Nepal*. 2010;6(1):51-3. [\[DOI\]](#)
5. Lotufo MA, Júnior CA, Mattos JP, França CM. Pleomorphic adenoma of the upper lip in a child. *J Oral Sci*. 2008 Jun;50(2):225-8. [\[DOI\]](#)
6. Kataria SP, Tanwar P, Sethi D, Garg M. Pleomorphic adenoma of the upper lip. *J Cutan Aesthet Surg*. 2011;4(3):217. [\[DOI\]](#)
7. Krolls SO, Hicks JL. Mixed tumors of the lower lip. *Oral Surg Oral Med Oral Pathol*. 1973 Feb;35(2):212-7. [\[DOI\]](#)
8. Pons Vicente O, Almendros Marques N, Berini Aytes L, Gay Escoda C. Minor salivary gland tumors: A clinicopathological study of 18 cases. *Med Oral Patol Oral Cir Bucal*. 2008;31:582 [\[Full Text\]](#)