

## Unilateral Bifurcated Renal Pelvis with Partial Duplication of Ureter and An Accessory Renal Artery: A Case Report

KC Sudikshya<sup>\*1</sup>, Rauniyar Shyam Babu<sup>2</sup>

<sup>1</sup> Department of Anatomy, Lumbini Medical College, Pravash, Tansen, Palpa, Nepal

<sup>2</sup> Department of Anatomy, National Medical College and Teaching Hospital, Birgunj, Nepal.

**Date of Submission :** Feb 10, 2018

**Received in Revised Form :** Feb 25, 2018

**Date of Acceptance :** March 10, 2018

**Date of Publishing :** July 30, 2018

### ABSTRACT

Duplication of renal collecting system is the most common upper urinary tract congenital anomaly. Duplex collecting system is presence of complete or partial double pelvicalyceal system which is associated with single or double ureter. A duplicated ureter is commonly found in association with other congenital anomalies which are often an incidental finding during radiograph of abdomen and pelvic region for other purposes.

During routine dissection of a female cadaver of about 60-65 years old, in the Department of Anatomy, National Medical College, Birgunj; the bifurcated renal pelvis with incomplete duplication of ureter and an accessory renal artery was found on left side. Two segments of ureter coalesce 2.4 cm distal to the lower pole of kidney and form a single ureter. Right sided renal pelvis and ureter was normal. Both the ureters opened in the urinary bladder with single opening as usual.

Knowledge of normal anatomy as well as developmental anomalies of the urinary system is of utmost importance not only for anatomists, radiologists and urologists but also to surgeons for uneventful renal transplant.

**Keywords:** Accessory renal artery, Duplication, Kidney, Renal pelvis, Ureter.

**\*Corresponding Author:** Dr. Sudikshya KC, Department of Anatomy, Lumbini Medical College, Palpa, Nepal, Email- Sudi801@gmail.com.

### INTRODUCTION

The ureters are paired thick walled and narrow muscular tubes measuring 25–30 cm, which convey urine from kidneys to the urinary bladder and is continuous superiorly with the funnel-shaped renal pelvis. The renal arteries are the lateral branches of abdominal aorta below the origin of superior mesenteric artery at the vertebral level between L1 and L2. Near the renal hilum, each artery divides into an anterior and a posterior division, which give rise to a number of segmental arteries supplying the renal vascular segments. Accessory renal arteries are common (30% of individuals), and usually arise from the aorta above or below (most commonly below) the main renal artery and follow it to the renal hilum. They are regarded as persistent embryonic lateral splanchnic arteries.<sup>1</sup>

The definitive kidneys have two functional components; the excretory part (glomerulus, capsule and nephron tubules) that develops from metanephric blastema and the collecting part (ureter, pelvis, major and minor calyces) developing from ureteric bud at about 5<sup>th</sup> week of intrauterine life.<sup>2</sup>

According to the nomenclature established by the committee on terminology, Nomenclature, and Classification of the Section on Urology of the American Academy of Pediatrics, duplicated collecting renal systems are kidneys with two pelvicalyceal systems.<sup>3</sup>

Duplication of ureter is the most common anomaly of urinary system. It may be complete, incomplete, unilateral or bilateral. Incomplete duplication of ureter is known as bifid ureter. Bilateral duplication of ureter is rare occurring in 0.13% individuals while 0.8% individuals have bifid ureter. They may fuse at any point in their course or may separately open into the urinary bladder.<sup>1</sup>

Bifid renal pelvis and ureter is often asymptomatic and incidentally diagnosed during radiographic imaging of abdomen and pelvic region for other purposes. However, it may lead to clinical conditions like formation of renal calculi, ureterocele, vesicoureteric reflux, hydronephrosis, and urinary tract infections.<sup>4,5</sup>

Variations in renal blood supply is very crucial in renal pathologies, radiological interventions, and renal transplantations. Kidney transplant with single renal artery is comparatively easier and successful with minimal post-surgical vascular and urological complications compared to those with more than one renal artery.<sup>6</sup>

### CASE REPORT

In routine dissection of cadavers in Department of Anatomy, NMC, Birgunj, we noted unilateral bifid renal pelvis with incompletely duplicated ureter and an accessory renal artery in an approximately 60-65 years old female cadaver. The cause of deceased is unknown.

Anterior abdominal wall was incised and abdomen cavity of cadaver was opened. Abdominal viscera were removed; the posterior wall of abdomen was approached and parietal peritoneum was removed. On the right side, ureter was normal with no any abnormalities throughout its origin, course, relation and termination.

On the left side, a normal appearing kidney with bifid ureter was observed. At its beginning two separate segments of the ureter with its own renal pelvis could be distinguished. The both segments coursed down over posterior wall and later united at 2.4 cm from lower pole of left kidney. The upper segment measured 7.5 cm while lower segment measured 5.6 cm from the hilum to the point of junction. Then the ureter crossed the pelvic brim and opened into the urinary bladder wall by single orifice. The length of ureter measured 19 cm from point of union of two segments to the bladder wall. There was no other associated anomalies related to any other system.

There were two left renal arteries arising laterally from abdominal aorta. The upper one was considered an accessory renal artery because of its lesser caliber, which was comparatively longer and running downwards. At the hilum it was entering into the kidney behind renal vein, immediately in front of lower segment of renal pelvis. The lower one was considered as main renal artery as it had wider caliber. It was shorter, running upward and posterior to the former. At the hilum, it entered into the kidney just above upper segment of renal pelvis behind renal vein.

Single large renal vein was formed by fusion of three tributaries at the hilum.

Arrangement of structures at hilum: Anterior to posterior

- Renal vein
- Main and accessory renal arteries
- Upper and lower segments of renal pelvis.

Arrangement of structures at hilum: From above downwards behind renal vein

- Main renal artery
- Upper segment of renal pelvis
- Lower segment of renal pelvis with accessory renal artery.

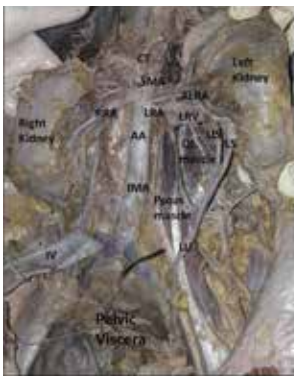


Figure 1: Kidneys along with duplicated left ureter and accessory left renal artery in situ.

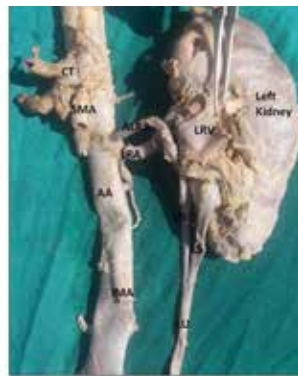


Figure 2: Left Kidney removed along with duplicated left ureter and part of Abdominal Aorta.

CT: Coeliac Trunk, SMA: Superior Mesenteric Artery, RRA: Right Renal Artery, LRA: Left Renal Artery, LRV: Left Renal Vein, ALRA: Accessory Left Renal Artery, AA: Abdominal Aorta, IMA: Inferior Mesenteric Artery, US: Upper segment of left ureter, LS: Lower segment of left ureter, QL: Quadratus Lumborum Muscle, IV: Inferior Venacava, LU: Left ureter.

## DISCUSSION

**Embryological basis:** Duplication of the ureter results from early splitting of the ureteric bud. It may be partial or complete. In partial duplication, renal pelvis is bifid and two segments of ureter meet before opening in the bladder; while in complete duplication, two ureters open separately into urinary bladder. If more than one ureteric bud develops and migrates to the metanephros, the metanephric tissue may be divided into two parts, each with its own renal pelvis and ureter. When the buds are close to each other, the ureteric orifices are in the normal position in bladder, but if the buds are widely separated, the orifices may be ectopic.<sup>2</sup>

Duplicated ureter and accessory renal arteries were reported by many researchers in earlier literatures. These may or may not associate with other anomalies. Previous studies have also enlightened that the duplicated ureters are associated with Goltz syndrome<sup>7</sup>, high cephalad kidney, duplication of the pelvis<sup>8</sup>, ectopic ureter and contralateral quadrifid ureter, and L3 hemivertebra.<sup>9</sup> Thorough study of embryogenesis of genitourinary system can best explain such abnormalities.

Duplication of ureter (complete or partial) is most commonly occurring anomaly of urinary system

i.e. approximately 1 in 20 people.<sup>10</sup> The incomplete duplication is three times more common than complete duplication (1 in 500 cases).<sup>10,11,12,13</sup> A wide variety of clinical manifestations such as ureteroureteral reflux or ureteropelvic junction obstruction leading to hydronephrosis or recurrent urinary tract infection as well as urolithiasis is found to be associated with duplicated ureter.<sup>5,14</sup> It may remain asymptomatic throughout the life,<sup>14</sup> may get diagnosed incidentally during radiographic procedures or encountered during cadaveric dissections or autopsies.

Comparatively unilateral duplication is commonly occurring than bilateral duplication which is also explained by Whitaker and Danks, who found unilateral duplication six times more than bilateral duplication.<sup>15</sup> Duplicated collecting systems are twice common in women compared with men.<sup>15,16</sup> Variation in number and origin of the renal artery is also common as well as clinically important findings in different study groups.<sup>6,17</sup>

Our study showed the presence of incomplete duplication of left ureter with an accessory renal artery in female cadaver without any associated congenital anomalies. Similar finding was reported by Chiman et al.<sup>5</sup> Das et al. reported an incomplete duplicated ureter, in right side of female cadaver without any associated congenital anomaly.<sup>18</sup> However Kate and Shinde reported duplex kidney with unilateral incomplete bifid ureter in male cadaver.<sup>4</sup> A study by Nagpal and Chauhan reported unilateral bifid ureter on the right side of a female cadaver.<sup>19</sup> Separate studies by Yuganti et al. and Fateme et al. showed an incomplete duplicated ureter on left kidney in male cadaver without accessory renal artery.<sup>14,20</sup> Matsuyama reported bilateral duplicated ureter in which two ureters originated from a single renal pelvis in female cadaver.<sup>10</sup>

## CONCLUSION

Reassessment of this study suggests that anomalies related with renal system, duplicated ureters along with variation in renal arteries are commonly seen that may or may not manifest clinically. These variations should not be ignored by anatomists, urologists, radiologists, surgeons and gynecologists as well.

## REFERENCES

1. Gray H. Kidney and Ureter. In: Peter L. Williams, editor. Gray's anatomy, The Anatomical Basis of Clinical Practice. (40th ed.) New York: Elsevier Churchill Livingstone; 2008.p 1238-41.
2. Sadler TW. Urogenital system. In: Lanhman's Medical embryology, editor. (11th ed.) Philadelphia: Wolters Kluwer Lippincort William and Wilkins; 2010. p. 235-63.
3. Glassberg KI, Braren V, Duckett JW et al. Suggested terminology for duplex systems, ectopic ureters and ureteroceles. J Urol. 1984; 132:1153-4.
4. Kate DR, Shinde RB. Duplex Kidney- An Anatomical and Clinical Insight. J Dent Med Sci. 2015; 14(4):14-7.
5. Kumari C, Motwani R, Jhahria SK, Rani N, Jain P, Raza K et al. Higher right kidney and partial duplication of left ureter: a case report. Int J Anat Res. 2017; 5(2.2):3788-90.
6. Mishra A, Sharma PK, Manik P, Mishra PP. Bilateral multiple renal arteries: A case report. OA Anatomy. 2014; 2(3):22-4.
7. Gunduz K, GunalpI, ErdenI. Focal dermal hypoplasia (Goltz's syndrome). Ophthalmic Genet. 1997; 18:143-9.
8. Al Attia HM. Cephalad Renal Ectopia duplication of pelvicalyceal system and patent ductus arteriosus in an adult female. Scand J Urol Nephrol. 1999; 33:257-9.
9. Bhandarkar AD, Raju AM, Rao MS. Single unilateral ectopic bifid ureter with contralateral orthotopic quadrifid ureter -a rare combination. J Postgrad Med. 1997; 43:104-5.
10. Matsuyama N. A Case of Bilateral Duplicated Ureter - Gross Anatomy. J Case Rep Stud. 5(6): 601.
11. Fernbach SK, Feinstein KA, Spence K, Lindstorm CA. Ureteral duplication and its complications. Radiographics. 1997; 17(1):109-27.
12. Dahnert W. Radiology Review Manual. 6th ed. Philadelphia: Lippincott Williams & Wilkins; 2007.
13. Prakash RT, Venkatiah J, Bhardwaj AK et al. Double ureter and duplex system: a cadaver and radiological study. J Urol. 2011; 8:145-8.
14. Vaidya YP, Waghmare JE, Tarnekar AM, Shende MR. Unilateral isolated incompletely duplicated ureter. J Mahatma Gandhi Inst Med Sci. 2014; 19:148-50.
15. Whitaker J, Danks DM. A study of the inheritance of duplication of the kidneys and ureters. J Urol. 1966; 95:176-8.
16. Siomou E, Papadopoulou F, Kollios KD, et al. Duplex collecting system diagnosed during the first 6 years of life after a first urinary tract infection: a study of 63 children. J Urol. 2006; 175:678-81.
17. Gupta A, Gupta R, Singha RK. The Accessory Renal Arteries: A Comparative Study in Vertebrates with its Clinical Implications. J Clin Diag Res. 2011; 5(5):970-3.
18. Das S, Dhar P, Mehra RD. Unilateral Isolated Bifid Ureter -A Case Report. J Anniston India. 2001; 50:43-4.
19. Nagpal H, Chauhan R. Unilateral duplex collecting system with incomplete duplication of ureter - a case report. Int J Res Med Sci. 2017; 5:2254-6.
20. Tahmasebi F, Barati S, Mazaheri Z. Case Report: Unilateral Incompletely Duplicated Ureter without any Accessory Renal Artery. Anatomical Sci. 2015; 12(3):141-3.