

Digital Photographs in Analysis of Lip Prints for Gender Identification

Dr. Pratibha Poudel,¹ Dr. Ritesh Sree,¹ Dr. Swagat Kumar Mahanta²

¹Department of Oral Pathology, Kathmandu University School of Medical Sciences, Dhulikhel, Kavre, Nepal;

²Department of Community Dentistry, Kathmandu University School of Medical Sciences, Dhulikhel, Kavre, Nepal.

ABSTRACT

Introduction: Cheiloscopy is considered as an emerging method in forensic odontology for identification of gender. There are several methods given in literature to identify the lip print types. Digital photographs can be used to study the lip prints for gender identification.

Objective: The aim of the study was to identify the predominant lip print pattern in males and females by using digital photographs.

Methods: This analytical cross-sectional study included 206 subjects, comprising 103 males and 103 females. Digital photographs were used to identify the lip print patterns. The classification given by Suzuki and Tsuchihashi was used to further classify the lip patterns. Kappa test was applied to check for inter observer variation. Statistical analysis was done using SPSS version 23. The association between gender and lip print type was tested by Chi square test.

Results: Type I was the most common lip print followed by Type I'. Type V was the least common lip print followed by Type IV. Type I and Type II were the most common pattern in females and males respectively and these differences were found to be statistically significant ($p < 0.01$).

Conclusion: Digital photographs are very useful for identification of lip print pattern. The variation in lip print pattern among males and females can be taken as an aid in gender determination.

Keywords: Cheiloscopy; forensic; gender; identification; odontology.

INTRODUCTION

Identification of victim is very important in major disasters, civil cases and criminal cases.¹ Finger print, deoxyribonucleic acid analysis and dental records are the common technique for identification. Nonetheless, these techniques require qualified personnel and in certain circumstances, it can become difficult to carry out these techniques. So there is still a need for reliable alternative methods to establish identity of a person.²

Cheiloscopy is an emerging method for identification of an individual.^{3,4} Similar to finger print, lip print is unique, invariable and permanent.¹ These patterns can be identified as early as sixth week of intrauterine life and henceforth they change rarely.⁵

Majority of the studies have used lipstick to study the lip print patterns. However, this is very tedious process and unhygienic if same lipstick is used for all the subjects. Also some of the prints could be spoiled due to smudging.¹ As this is the era of digitalisation, using digital photographs to identify lip print pattern could be an easy alternative to overcome these drawbacks. Therefore, this study is an attempt to study the lip print patterns for gender identification by using digital photographs.

METHODS

This analytical cross-sectional study was conducted among 206 undergraduate dental students of Kathmandu University School of Medical Sciences (KUSMS), in November, 2019 after taking approval from Institutional Review Committee of KUSMS (IRC-KUSMS No. 213/19). The sample size was determined based on the study done by Badiye and Kapoor.¹ All the subjects were explained about the purpose of study and informed consents were obtained. Subjects having gross deformities of lip like cleft lip, ulcer, traumatic injuries on lip were excluded from the study. The subjects were made to stand straight with the head aligned in a Frankfurt plane. The lip photograph was taken in natural state without any application of lipstick, lip gloss or lip filler (Figure 1).

The subjects were photographed twice using digital camera

Correspondence:

Dr. Pratibha Poudel

Department of Oral Pathology, Kathmandu University School of Medical Sciences, Dhulikhel, Kavre, Nepal.

email: poudelpratibha@kusms.edu.np

Citation

Poudel P, Sree R, Mahanta SK. Digital Photographs in Analysis of Lip Prints for Gender Identification. J Nepal Soc Perio Oral Implantol. 2019;3(6):54-7.

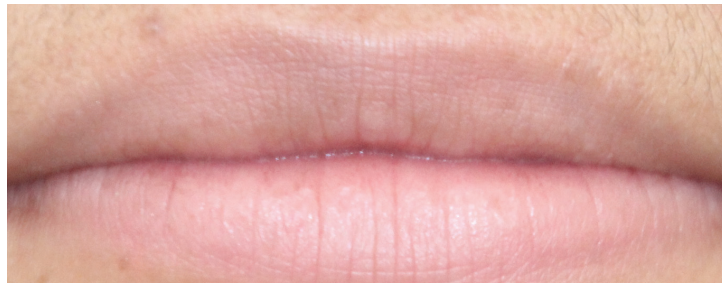

Figure 1: Lip photograph showing the lip prints.

(Canon EOS 60D) with a tripod stand to reduce the chances of obtaining blurred photographs. For analysis central portion of lower lip (10 mm wide) was considered, as this area is always visible even in small fragment and also due to numerical superiority of lines in the area of study.⁶ The classification given by Suzuki and Tsuchihashi was used to further classify the lip patterns.⁷

- Type I: Long vertical (clear-cut vertical grooves that run across the lips)
- Type I': Short vertical (partial length groove of Type I)
- Type II: Branched grooves (branching Y-shaped pattern)
- Type III: Intersected grooves (criss-cross pattern)
- Type IV: Reticular pattern (grooves that form a rectangular pattern)
- Type V: Mixed/Indefinite (grooves that do not fall into any of the above categories and cannot be differentiated morphologically/ undetermined)

Identification of lip pattern was done by two observers. Cohen's kappa statistic was used to check for inter observer variation. Statistical analysis was done using SPSS version 23. The association between gender and lip print type was tested by Chi square test with p value < 0.01.

RESULTS

A total of 206 participants were included in the study, out of which 103 were males and 103 were females (Table 1).

The mean age of subjects in the study was 24 years (24.40 ± 4.87 years). First observer identified 53 participants (25.7%) with type I, 48 (23.3%) with Type I', 40 (19.4%) with Type II,

38 (18.4%) with Type III and 27 (13.1%) with Type IV. Second observer identified 55 participants (26.7%) with type I, 48 (23.3%) with Type I', 42 (20.4%) with Type II, 35 (17.0%) with Type III and 26 (12.6%) with Type IV. None of the study participants had Type V lip print (Table 2).

Type I was the most common lip print followed by Type I'. Type V was the least common lip print followed by Type IV. Both the observer identified Type II and Type I as most common lip print for males and females respectively (Figure 2, 3).

Table 1: Frequency distributions of subjects based on the gender.

Gender	n (%)
Male	103 (50.0)
Female	103 (50.0)
Total	206 (100.0)

Table 2: Frequency distribution of subjects based on type of lip prints identified by two observers.

Type of lip print	Observer 1 n(%)	Observer 2 n (%)
Type I	53 (25.7)	55 (26.7)
Type I'	48 (23.3)	48 (23.3)
Type II	40 (19.4)	42 (20.4)
Type III	38 (18.4)	35 (17.0)
Type IV	27 (13.1)	26 (12.6)
Type V	0 (0.0)	0 (0.0)
Total	206 (100.0)	206 (100.0)

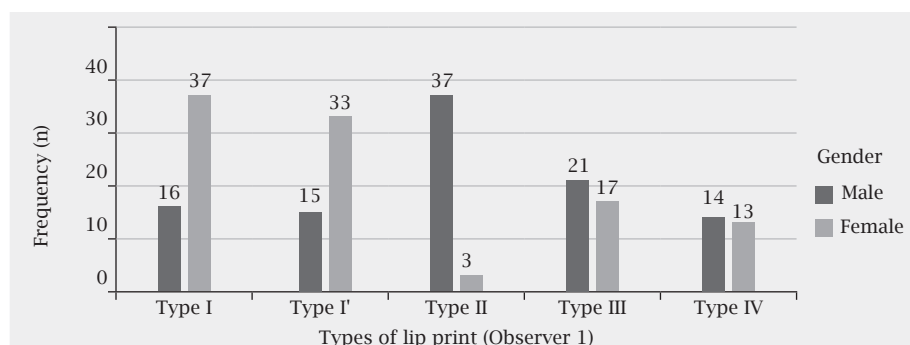


Figure 2: Frequency distribution based on types of lip print pattern in males and females as identified by first observer.

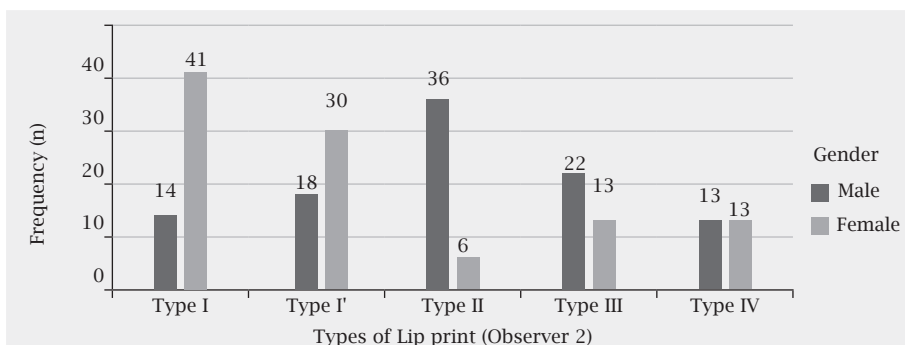


Figure 3: Frequency distribution based on types of lip print pattern in males and females as identified by second observer.

Table 3: Lip print patterns: males versus females.

Observer	Chi square	df	p value
Observer 1	44.42	4	<0.001
Observer 2	39.99	4	<0.001

Chi square test showed statistically significant differences between lip print types in males and females ($p < 0.01$, Table 3).

The Kappa value (+0.87) indicated a positive agreement among the examiners for the determination of lip print among the subjects ($p < 0.01$).

DISCUSSION

Lip prints are considered as an important aid in forensic investigation and gender identification. They are considered as analogous to finger print and most important forms of transfer evidence.⁸ They are unique and don't change throughout the life of a person.⁴ It has been verified that they recover even after inflammation, trauma, and diseases like herpes virus infection.⁵ They are different even between twins which highlights the fact that it is unique for an individual.² Lip prints are usually left at crime scene. Analysis of these prints and comparison with those of the suspected person may be useful for identification.² In some cases when sufficient evidences are not there for direct match, they can serve as the means for identification of gender and narrow down the investigation by half.^{5,9}

Several methods have been reported in literature for recording the lip prints. The conventional lipstick method that has been widely used in literature has its own drawbacks. The major drawback with this method is that it is difficult to store the prints for longer time without distortion. This in turn makes difficult to create a comprehensive database. Apart from this, most of the male subjects hesitate to participate in study, as it requires application of lipstick. Therefore, in this study we have tried to study the lip prints pattern for gender identification by using digital photographs. Though the lines and furrows are present in both upper and lower lip, only the middle portion of lip is

mostly taken into consideration.⁸ Sivapathasundaram et al. has suggested the middle part of lower lip (10 mm wide) as the most suitable area to study the pattern of lip print as this is almost always visible in any trace.⁶ In the present study also we have considered the same area to identify the pattern of lip print.

Among 206 study participants, Type I was the most common lip print followed by Type I'. Our findings are in agreement to the findings of previous studies done in Nepalese population who also reported Type I to be the most common lip print in their study.^{10,11} None of the participants in our study had Type V lip print and this corroborates to the findings of Timsinha and Kar.⁷ However results from Indian population are somewhat different from our findings. Badiye and Kapoor studied the morphologic variation in lip print pattern in central Indian population and found that Type IV was most prevalent and Type III was least prevalent lip print in these population.¹

In our study, the most common type of lip print in male was Type II and in females was Type I and these differences were found to be statistically significant ($p < 0.01$). Our findings are in accordance to the findings of Bajracharya et al. who also reported Type II and Type I to be the most common lip print type in males and females respectively.¹¹ Badiye and Kapoor also reported Type II to be most predominant pattern in males.¹ Sharma et al. reported Type I to be most predominant pattern in females.⁸ These findings are similar to our findings. However, in contrast to our findings, Randhawa et al. reported Type III to be the most common pattern in males but for females they also reported Type I as the predominant pattern.¹² Jatti and Rastogi reported Type II to be the most common pattern in both males and females in south Indian population.¹³ Nevertheless, these variations could be due to different race and ethnicity. Studies have shown that lip print varies depending on ethnic and racial differences.⁷

Thus through this study we have tried to study the lip print pattern by using digital photography method. This method overcomes the flaws of conventional lipstick methods such as spoiling of prints due to smudging of the lipstick. Hence,

the authors recommend the use of digital photographs for study of lip print for various purposes including research.

CONCLUSION

Lip prints can be considered as an adjunctive tool in identification of gender. The use of digital photographs can be very instrumental in creating the comprehensive database

that might be useful for future reference. However, work on similar ground considering larger sample are needed to validate the findings of this study.

Conflict of Interest: None

REFERENCES

1. Badiye A, Kapoor N. Morphologic variations of lip-print patterns in a Central Indian population: A preliminary study. *Med Sci Law*. 2016 Jul;56(3):200-4.
2. El Domiaty MA, Al-gaidi SA, Elayat AA, Safwat MD, Galal SA. Morphological patterns of lip prints in Saudi Arabia at Almadinah Almonawarah province. *Forensic Sci Int*. 2010 Jul 15;200(1-3):179.e1-9.
3. Wrobel K, Doroz R. Method for identification of fragments of lip prints images on the basis of the generalised hough transform. *J Med Informatics Technol*. 2013;22:189-93.
4. Mohanty B, Jadon AK, Rathore S, Bhatt P, Gupta S, Vaid S. Cheiloscopy As a Means of Personal Identification in Forensic Dentistry: A Study. *Int J Prev Clin Dent Res*. 2015;2(2):42-4.
5. Augustine J, Barpande SR, Tupkari J V. Cheiloscopy as an adjunct to forensic identification: A study of 600 individuals. *J Forensic Odontostomatol*. 2008 Dec;26(2):44-52.
6. Academy T, Academy R, Trakt SS. Efficacy of cheiloscopy in gender determination- A digital approach. *Asia Pacific J Adv Bus Soc Stud*. 2017;3(1):290-6.
7. Timsinha S, Kar SM. A study on distribution and gender wise predilection of lip print pattern. *AJMS*. 2019 Jun 20;10(4):61-5.
8. Sharma P, Saxena S, Rathod V. Cheiloscopy: The study of lip prints in sex identification. *J Forensic Dent Sci*. 2009;1(1):24-7.
9. Vahanwala SP, Parekh BK. Study of lip prints as an aid to forensic methodology. *J Forensic Med Toxicol*. 2000;17(1):12-8.
10. Ghimire N, Ghimire N, Nepal P, Upadhyay S, Budhathoki SS, Subba A, et al. Lip print pattern: an identification tool. *Health Ren*. 2013;11(3):229-33.
11. Bajracharya D, Mainali A, Vaidya A, Thapa S, Pandey S. Cheiloscopy : An Aid in Gender Identification. *J Nepal Dent Assoc*. 2013;13(2):80-3.
12. Randhawa K, Narang RS, Arora PC. Study of the effect of age changes on lip print pattern and its reliability in sex determination. *J Forensic Odontostomatol*. 2011 Dec 1;29(2):45-51.
13. Jatti D, Rastogi P. Digital analysis of lip prints for personal identification: A cross-sectional study in south Indian population. *J Indian Acad Forensic Med*. 2015;37(3):289-93.