

## Prosthodontic Management of Flabby Ridge with Modified Impression Technique: A Case Report

Maskey B,<sup>1</sup> Kandel K,<sup>2</sup> Regmi M<sup>3</sup>

<sup>1</sup>Associate Professor, Department of Prosthodontics and Maxillofacial Prosthetics, People's Dental College and Hospital, Kathmandu

<sup>2,3</sup>Intern, People's Dental College and Hospital, Kathmandu

### ABSTRACT

Complete denture is a commonly used prosthesis used to replace missing dentition and associated structures in oral cavity. The success of complete denture is dependent on several factors, among which the health of the underlying denture bearing area plays a significant role. Any compromises on the quality of these denture resting areas, be it in the form of inflammation, ulceration, hyperplastic tissue, to name a few, will certainly affect the overall prognosis of the dentures. Compromised quality in the form of flabby ridge is not an uncommon clinical presentation and should always be considered during denture fabrication. Attempts have been made, both surgically and conservatively to accommodate these tissues. This case report describes one of the conservative methods wherein modification in impression making using conventional impression material was undertaken.

**Key words:** Complete denture; Denture resting areas; Flabby ridge; Impression making

### INTRODUCTION

A fibrous or flabby ridge is a superficial area of mobile soft tissue affecting the maxillary or mandibular alveolar ridges.<sup>1</sup> These tissues develop in edentulous ridge as the soft hyperplastic tissue replaces the alveolar bone. This condition can result from bone resorption due to several reasons including the faulty prosthesis.<sup>1</sup> The reported prevalence is about 24% in edentulous maxilla and 5% in edentulous mandible.<sup>2</sup> These tissues complicate the process of denture fabrication and adversely affect the stability, retention and support of complete denture prosthesis. These fibrous tissue gets compressed during impression making and later tend to recoil and displace the denture at

the time of denture delivery.<sup>3</sup> So, it is of utmost importance to accommodate these tissues for maintaining the oral health and extend the longevity of denture.

There are basically two approaches in managing the flabby tissues discussed in the literature. First, a surgical approach which includes removal of the hyperplastic tissue followed by a conventional or an implant supported prosthesis on the residual denture bearing area. Second, non-surgical approach wherein modification in impression technique or material is advocated with conventional prosthesis delivery.<sup>2</sup> This case report discusses about a non-surgical approach with modified impression technique for recording the flabby ridge of anterior maxillary and mandibular region.

*Conflict of Interest: None*

#### \*Corresponding Author

Dr. Brijesh Maskey,  
Associate Professor, Department of Prosthodontics  
and Maxillofacial Prosthetics, People's Dental  
College and Hospital, Kathmandu  
E-mail: bridgesmaskey@yahoo.com

### CASE REPORT

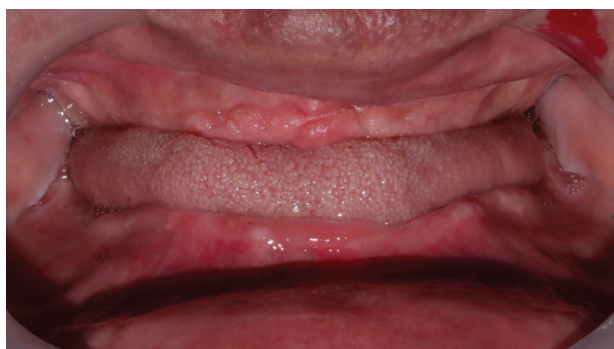A male patient of age 75 years came to the Department of prosthodontics at People's Dental College and Hospital with a chief complaint of pain in lower anterior region of

jaw while using the previous denture. It was fabricated a month after complete removal of teeth 7 years back in a private clinic. There was no problem associated with the dentures until a year ago. There was no significant medical history reported. On intraoral examination, flabby tissue in the maxillary and mandibular anterior region extending from right canine region to the left canine region with slight erythema over ridge of lower anterior region was reported (Figure 1). The tissue was mobile and irritated. Various treatment options were discussed with the patient including surgical and implant retained prosthesis but patient seemed reluctant. So, prosthetic management of the case was planned with modification of the conventional impression technique to accommodate the flabby tissue.

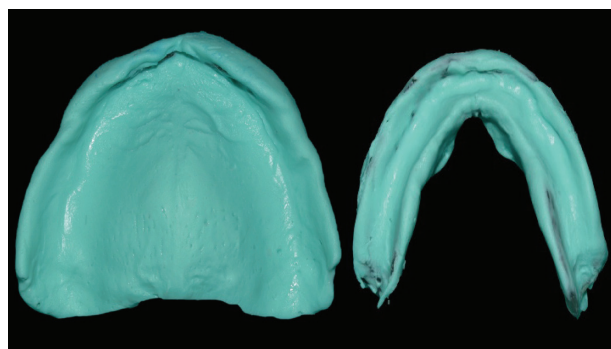
The preliminary impression was made using alginate (Tropicalgin normal setting, Zhermack) in perforated edentulous trays and poured in dental plaster (Figure 2). The flabby tissue areas were identified and marked on the maxillary and mandibular cast (Figure 3). A relief wax

was placed over the marked region (Figure 4) and wax spacer was placed over it. Special trays were fabricated for mandibular and maxillary arch using self-cure acrylic resin. These trays were border molded using green stick and the wax spacer as well as relief wax were removed. Several vent holes were made corresponding to the flabby tissue region using 2mm width straight fissure bur (Figure 5). The tray adhesive was applied over the tray and final impression was made using light body elastomer (Figure 6).

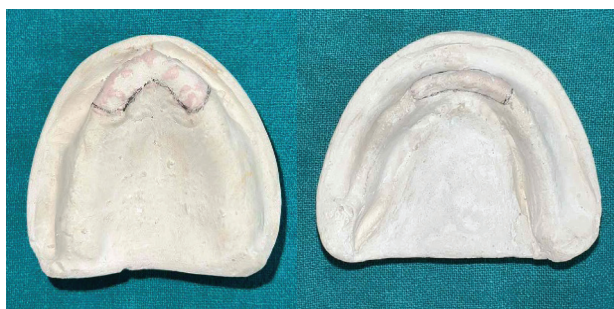Beading of the final impressions were done with a mixture of plaster and pumice at the ratio of 1:1 and boxed using base plate wax (Figure 7).<sup>8</sup> The master cast was obtained and denture base with occlusal rims were fabricated. Thereon, jaw relation, teeth arrangement, try-in was performed. The processing was done in conventional manner and the dentures were delivered to patient after trimming, finishing and polishing. Few denture adjustments were done and patient was satisfied with the retention, stability, aesthetics and function at subsequent visit.



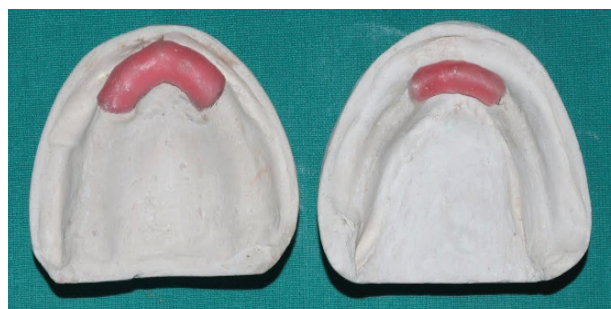**Figure 1:** Initial presentation



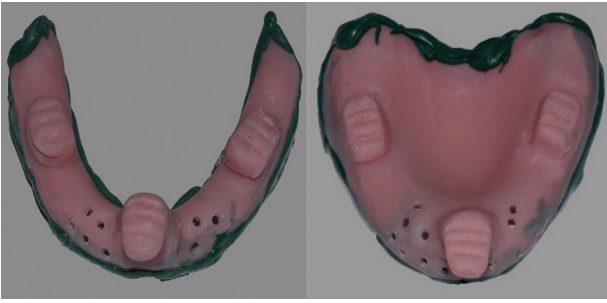
**Figure 2:** Primary impression



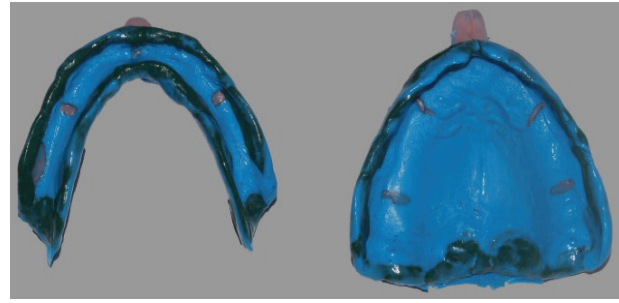
**Figure 3:** Area of flabby ridge marked on primary cast



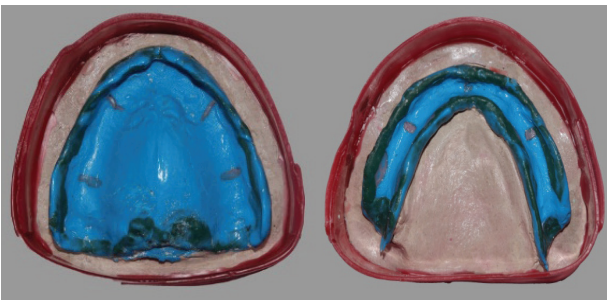
**Figure 4:** Relief wax placed over the marked area



**Figure 5:** Escape holes made on custom tray corresponding to area of flabby ridge



**Figure 6:** Final impression made using light body elastomer



**Figure 7:** Beading with plaster pumice mixture and boxing using base plate wax

## DISCUSSION

Flabby ridges pose very unique situation unless diagnosed and carefully planned. They can remain compressed under the dentures, recoil in a while and effect the retention and stability of the dentures initially and may cause pain and tenderness during function and at rest in a long run. Hence, these should be managed for effectiveness of complete denture treatment and patient satisfaction. The literature suggests surgically removing the fibrous tissue can be an option but often times, creates a bigger prosthodontics challenge with very limited denture support to rest on. Implant retained prosthesis can be an excellent option post-surgical removal of the deceased tissue with promised stability and retention. However, the complexity of the surgery, the need for trained personnel and most importantly, the expense can often times deter from its routine application. Additionally, it may be unsuited for patient with complex medical histories. On the other hand, literature also suggests conventional

prosthodontic options with few modifications in procedures which can reliably address these situations.

Different impression techniques and materials have been discussed in the literature. The choice primarily relies on patient presentation, individual clinician preference, feasibility in terms of access to material and patient choice. In this case, efforts were made to record the flabby tissue at rest during final impression which formed the basis for conservative approach. Provisions for vent holes in custom trays as suggested by 'Selective perforation tray technique'<sup>6,7</sup> in addition to relief wax<sup>7</sup> was given simultaneously to minimize compression on the tissues while recording. The relief wax placed during custom tray fabrication provided abundant space for low viscosity, light body final impression material to flow and the vent holes provided an escape route for the material which further relived the area of concern during impression making. This major advantage of this combination technique is the assurance of recording the tissue under minimal pressure than the previously discussed techniques. Additionally, the technique offers a simple, effective means for managing flabby ridge which can be performed in every dental setting.

## CONCLUSION

Flabby ridge during complete denture fabrication poses a unique prosthodontics challenge which needs special consideration. Modifying the

impression technique to accommodate the fibrous tissues can be a simple, cost effective, noninvasive yet acceptable modality managing these cases.

### ACKNOWLEDGEMENT

Lab technician Bhramadev Mandal for the lab support.

### REFERENCES

1. Bansal R, Kumar M, Garg R, Saini R, Kaushala S. Prosthodontic rehabilitation of patient with flabby ridges with different impression techniques. *Indian J Dent.* 2014 Apr;5(2):110-3. doi: 10.4103/0975-962X.135296. PMID: 25565737; PMCID: PMC4184326
2. Crawford RW, Walmsley AD. A review of prosthodontic management of fibrous ridges. *Br Dent J.* 2005 Dec 10;199(11):715-9; quiz 740-1. doi: 10.1038/sj.bdj.4812968. PMID: 16341179.
3. Bhatia P, Tripathi S, Madan R. An ingenious approach of recording the flabby ridge in construction of complete denture. *IJAR.* 2019; 9 (5): 1-2.
4. Kumar MS, Hussain M, Thombare R. Rehabilitation of Flabby Tissue-A Case Report. *Journal of the Indian Dental Association.* 2011;5(7):833.
5. Maskey B, Mathema SR, Bhochhibhoya A. A Simplified Impression Technique for a Flabby Maxilla-A Clinical Report. *Journal of Nepalese Prosthodontic Society.* 2018 Dec 31;1(2):96-9. DOI: <https://doi.org/10.3126/jnprossoc.v1i2.23864>
6. Singh RK, Patil N, Datta A, Pattedar A, Billesh NK. Impression techniques for management of flabby ridges in complete denture patients: A review of literature. *Int J Appl Dent Sci.* 2022;8(1):31-6. DOI: <https://doi.org/10.22271/oral.2022.v8.i1a.1403>
7. Pai U Y, Reddy V S, Josi R N. A single step impression technique of flabby ridges using monophasic polyvinylsiloxane material: a case report. *Case Rep Dent.* 2014;2014:104541. doi: 10.1155/2014/104541
8. Kulkarni P R, Kulkarni R S, Jain S. A New Hybrid Technique for Beading and Boxing of Complete Denture Final Impressions. *JDMT.*2017;6(3): 103-7. Doi. [10.22038/JDMT.2017.8937](https://doi.org/10.22038/JDMT.2017.8937)