

Root Guided Immediate Implant Placement at Mandibular Molar Site: A Case Report

Pradhan B¹, Joshi SP², Sah S³

¹PG Resident, Department of Prosthodontics, National Academy of Medical Sciences, Bir Hospital, Kathmandu, Nepal

²Professor, Department of Prosthodontics, National Academy of Medical Sciences, Bir Hospital, Kathmandu, Nepal

³Assistant Professor, Department of Prosthodontics, National Academy of Medical Sciences, Bir Hospital, Kathmandu, Nepal

Abstract

With the advancement in science and technology, Immediate implant placement has become a widely used and well accepted alternative to traditional treatment protocols. Post extraction implant placement in multirooted molar area is challenging. The primary stability in molar areas is achieved by engaging the interradicular bone but slipping of osteotomy drill to mesial or distal root socket during implant bed preparation is the main problem in post extraction immediate implant placement. Use of surgical guide, pre-extractive interradicular implant bed preparation and the combination of both these techniques has been used to overcome the problem related to immediate implant placement at molar sites.

This paper presents an alternative approach in immediate Implant placement in multi rooted molar area that uses the anatomy and morphology of roots in guiding the osteotomy to provide an ideal 3-dimensional implant positioning.

Key words: Immediate implant; Primary stability; Surgical guide.

Introduction

Immediate implant placement is defined as the placement of an implant into the extraction socket at the time of tooth extraction.¹ The placement of immediate implant was reported by Schulte and Heimke and Schulte et al in 1976.² Immediate implant placement offers many advantages over the conventional approach which includes fewer number of surgical procedures, reduction in overall treatment time, increase in patients comfort and satisfaction.^{3,4} Reports have shown that success and survival rates of immediate implants are similar to those of traditional protocols.⁵ However, immediate implant placement in

multirooted teeth is challenging due to reduced thickness of interradicular septum, chances of deflection of osteotomy drill from surface of bone septa.

This article presents an alternative approach in immediate Implant placement in multi rooted molar area that uses the anatomy and morphology of roots in guiding the osteotomy to provide an ideal 3-dimensional implant positioning.

Case Report

A 20 years old female patient reported to Dental Department, Prosthodontic Unit of Bir Hospital with the chief complain of grossly decayed tooth in right side of lower jaw and wanted its replacement. There was no relevant medical history affecting the dental treatment. Intra oral examination revealed grossly decayed 46 (Fig. 1). Radiographic examination revealed root canal treated 46 fractured at cervical third. Upon endodontic consultation, the tooth had

*Corresponding Author

Dr. Bismita Pradhan

PG Resident

Department of Prosthodontics

National Academy of Medical Sciences, Bir Hospital, Kathmandu, Nepal

E-mail: vbismita@gmail.com

poor prognosis and was advised for extraction.

Treatment options of either immediate implant placement or delayed implant placement, or fixed partial denture were explained to the patient along with advantages and disadvantages of each treatment option. The patient had limited time and decided to go with immediate implant placement. Primary impression was made with irreversible hydrocolloid impression material and diagnostic cast was poured with Type III dental stone. CBCT was taken and implant positioning was determined using SLIDEXIS 4 software (Fig. 2). Laboratory investigations including complete blood count, Hbs Ag, HIV, Vit D were sent to rule out any underlying pathology. The reports obtained were within normal limits. Finally, the surgery for immediate implant placement was planned.

Following local anaesthesia, coronal reduction of 46 was done up to the gingival margin. Pre extractive interradicular implant bed preparation was done; osteotomies were performed directly through the remaining root complex without flap elevation. Initial osteotomy was made at the center of the inter-radicular septum with the pilot bur, taking care to follow the long axis of the tooth (Fig. 3). Guiding pin was placed in initial osteotomy site and radiograph was taken to ensure the correct direction of the osteotomy (Fig. 4). After the direction of the initial osteotomy was verified, the site preparation was completed. The osteotomy was

extended beyond the root length to gain 2-3 mm of sound apical bone. After the final osteotomy was prepared through the centre of existing roots, the roots were extracted with minimal trauma using periosteal elevator (Fig. 5). The extraction socket was thoroughly curetted and disinfected with gauze piece soaked with betadine for 5 minutes. The length of the implant was selected to extend between 2 or 3 mm beyond the apices of the tooth to be extracted to enhance the initial stability of the implant. In this case, dental implant of 4.5 x 12 mm (Bredent) was placed. Adequate insertion torque (25 N-cm) and sufficient primary stability allowed the non-submerged healing approach. Since the jumping distance was more than 2mm, Bone graft (Bio Oss, Geistlich) was used to fill the gap (Fig. 6) and customized healing abutment was placed (Fig. 7-8). Post-operative instructions were given along with CHX mouthwash and antibiotic coverage for a week. Patient was recalled in between to check the healing of implant site. After 4 months following the procedure, a radiograph was taken which showed a complete healing of the extraction socket and healthy peri implant tissue condition thus prosthetic treatment was initiated (Fig. 9). The gingival contours of customized gingival former were copied using light body and putty with help of light cure composite resin. Impression was made using close tray technique (Fig 10). Zirconia screw retained crown was given as definitive restoration (Fig. 11-12).

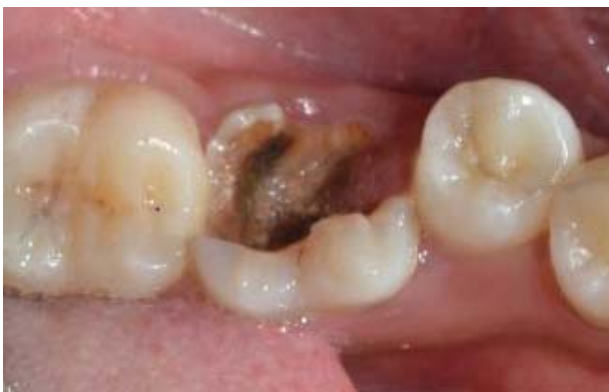

Figure 1: Grossly decayed 36

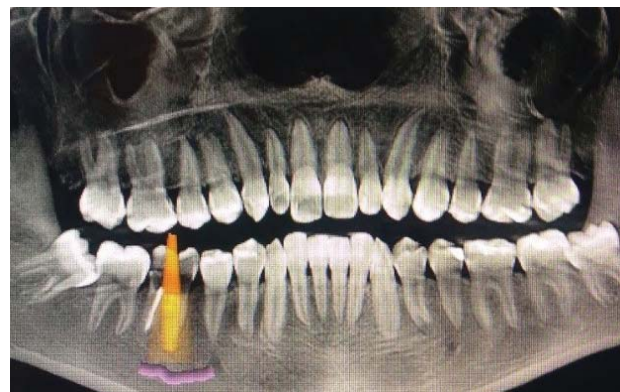


Figure 2: Implant planning using SLIDEXIS Software

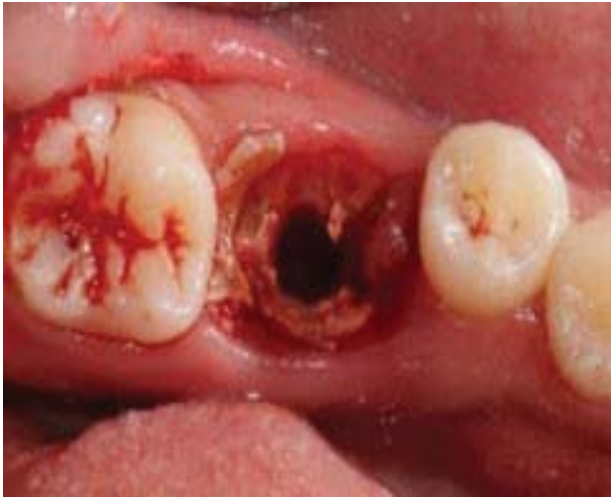

Figure 3 Osteotomy between the roots

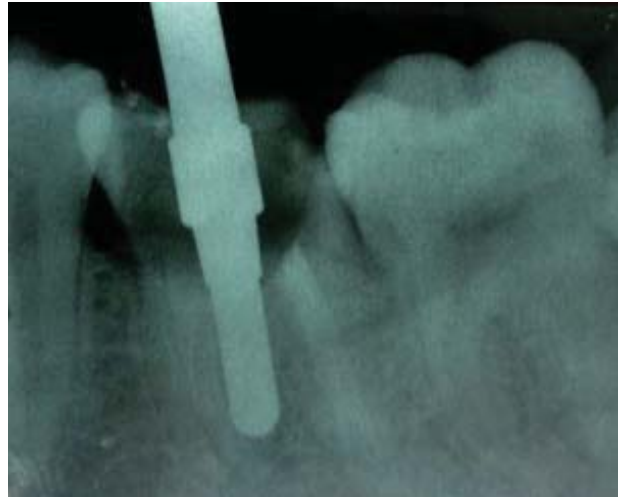

Figure 4: Radiograph with guiding pin

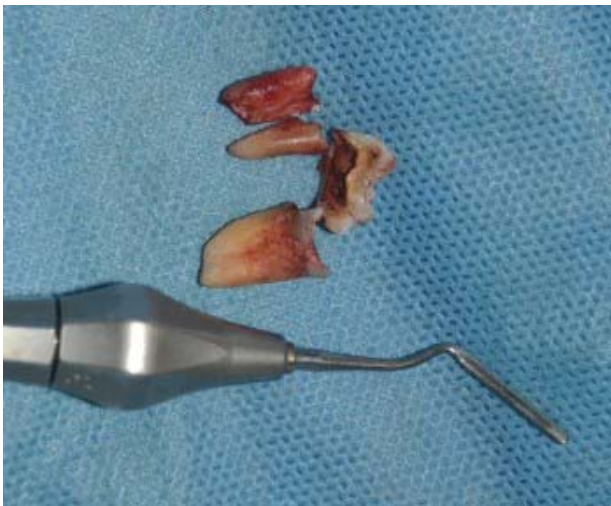

Figure 5 Extraction of tooth using periosteal elevator

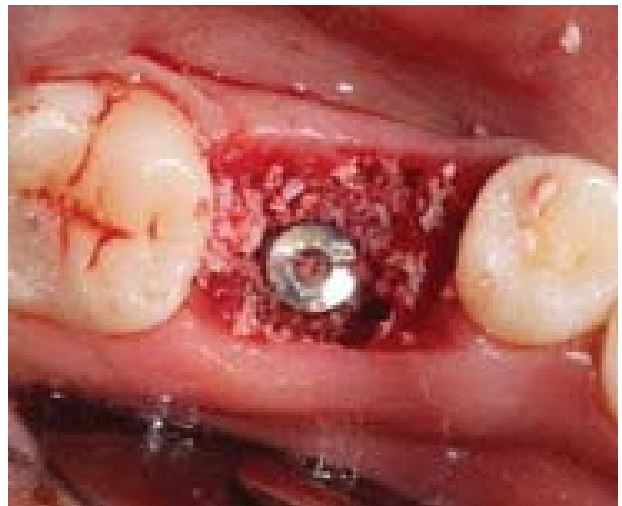

Figure 6 Placement of implant and Bio Oss in osteotomy site

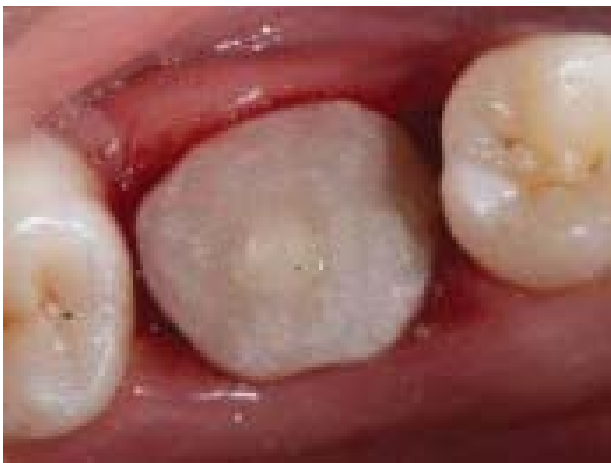

Figure 7: Customized gingival Former

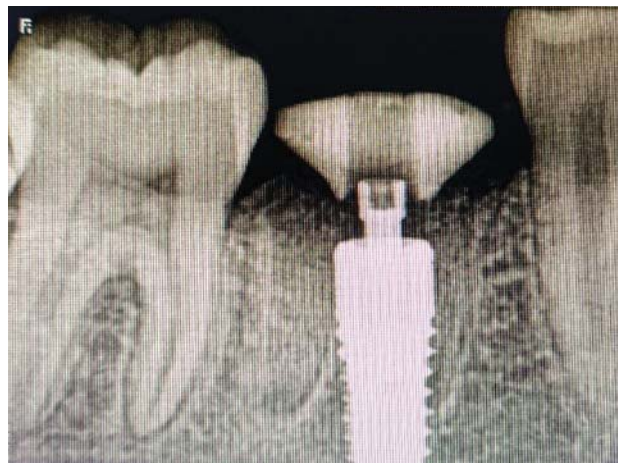

Figure 8: Radiograph after placement of gingival former

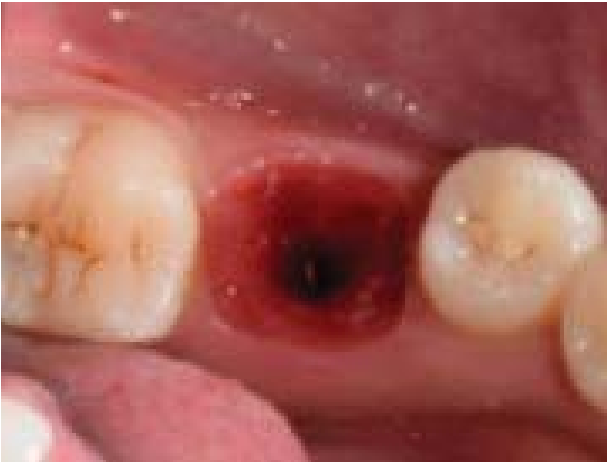

Figure 9: Soft tissue profile after healing

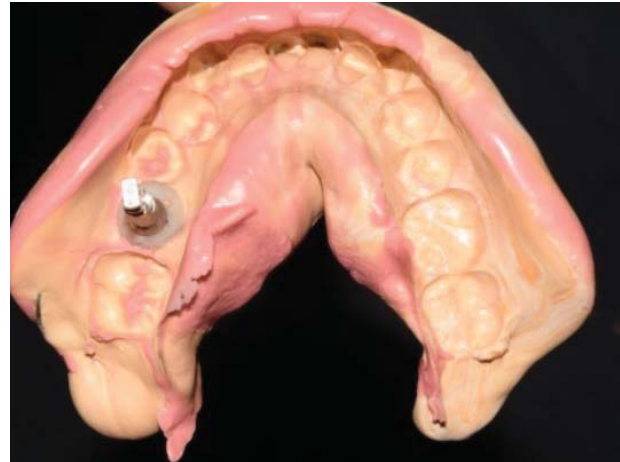

Figure 10: Impression using close tray technique

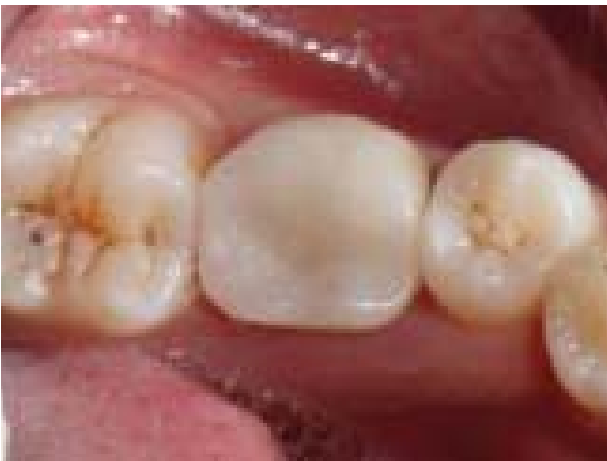

Figure 11: Screw retained all ceramic crown in place

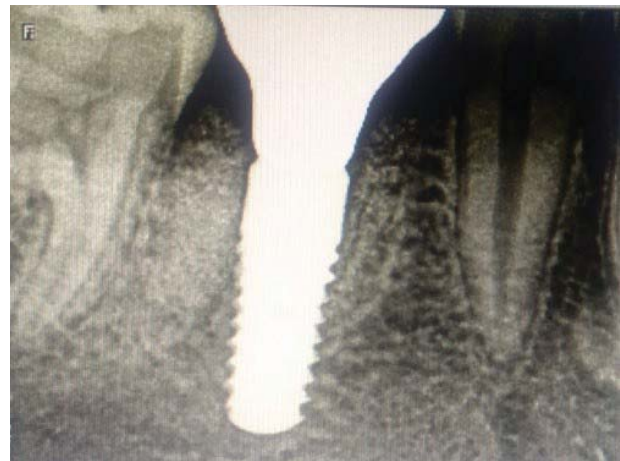

Figure 12: Radiograph after placement of Implant crown

Discussion

With the psychological and economic impact of reduction in number of surgeries and in treatment time the use of immediate implant is gaining popularity. Atieh *et al.* (2010) in his review article on survival rates of immediate implants after evaluating data of 1013 implants in nine studies reported a survival rate of 93.9% to 100% over an observation period of upto 11 years. Lang *et al.* (2012) in his review article also reported high survival rates for immediate implants placed in posterior mandibular region. With careful patient selection and precise implant placement procedure, the predictably

and survival rates of immediate implants are comparable to delayed implants placed in healed sites.³ However, immediate post extraction implant placement in multirooted teeth is difficult and challenging. The drill may continuously slip leading to inaccurate implant position.⁶ Stephan *et al.*, 2013 reported that pre extraction tooth root guided osteotomy and implant bed preparation proves better alternative to counteract this clinical difficulty encountered during immediate implant placement in multirooted areas. Retained root complex serves as an ideal template for the emergence profile of the tooth to be replaced.

However, it is important to consider the tooth and remaining bone condition.⁷ The remaining root should have absence of active infections and favorable root position. Similarly, sufficient remaining bone (inter radicular, apical) should be available for immediate implant placement. If the bone conditions are not favorable and initial stabilization cannot be achieved, an augmentation procedure must be planned and the implant insertion must be done later.⁸

This technique may raise concern about the risk of a deleterious reaction caused by drill debris displaced in the socket or in the osteotomy. Therefore, it is recommended to thoroughly curette and debride the site prior to insertion of the implant. Care should be taken to remove all the existing endodontic filling material as the remnants of endodontic filling that can serve as local source of irritation.⁵ However, debris originating from tooth structure and tooth itself doesn't interfere with implant integration but rather involved in local bone turn over.⁹ The use of customized healing abutment in this case is to create an ideal emergence profile to guide soft tissue healing and positioning during the maturation process (Dual Zone concept Tarnow, Chu)¹⁰. Graft material helps serve as a scaffold to maintain hard- and soft-tissue volume as well as blood clot for initial healing. Adequate insertion torque and sufficient primary implant stability allowed for non- submerged healing in this case. This may be due to the support by the interradicular bone that was preserved in the lateral aspects of osteotomy and engagement of 2-3 mm of sound bone apically.

Conclusion

Immediate implant is widely used in today's clinical practice. Although there are standardized protocols and numerous studies describing the technique in the esthetic zone less information is available on immediate implant placement in multi root areas. The placement of immediate

implant in multirooted teeth is challenging. Thus, the pre extractive interradicular bed preparation allows a simple and guided implant placement using anatomy and geometry of roots and helps in ideal three-dimensional implant positioning.

References

1. Al-Sabbagh M, Kutkut A. Immediate implant placement: surgical techniques for prevention and management of complications. *Dent Clin*. 2015;59(1):73-95.
2. Rebele SF, Zühr O, Hürzeler MB. Pre-extractive interradicular implant bed preparation: case presentations of a novel approach to immediate implant placement at multirooted molar sites. *Int J Periodontics Restorative Dent*. 2013;33(1):89-96.
3. Fugazzotto PA. Implant placement at the time of mandibular molar extraction: Description of technique and preliminary results of 341 cases. *J Periodontol*. 2008;79(4):737-47.
4. Joshi DV, Suhag DV, Shalin D. report of two cases". *International Journal of Current Research Article History*. 2016.
5. Valenzuela S, Olivares JM, Weiss N, Benadof D. Immediate implant placement by interradicular bone drilling before molar extraction: clinical case report with one-year follow-up. *Case Rep Dent*. 2018; 2018:6412826.
6. Scarano A. Traditional Postextractive Implant Site Preparation Compared with Pre-extractive Interradicular Implant Bed Preparation in the Mandibular Molar Region, Using an Ultrasonic Device: A Randomized Pilot Study. *Int J Oral Maxillofac Implants*. 2017; 32(3):655-660.
7. Chen ST, Darby IB, Reynolds EC, Clement JG. Immediate implant placement postextraction without flap elevation. *J Periodontol*. 2009;80(1):163-72.
8. Rodriguez-Tizcareño MH, Bravo-Flores C. Anatomically guided implant site preparation technique at molar sites. *Implant Dent*. 2009;18(5):393-401.
9. Andreasen JO, Hjørtting-Hansen E. Replantation of teeth. II. Histological study of 22 replanted

- anterior teeth in humans. *Acta Odontologica Scandinavica*. 1966;24(3):287-306
10. Chu SJ, Salama MA, Salama H, Garber DA, Saito H, Sarnachiaro GO, Tarnow DP. The dual-zone therapeutic concept of managing immediate implant placement and provisional restoration in anterior extraction sockets. *Compend Contin Educ Dent*. 2012;33(7):524-32, 534.