

Stabilization Appliance for Masticatory Pain Secondary to Bruxism: A Case report

Paudel S¹, Suwal P², Singh RK³, Parajuli P⁴, Limbu IK⁵, Basnet BB⁶

¹PG Resident, Department of Prosthodontics, College of Dental Surgery, BPKIHS, Dharan, Nepal

²HOD and Professor, Department of Prosthodontics, College of Dental Surgery, BPKIHS, Dharan, Nepal

³Professor, Department of Prosthodontics, College of Dental Surgery, BPKIHS, Dharan, Nepal

⁴Associate Professor, Department of Prosthodontics, College of Dental Surgery, BPKIHS, Dharan, Nepal

^{5,6}Assistant Professor, Department of Prosthodontics, College of Dental Surgery, BPKIHS, Dharan, Nepal

Abstract

Occlusal appliance therapy is a proven modality for facilitating diagnosis and alleviating the pain related to different types of temporomandibular dysfunctions and obnoxious parafunctional habits such as bruxism and clenching. A properly fabricated occlusal appliance or splint serves the functions of relaxing the masticatory muscles, allowing the condyle to seat in centric relation, providing diagnostic information, protecting teeth and associated structures. The stabilization appliance has shown to decrease parafunctional activity thus considered when pain occurs due to muscle hyperactivity due to bruxism.

This case report highlights on the management of masticatory pain secondary to bruxism with stabilization appliance as an adjunct to other pharmacological and physical therapy. A heat cured acrylic stabilization appliance was fabricated and delivered to the patient which significantly reduced the pain within four weeks.

Key words: Bruxism; Occlusal Splint; Stabilization Appliance; Temporomandibular Dysfunction.

Introduction

An occlusal appliance can be a valuable diagnostic and treatment aid in carefully selected cases if properly made, adjusted and maintained. It provides a relatively easy, inexpensive and non-harmful way to make reversible changes in the occlusion¹.

The stabilization appliance is a hard-acrylic splint that is mostly efficacious for masticatory myalgia and temporomandibular joint (TMJ) arthralgia, especially if the pain is worse upon

awakening.² Such splints are designed to provide postural stabilization and to protect the TMJ, muscles and teeth³ and also to reduce symptoms from parafunctional activity associated with increased levels of emotional stress.⁴

A stabilization splint provides centric relation occlusion, eliminates posterior interference, provides anterior guidance and gives stable occlusal relationships with uniform tooth contacts throughout the dental arch.⁵ After a period of successful splint therapy (between 2 to 3 months), patients can be weaned off the splint.

Conflict of Interest: No

*Corresponding Author

Dr. Sandhya Paudel

PG Resident,

Department of Prosthodontics, College of Dental Surgery, BPKIHS, Dharan, Nepal

E-mail: paudelsandhya3@gmail.com

Case Description

A 42-year old female patient presented to the Department of Prosthodontics, CODS, BPKIHS with a complaint of pain in jaw during awakening for 3 months which had greatly affected her daily activities. There was no

history of trauma or recent dental changes and panoramic radiograph was unremarkable. Since her history revealed increased masticatory pain in the morning secondary to bruxism, a stabilization appliance was planned for night time use.

A set of diagnostic impressions of maxillary and mandibular arch were obtained with irreversible hydrocolloid (Coltoprint-NCR, Coltene). A facebow transfer with a Hanau spring bow (Fig.1) was done and maxillary cast was mounted to a semi-adjustable articulator (Hanau H2) Centric Relation (CR) bite record was obtained with a bite registration paste (Jet Bite, Coltene) to mount the mandibular cast (Fig.2). The peripheral extent of the appliance was outlined in pencil on the maxillary cast. The lingual border extended approximately 10 mm apical to the free gingival margins and the labial border terminated between the incisal and middle thirds of the anterior teeth (Fig. 3). Occlusal vertical dimension of the articulator was extended by extending the incisal pin downward. An interocclusal space of approximately 1.5 to 2.0 mm was achieved in the molar region of the cast to provide sufficient room for the anticipated thickness of the appliance. Next, two pieces of pink base plate wax (Pyrex Modelling Wax) were softened in hot water and adapted over the teeth of the maxillary cast and were extended up to the facial/buccal and palatal borders outlined previously. Imprints of mandibular tooth surfaces were obtained in the wax strip (Fig. 4). Sharp blade was used to remove excess wax until only the indentations of the functional (buccal) mandibular cusps remained.

Flattening and smoothing of the wax was done until solid CR contacts occurred bilaterally for every mandibular buccal cusp; solid CR marks were retained for as many incisors as

possible. At this point, all contacts were located in shallow wax depressions.

All protrusive, working and balancing interferences were detected and eliminated; being careful not to eliminate the blue CR dots. Also, all eccentric contacts made by the mandibular incisors were eliminated until the most prominent marks were those of the canines.

After smoothing all ridges and irregularities produced by centric closure and excursive movements, the wax pattern on the maxillary cast was invested and processed with clear, heat-polymerizing acrylic resin (Pyrax heat cure) in a manner similar to the way complete dentures are invested and processed (Fig. 5).

Following processing, intraoral adjustments were carried out (Fig. 6). The appliance was fitted comfortably and made adequately retentive. Lip and tongue movements did not unseat the appliance.

The following design features were incorporated during adjustment of splint:

- (1) All functional cusp tips contacted evenly and simultaneously in CR,
- (2) Only the mandibular canines contacted during canine-guided movements,
- (3) Mandibular canines and as many incisors as possible contacted during protrusive movement,
- (4) The stabilization appliance was stable during CR closure or any eccentric movement.

Within four weeks the patient reported a significant reduction in symptoms. Over the next three months she continued with the same treatment and reported a gradual decrease in her pain symptoms. The patient was also pharmacologically managed with NSAIDs and physical therapy.




Figure 1: Facebow record

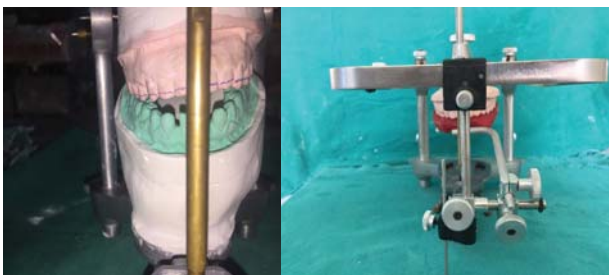


Figure 2: Transfer of the record to articulator

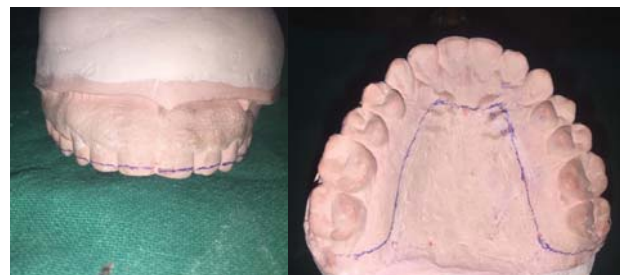

Figure 3: Marking of outline in cast

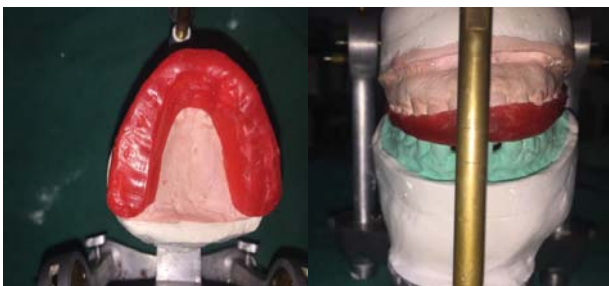

Figure 4: Adaptation of base plate wax to cast

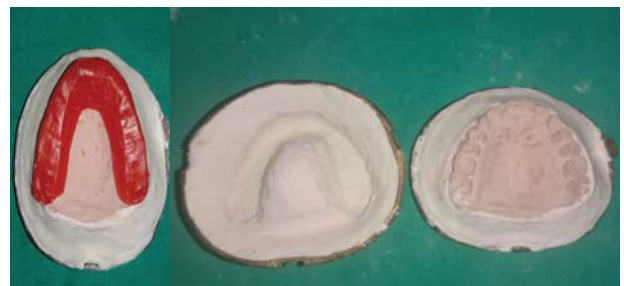

Figure 5: Processing of the appliance

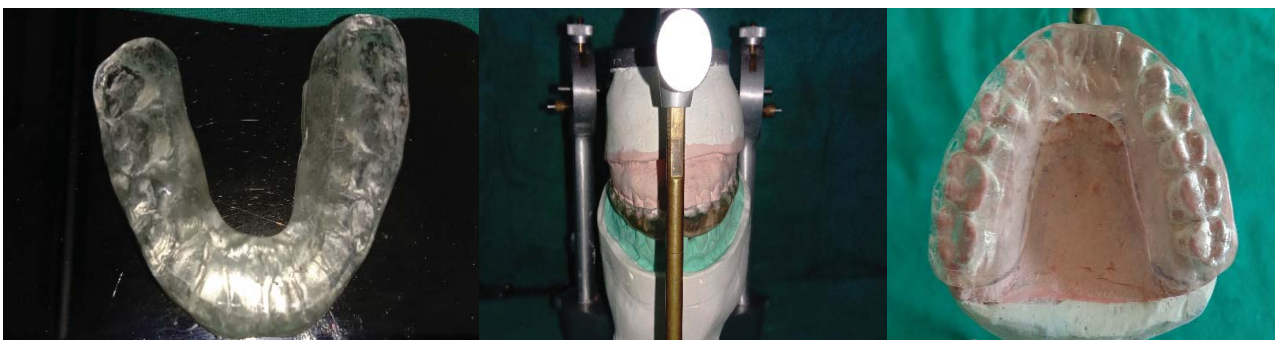


Figure 6: Finished appliance

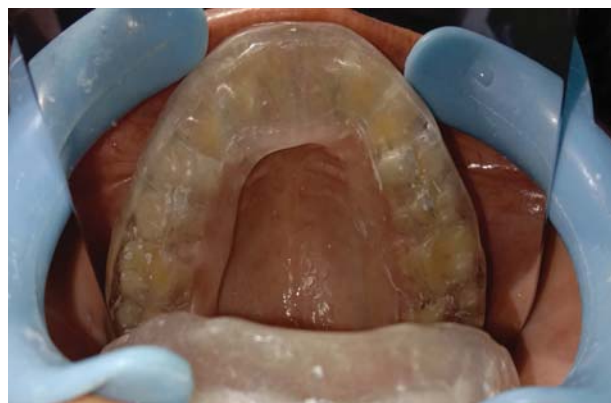
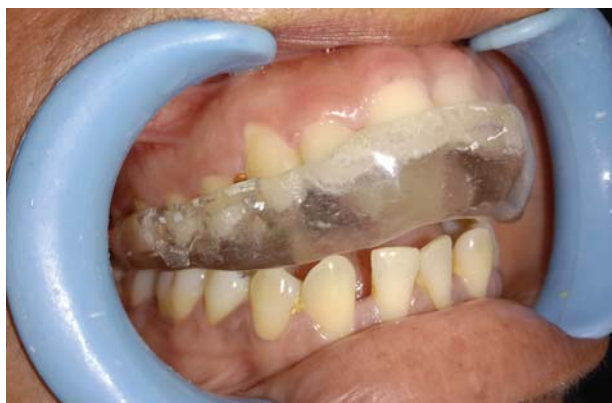
Figure 7: Intraoral photograph of the stabilization appliance

Discussion

There is almost complete consensus in the literature as to the remarkable effectivity of the stabilization appliance.^{2,7-11} Stabilization appliance are employed to provide a balanced function of the joint, protect the teeth, redistribute the forces applied to the jaws, relax the masticatory muscles and decrease the bruxism.^{7,8} The efficacy of occlusal appliances in managing localized masticatory myalgia, arthralgia or both has been sufficiently reported in the literature.² Lobbezoo et al showed a decrease in nocturnal muscle activity after insertion of stabilization splint.⁹

Ferrario VS¹⁰ stated that the splint reduced the electrical activity of the analyzed muscles and made it more equilibrated both between the left and the right side and between the temporal and the masseter muscles. Goldstein¹¹ stated that the splints were able to change the shape and function, however their outcomes could be more remarkable as to the painful symptomatology. Likewise, our patient also reported reduction in pain when stabilization appliance was used as an adjunct to temporomandibular dysfunction.

Conclusion

Some of the temporomandibular disorders may be treated with stabilization appliance and the best outcomes are related to total or partial

remission of the painful symptomatology and functional reestablishment. There is sufficient credible literature to support the use of splint therapy to reinstitute neuromuscular harmony in a compromised masticatory system. Dental practitioners have a responsibility to understand and provide this treatment, monitor the condition, and refer the patient to another practitioner if necessary.

References

1. Dylina TJ. A common sense approach to splint therapy. *J Prosthet Dent.* 2001;86:539-45.
2. Kreiner M, Betancor E, Clark GT. Occlusal stabilization appliance. Evidence of their efficacy. *J Am Dent Assoc.* 2001; 132:770-77.
3. Ash MM Jr. Current concepts in etiology, diagnosis and treatment of TMJ and muscle dysfunction. *J Oral Rehabil.* 1986;13:1-20.
4. Nelson SJ. Principles of stabilization of bite splint theory. *Dent Clin North Am.* 1995; 39:403-21.
5. Boero RP. The physiology of splint therapy: a literature review. *Angle Orthodontist.* 1989; 59:165-80.
6. Manns A, Miralles R, Santander H, Valdivia J. Influence of vertical dimension in the treatment of myofascial pain dysfunction syndrome. *J Prosthet Dent.* 1983; 50:700-09.
7. Okeson JP. Management of temporomandibular disorders and occlusion. 4th Edition. St. Louis: Mosby, 1998:509.

8. Dawson PE. Evaluation, diagnosis and treatment of occlusal problems. 2nd Edition. St. Louis: Mosby, 1989:186.
9. Lobbezoo F, Slater JJ R. Variation in masticatory muscle activity during subsequent, submaximal clenching efforts. J Oral Rehabil 2002; 29:504-09.
10. Ferrario VF, Sforza C, Tartaglia GM, Dellavia C. Immediate effect of a stabilization splint on masticatory muscle activity in temporomandibular disorder patients. J Oral Rehabil 2002; 29:810-15.
11. Goldstein BH. Temporomandibular disorders. A review of current understanding. Oral Surg Oral Med Oral Pathol Oral Radial Endod 1999; 88:379.