

Femoral artery Pseudo-aneurysm: Presentation, Causation and Outcome in Cardiothoracic Vascular and Transplant Centre of a Tertiary Level Hospital in Nepal

Bibhush Shrestha,¹ Anil Bhattarai,² Shiva Prasad Paudyal¹

¹Department of Cardiothoracic and Vascular Anesthesiology, ²Department of Cardiothoracic and Vascular Surgery, Tribhuvan University, Institute of Medicine, Maharajgunj, Kathmandu, Nepal.

Received: 25th April, 2024

Accepted: 24th May, 2024

Published: 10th June, 2024

ABSTRACT

Background: Peripheral arterial pseudo-aneurysms are of varied etiology and are quite common presenting from simple swelling to life threatening hemorrhage and sepsis. Our study aimed at evaluating our Institute's experience with femoral artery pseudo-aneurysm over a span of 2 years with particular focus on the various range of presentations, causative factors and management outcomes.

Methods: Retrospective analysis of medical records of patients with diagnosis of femoral arterial pseudo-aneurysm who underwent surgery was done. Data was collected retrospectively from Anesthesia and vascular surgery records as well as administrative records.

Results: Over the duration of 2 years we found a total of 135 cases of femoral artery pseudo-aneurysm treated in our center. Intravenous drug abuse (112) followed by catheter induced (11) was the commonest etiology. Demographics showed a propensity towards the youth with most cases in the 20-30 age group (78, 58%) followed by 30-40(35, 25%). A painful swelling with tenderness (91) was the commonest presentation. All patients underwent surgical treatment with 62 (45 %) patients undergoing ligation and the same numbers undergoing pseudo-aneurysm repair, 62(45%). 78(58%) patients had an uneventful recovery. However 18 cases had to undergo limb amputation and 7 patients lost their lives due to various complications.

Conclusion: Our study found that femoral artery pseudo-aneurysms present with various etiology and presentation, poses a huge challenge to the clinicians for surgery and management of its complications.

Keywords: vascular disease; femoral artery pseudo-aneurysm; IV drug abuse; Nepal.

INTRODUCTION

A pseudo-aneurysm (or false aneurysm) is a hematoma that communicates with an artery through a disruption in the arterial wall. The common causes of pseudo-aneurysm are intravenous drug abuse (IVDA), iatrogenic due to diagnostic and therapeutic vascular interventions or a vascular anastomotic disruption, trauma, and infection.¹⁻³ Clinically, it may present with pulsatile hematoma, pain, discharge or with active extravasation/hemorrhage. Intermittent claudication, amputation of the limb, sepsis and death are the complications. Several management options are in practice like injection of thrombin into the sac of pseudo-aneurysm, open repair/ aneurysmorrhaphy, excision and debridement of infected tissue, excision and ligation of affected artery and revascularization. The principle of surgery are adequate debridement of necrotic tissue, control of hemorrhage and pres-

ervation of distal circulation whenever possible. In absence of timely intervention, femoral pseudo-aneurysms can lead to loss of limbs and be fatal secondary to septicemia and exsanguinations.⁴ Irrespective of treatment options, high index of suspicion, timely diagnosis and intervention is the key to good outcome.

METHOD

Our study was a retrospective observational study covering the period from 15th March 2022 to 14th March 2024 in our center which is the only tertiary level Cardiothoracic Vascular and Transplant Center in Nepal. After achieving approval from the institutional review committee, Vascular surgery records, anesthesia OT records and administrative records of patients who presented with femoral artery pseudo-aneurysms due various etiologies were reviewed. Data regarding demography, age, gender, presenta-

Correspondence: Dr. Shiva Prasad Paudyal, Department of Cardiothoracic & Vascular Anesthesiology, TU, IOM, Maharajgunj, Kathmandu, Nepal. Email: shivapd.yl@gmail.com, Phone: +977-9860178205.

tion, surgical management, complications within the days of hospital stay and outcome was analyzed.

RESULTS

A total of 135 patients were included in this study. 90.4 % (122) of the patients were male and 58% (78) comprised of those in the 20-30 age group (Figure 1).

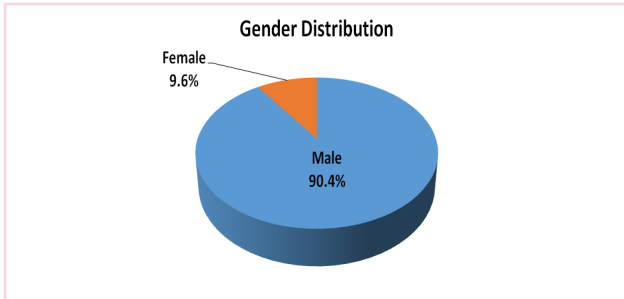


Figure 1. Gender distribution.

Table 1. Age-Gender Distribution.

| Gender | Age (years) | | | | Mean±SD |
|-------------|-------------|-------|-------|-----|-----------|
| | <20 | 20-30 | 30-40 | >40 | |
| Female | 0 | 6 | 1 | 6 | 40±20 |
| Male | 1 | 72 | 34 | 15 | 32.6±11.3 |
| Total (135) | 1 | 78 | 35 | 21 | 31.9±12.1 |

Etiology: One hundred and twelve (83%) of those pseudo-aneurysm were caused due to IV drug abuse. Another 11(8%) patients developed pseudo-aneurysm due to catheter and interventional vascular procedures while 7(5%) patients had traumatic etiology (Figure 2).

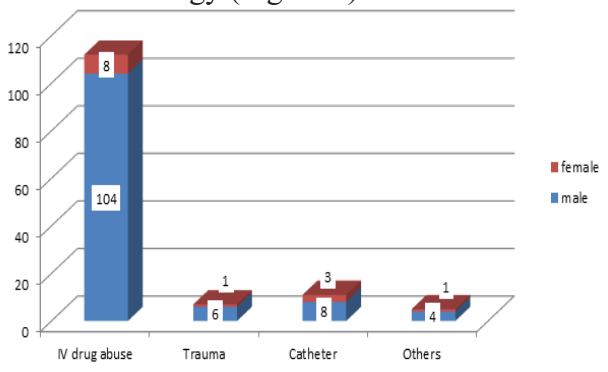


Figure 2. Etiology.

Presentation: Most common presentation among femoral artery pseudo-aneurysm patients was painful/tender swelling over the groin area(65%), followed closely by the complaints of a pulsatile mass(57%). Among other presentations hemorrhage with shock was present among 16% of the patients while infect-

ed swelling was the presentation among 31% patients (Table 2).

| Presentations | Frequency(%) |
|------------------------|--------------|
| Painful swelling | 91(65) |
| Pulsatile mass | 78(57) |
| Oozing mass | 41(30) |
| Frank hemorrhage | 30(22) |
| Pus discharge | 42(31) |
| Ulcers | 25(18) |
| Sepsis | 18(13) |
| Hemorrhage with shock | 22(16) |
| Limb claudication | 9(6) |
| Severe limb pain | 20(14) |
| Limb ischemia/gangrene | 11(8) |

Also, 94 (70%) of the cases were treated with emergency surgery while 41(30%) were treated electively (Figure 3).

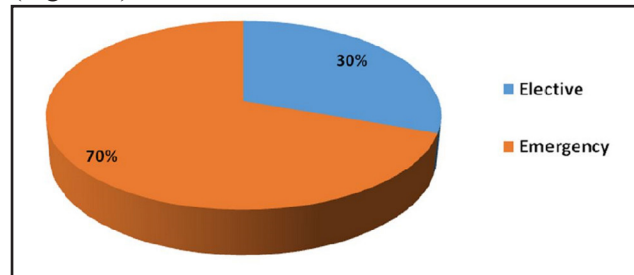


Figure 3. Timing of surgery.

Intervention: In our study 62(46%) patients were intervened with either open aneurysm repair and further 61(45%) patients with ligation of the vessel with debridement. Remaining 12 patients(9%) either underwent coiling, PTFE grafting, bypass or limb amputation (Figure 4).

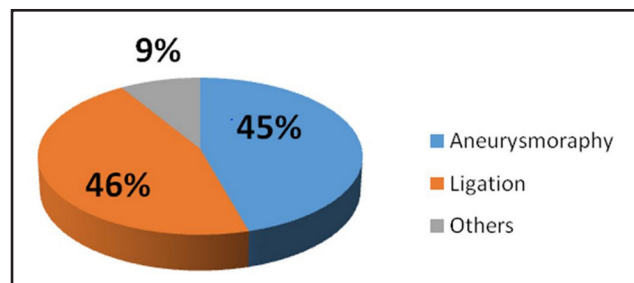


Figure 4. Modalities of surgery.

Outcome:78 (58%) patients had an uneventful recovery after intervention however 38(28%) of the patients developed wound infection, 18 patients (13%) had to undergo amputation of the limb involved. 21

patients had to undergo debridement while 17 patients underwent re-exploration due to persistent bleeding. 8 patients developed claudication, 2 cases were treated with bypass after ligation initially, 7 cases developed sepsis and septic shock and died due to various complication (Table 3).

| Outcomes | Frequency(%) |
|-----------------------------|---------------------|
| amputation | 18(13) |
| bleeding and re-exploration | 17(12) |
| bypass | 2(1) |
| claudication | 8(6) |
| debridement | 21(15) |
| mortality | 7(5) |
| sepsis | 12(9) |
| uneventful recovery | 78(58) |
| wound infection | 38(28) |

DISCUSSION

Our study aimed at studying the etiology, incidence and outcomes among the patients presenting to our center with femoral artery pseudo-aneurysm. But it has also revealed a lot more than that we have aimed for. Over the two years our study has reviewed, the incidence of femoral artery pseudo-aneurysm is found to be higher than that of most other centers who have conducted such studies.^{1,5,6} This can be attributed to our Center being the only vascular center of the country. And thus the referral center for every vascular pathology and emergency. In our study, most of the patients were males aged between 20-30 years. Contemporary studies among the south-asian population also have shown similar results.^{1,6} Highest number of patients presenting at our center presented with an etiology of long term intravenous drug abuse. The age group and the etiology point us towards the glaring problem of drug abuse among the youth in our society. Femoral artery because of its easy access and proximity to the femoral vein, is the commonest puncture site among drug abusers. Femoral artery is also the most commonest endovascular access site. This has led to high incidence of femoral artery pseudo-aneurysm.^{1,5,7,8} Most patients with femoral artery pseudo-aneurysms present with tender/painful

mass over the groin or a pulsatile swelling.^{1,3,5} Patients in our center are referred from various cities of Nepal. Due to referral delay or transportation they usually present late with signs/ symptoms of limb ischemia, infection, shock and sepsis. This also explains the frequency of complications pre or post-operatively including hemorrhage, anemia, limb amputations, sepsis and mortality. The treatment /surgical modality of treatment for femoral artery pseudo-aneurysms depends upon the etiology and presentation. Surgical repair is the management of choice however late presentation and infection hinder the chances of performing a primary repair. Ligation of the vessel with debridement/excision of the pseudo-aneurysm puts the limb at risk of ischemia, but collateral circulation is generally present or develops in these patients.⁹ In our study both modalities of treatment had equal frequencies(45% each). Two of the patients after debridement underwent revascularization with bypass surgeries. Coiling and endovascular intervention and ultrasonographic compression are few other modalities of treatment. Our study showed a limb amputation among 18 of the patients which is a high number as compared to contemporary studies.^{2,10} Late presentation and infection are the major factors that hinder early revascularization in those with ligation leading to limb ischemia and amputation. Complications included bleeding and re-exploration, debridement, infection and claudication which are similar in incidence with data from other tertiary centres.^{1,3,5,10} There are several limitations of our study. Clinical data regarding biochemistry findings, hemorrhage and hemoglobin levels, other comorbidities etc are missing. Further research and studies in this regard is warranted.

CONCLUSION

Femoral artery pseudo-aneurysms present with unique challenge to the clinicians in terms of presentation, etiology, optimal treatment/surgery and complications that can even be fatal. However, timely diagnosis and intervention can save limb and life of the patient with minimal complications. 83% of the patients were IV drug abusers and was the commonest etiology. Treatment with

ligation or primary repair both bore good outcomes. Late presentation, infection and sepsis are few factors that hamper the outcomes leading to loss of limb and mortality. Even with a large burden of such patients presenting late with multiple complications in our center, the only tertiary

level vascular center in Nepal, the outcomes are more promising.

Conflict of interest: None

REFERENCE

1. Luther A, Kumar A, Negi KN. Peripheral Arterial Pseudoaneurysms-a 10-Year Clinical Study. *Indian J Surg.* 2015;77(Suppl 2):603-7.
2. Al Shakarchi J, Wall M, Garnham A, Hobbs S, Newman J. Artery Ligation for Infected Femoral Pseudoaneurysms Does Carry a High Risk of Major Amputation. *Ann Vasc Surg.* 2019;58:326-30.
3. Samarakoon LB, Ho DCY, Tan YK, Kum SWC, Lim DM. Infected femoral pseudoaneurysms in intravenous drug abusers: a decade of experience from a Singapore tertiary centre. *Singapore Med J.* 2021;62(3):135-8.
4. Ilic A, Stevanovic K, Pejkić S, Marković M, Dimić A, Sladojević M, Davidović L. Vascular Injuries in Intravenous Drug Addicts-A Single-Center Experience. *Ann Vasc Surg.* 2020;67:185-91.
5. Schlegel RN, Clements W, Koukounaras J, Goh GS, Joseph T, Phan T, Moriarty HK. A 10-year retrospective review of management and outcomes of pseudoaneurysms at a tertiary referral centre. *J Med Imaging Radiat Oncol.* 2022;66(5):603-8.
6. Darbari A, Tandon S, Chandra G, Dwivedi SK, Kumar A, Gupta A. Post-traumatic peripheral arterial pseudoaneurysms: Our experience. *Indian Journal of Thoracic and Cardiovascular Surgery.* 2006;22(3):182-7.
7. Mohammadzadeh MA, Hossain-Akbar M, Ejtemaee-Mehr S. Vascular lesions in intravascular drug abusers in Guilan, north of Iran. *Arch Iran Med.* 2007;10(4):522-4.
8. Reddy DJ. Treatment of drug-related infected false aneurysm of the femoral artery--is routine revascularization justified? *J Vasc Surg.* 1988;8(3):344-5.
9. Arora S, Weber MA, Fox CJ, Neville R, Lidor A, Sidawy AN. Common femoral artery ligation and local debridement: a safe treatment for infected femoral artery pseudoaneurysms. *J Vasc Surg.* 2001;33(5):990-3.
10. NU DD, Berlas FT, Rehman KU, Ali G, Salahuddin F, Mumtaz A. Outcomes of Femoral Artery Pseudoaneurysm in Intravenous Drug Abusers Managed at a Tertiary Care Center. *Cureus.* 2021;13(2):e13350.

Citation: Shrestha B, Paudyal SP, Bhattarai A. Femoral artery Pseudo-aneurysm: Presentation, Causation and Outcome in Cardiothoracic Vascular and Transplant Centre of a Tertiary Level Hospital in Nepal. *JNHLS.* 2024; 3(1):22-25.