

# Transcatheter Aortic Valve Implantation (TAVI) In Small Island Nation- Maldives, Leading Cardiac Care to A Higher Standard

Kaushal Kishore Tiwari,<sup>1</sup> Mohamed Shafiu,<sup>1</sup> Murari Barakoti,<sup>2</sup> Ashish Kumar Nema,<sup>2</sup> Athul Suresh Kumar,<sup>1</sup> Dusooma Abdul Razzag,<sup>3</sup> Diwas Manandhar,<sup>3</sup> Sai Satish<sup>4</sup>

<sup>1</sup>Department of Cardiothoracic and Vascular Surgery, ADK Hospital Pvt. Ltd. Male, Republic of Maldives, <sup>2</sup>Department of Cardiology, ADK Hospital Pvt. Ltd. Male, Republic of Maldives, <sup>3</sup>Department of Anesthesiology, ADK Hospital Pvt. Ltd. Male, Republic of Maldives, <sup>4</sup>Department of Cardiology, Apollo Hospital Group, Chennai, India.

Received: 23<sup>rd</sup> March, 2023

Accepted: 4<sup>th</sup> May, 2024

Published: 10<sup>th</sup> June, 2024

## ABSTRACT

**Background:** Surgical aortic valve replacement is still considered the preferred treatment option for patients with severe aortic valve stenosis, and it is known to improve the survival of the patients. However, about 30-50% of patients are not operated on due to several reasons including old age, high risk and other comorbidities. Transcatheter Aortic Valve Implantation (TAVI) is emerging as an alternative treatment option for elderly patients with high surgical risk.

**Methods:** In our study, four patients have undergone TAVI from February 2022 till May 2023 using Medtronic Transcatheter Aortic Valve, Core valve Evolut R (Medtronic Inc., Minneapolis, MN, USA) bioprosthesis.

**Results:** All the patients were discharged early. Follow-up Echocardiography showed decreased transaortic gradient with improved quality of life.

**Conclusion:** We conclude, implementation and use of this emerging technology in small Island Nations like Maldives would help to treat many patients, mostly elderly and high-risk as well as patients with intermediate risk requiring aortic valve surgery with less morbidity and comparable mortality in comparison to SAVR.

**Keywords:** aortic stenosis; transcatheter aortic valve implantation; small island nation.

## INTRODUCTION

The incidence of degenerative valvular heart disease is increasing due to an increase in overall life expectancy all over the world. Aortic stenosis, in particular, is being detected more often leading to increased cardiovascular morbidity and mortality.<sup>1</sup> Surgical aortic valve replacement is still considered the preferred treatment option for patients with severe aortic valve stenosis and it is known to improve the survival of the patients.<sup>2</sup> Several studies have reported surgery could achieve an acceptable 30 days mortality (2.8%). However, about 30-50% of patients are not operated on due to several reasons including old age, high risk and other comorbidities.<sup>3</sup> Transcatheter Aortic Valve Implantation (TAVI) is emerging as an alternative treatment option for elderly patients with high surgical risk. The first successful TAVI was performed by Alain Cribier and his team in France in 2002.<sup>4</sup> Currently, about 100000

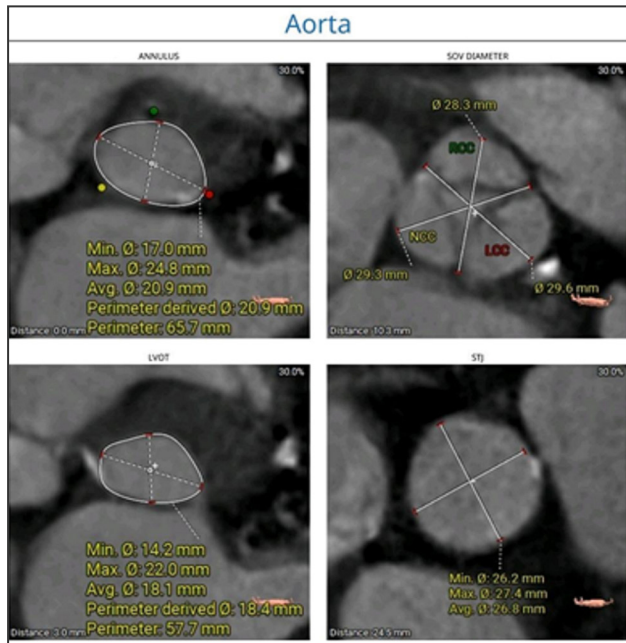
TAVI cases per year are performed worldwide and evidence suggests its indication and use will expand in the near future. Cardiac surgery services started on 8<sup>th</sup> August 2018 in Maldives at the ADK hospital Pvt. Ltd.. It is at the toddler stage in the Maldives. Since then, 255 open-heart surgeries have been performed. Out of it, 53 Aortic valve surgeries are being performed. Many aortic stenosis patients referred to us for surgical treatment are elderly, with several comorbidities putting them in the high-risk group. So, we decided to start the TAVI program as an alternative armamentarium for the patient who otherwise couldn't undergo aortic valve replacement.

## METHOD

Four patients have undergone TAVI since February 2022 till May 2023 who have presented to our department of Cardiothoracic and Vascular Surgery for surgical management with a diagnosis of degenerative valvular heart disease, severe aortic regurgitation and

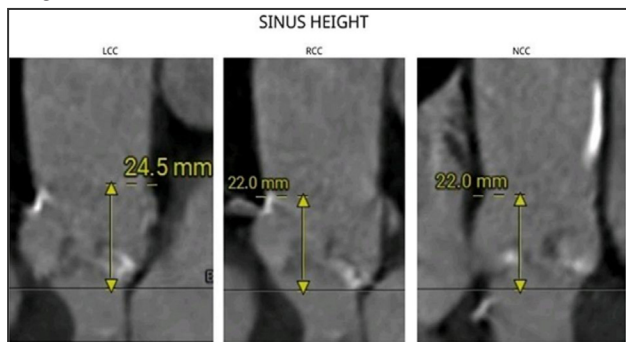
**Correspondence:** Dr. Kaushal Kishore Tiwari, Department of Cardiothoracic and Vascular Surgery, ADK Hospital Pvt. Ltd. Male, Republic of Maldives. Email: drkaushalkt@yahoo.com, Phone: +9609421623.

stenosis. Patients' demographic data and preoperative echocardiography findings are presented in (Table 1) Preoperatively, CT aortography was obtained using



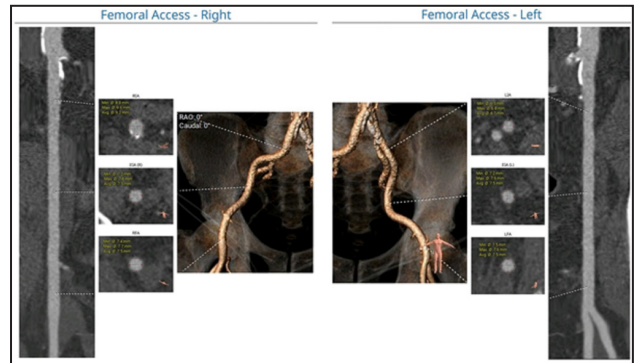
**Figure 1. Mean Aortic annulus diameter, mean aortic annulus perimeter, annulus area, sinus of Valsalva mean diameter calculation.**

the TAVI protocol. Mean Aortic annulus diameter, mean aortic annulus perimeter, annulus area, sinus of Valsalva mean diameter (Figure 1), sinus of Valsalva height, the height of right and left coronary ostias (Figure 2), average right and left common iliac, external iliac and femoral artery diameter were calculated (Figure 3).

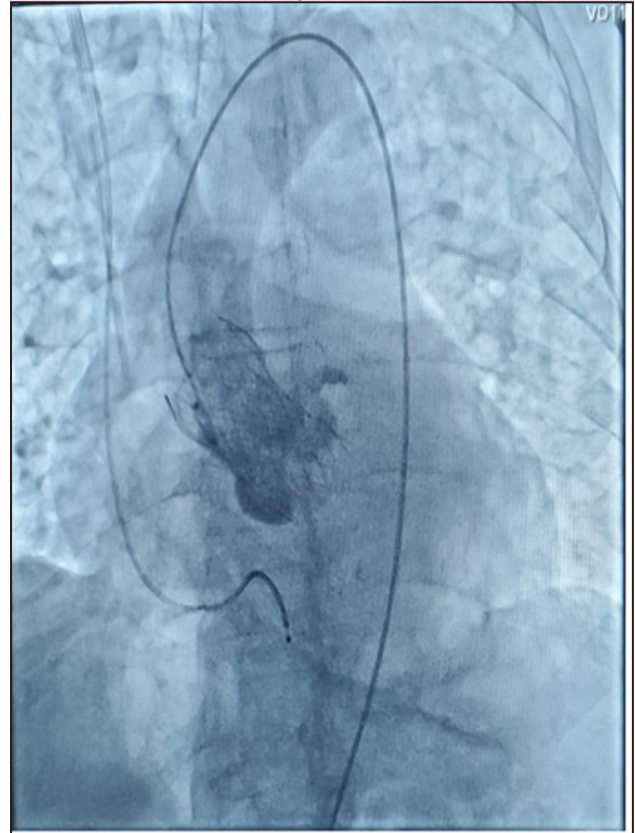

**Figure 2. Sinus of Valsalva height, the height of right and left coronary ostias measurement.**

On the basis of CT aortography analysis, the size of the aortic valve was decided. TAVI procedure was performed in the Hybrid operating room with the stand-by cardiopulmonary bypass machine in the operative



**Figure 3. Right and left common iliac, external iliac and femoral artery diameter measurement.**



**Figure 4. Post implantation fluoroscopy.**



**Figure 5. Heart Team after successful TAVI for the first time in the Maldives.**

room. All patients underwent the procedure under general anaesthesia. Transesophageal Echocardiography (TEE) is used during the surgery to monitor intraoperative and postoperative heart function. In the first case, both the right and left Femoral arteries were cannulated transcutaneously. In the three consecutive cases, the right Femoral artery was exposed surgically. Left Radial artery cannulated for continuous arterial pressure monitoring. A 5F balloon-tipped temporary pacemaker wire was introduced to the right ventricle through the right Internal Jugular vein using a 6F sheath. Systemic heparinization has been done. Standard procedural protocol followed as per the manufacturer's guideline. In particular, The right Femoral artery was dilated and an 18F Sentrant™ (Medtronic Inc., Minneapolis, MN, USA) introducer sheath with hydrophilic coating was inserted. Left Femoral artery cannulated using 7F sheath. A 5F pigtail catheter is advanced up to the NCC through the left Femoral artery via a 7F sheath. The aortic valve crossed with an AL-1 6F catheter through the right Femoral artery to the left ventricle (LV) using Teflon straight-tip guidewire. After the successful crossing of the valve, exchange length J tip Teflon wire was inserted and exchanged with a 6F pigtail catheter. Peak-to-peak pressure gradient was recorded. A pre-shaped stiff Confida wire (Confida™ Brecker, Medtronic, Inc., Minneapolis, MN, USA) was placed into the LV cavity after confirming that it is free from the mitral valve apparatus. In all the cases Medtronic Transcatheter Aortic Valve, Core valve Evolut R (Medtronic Inc., Minneapolis, MN, USA) bioprosthesis of 29 mm (20% oversizing) is prepared in the introducer and delivery system EnVeo Pro Delivery catheter system. The valve passed to the aortic position, positioned at about 5 mm below NCC. Ascending aortogram was taken with the injector and after satisfactory implant depth, the valve was deployed under rapid Ventricular pacing up to 180 bpm at the aortic position approximately 5 mm below NCC. Aortic Valve correct positioning confirmed (Image 4). Post-implant aortogram revealed an excellent valve implant depth of 5 mm, coaxial, well expanded with no gradient, trace paravalvular regurgitation and no conduction abnor-

mality. Intraoperative TEE confirmed the findings. In one case, post-device deployment, moderated paravalvular regurgitation was detected, so post-dilation of the valve was done with a Tyshak II 22 x 50 mm balloon. Immediate TEE showed minimal paravalvular leak. The pigtail catheter and LV catheter were removed. Femoral sheaths removed. The right Femoral artery closed with two suture-mediated closure devices (Perclose ProGlide®, Abbott Laboratories, Abbott Park, IL), which were deployed at 2 and 10 o'clock positions in the first case and by direct surgical closure using purse string in three consecutive cases. Protamine given. Hemostasis controlled.

## RESULTS

All the patients were extubated on the table and shifted to the CCU with stable hemodynamics. There were no vascular complications, cardiac events or infections in the postoperative period. Two patients were discharged on the 3<sup>rd</sup> postoperative day, one patient was discharged on the 5<sup>th</sup> postoperative day due to diabetes management. At the one-month follow-up all patients were improved, asymptomatic, and with a mean gradient of  $10.76 \pm 3.26$  mmHg.

Characteristics	Values
Age	82.25±2.16 years
Male:Female	3:01
Diabetes	4
HTN	4
Dislipidemia	4
Chronic Renal Failure	1
Mean Aortic Gradient	48.25±4.81 mmHg

## DISCUSSION

Timely surgery for severe aortic stenosis improves the quality of life and decreases mortality<sup>5</sup>. Surgical aortic valve replacement is performed for decades with minimal risk of mortality and morbidity in patients with mild to moderate risk factors. To be precise, AVR carries an average 30-day mortality of 1-3%.<sup>6</sup> However, elderly patients with multiple comorbidities fall into the high-risk category,

increasing surgical mortality up to 5-10 times higher.<sup>7,8</sup> An alternative method of treatment for these high-risk patients is welcomed. Since its first use in 2002, TAVI has become an acceptable alternative method of treatment for patients otherwise inoperable due to higher mortality.<sup>9</sup> Furthermore, recent advances in techniques and minimalization of the procedure (Single arterial cannulation)<sup>10</sup> in several studies have shown similar results in younger and low-risk patients leading to changes in the current guidelines for TAVI.<sup>11</sup> Approximately 2-4% of adults aged >65 years living in developed countries are affected with calcific aortic stenosis.<sup>12</sup> Surgical aortic valve replacement (SAVR) was previously the only option available to patients with symptomatic, severe aortic stenosis, without which a median survival of ~2 years was to be expected.<sup>13,14</sup> However, one-third of these patients have traditionally not undergone SAVR due to high surgical risk.<sup>15</sup> So, most of our high-risk patients are managed medically. Unfortunately, medical management of these patients has been universally futile, and although diuretic therapy can temporarily relieve symptoms, they have not been shown to affect the natural history of the disease and overall prognosis. In past, balloon aortic valvuloplasty (BAV) has been similarly effective in providing temporary symptom relief in these patients, but it has high rates of rapid restenosis and a lack of improvement in survival, and therefore it has merely a palliative role.<sup>16,17</sup>

Careful preprocedural planning is required for a successful TAVI procedure. CT aortography has proved to be helpful in preprocedural planning by assessing the optimal method of access; defining anatomic relationships between the aortic valve, root, left ventricle, and coronary Ostia; choosing the optimal device size; and, lastly, contributing to the procedural plan.<sup>18</sup> Moreover, the use of recently developed sophisticated 3D software (FEops HEART Guide™, Gent, Belgium), which can simulate procedural outcomes such as the severity of the paravalvular leak and the need for pacemaker (PPM) implantation will further help to improve TAVI outcome.<sup>19</sup>

Evidently, in patients undergoing TAVI, improvements in clinical endpoints like 30 days mortality rate,

life-threatening bleeding and strokes, reduced from 7.2% to 2.5%, 6.3% to 1.8% and 2.1% to 1.6%, respectively.<sup>20</sup>

However, despite the tremendous reduction in mortality with the use of TAVI, 1-year mortality is still high in these patients, emphasizing the importance of patient selection when determining which patients might have comorbid conditions that would preclude any benefit from TAVI.<sup>21</sup>

There are several Transcatheter heart valves available in the market, specifically self-expanding and balloon inflatable. All have their pros and cons. In all our four cases, we have used Medtronic Transcatheter Aortic Valve, Core valve EvolutR (Medtronic USA) bioprosthesis. This is a self-expanding fully retrievable valve during the procedure until the introducer catheter is not released from the valve. For the success of a TAVI program, continuation and mastering one type of valve are advised before shifting to another.

The use of TAVI has been started in several south Asian countries like India, Nepal, Bangladesh and Srilanka. Use of TAVI in small Island nations is still limited due to the higher cost of the valves, unavailability of the prosthesis and lack of manpower to perform.

At a first glance, the overall cost of TAVI looks higher due to the higher cost of the valves and consumables. However, a cost-effectiveness analysis in the PARTNER trial showed that TAVI was similar to SAVR for 12-month costs and quality-adjusted life-years, and transfemoral TAVI was even economically superior, despite the high costs associated with the TAVI devices.<sup>22</sup> Fortunately, in our case, the higher cost of the TAVI couldn't be a hurdle to starting the program because healthcare cost has been covered by the national insurance scheme "Aashandha" plus National Social Protection Agency (NSPA) in the Maldives.

In the majority of the centres around the world, TAVI has been performed by interventional cardiologists. Importantly, it is mandatory to perform TAVI in a centre with cardiac surgery facilities to avoid fatal complications during the procedure. Subsequently,

in our case, TAVIs have been performed by cardiac surgeons under supervision of an official proctor in collaboration with the cardiologist as a part of the heart team approach (Figure 5).

## CONCLUSION

TAVI is emerging as the treatment of choice for most patients with severe symptomatic AS. Implementation

and use of this emerging technology in small Island Nations like Maldives would help to treat many patients, mostly elderly and high-risk as well as patients with intermediate risk requiring aortic valve surgery with less morbidity and comparable mortality in comparison to SAVR.

**Conflict of interest:** None

## REFERENCE

1. Nkomo VT, Gardin JM, Skelton TN, Gottdiener JS, Scott CG, Enriquez-Sarano M. Burden of valvular heart diseases: a population-based study. *Lancet*. 2006;368:1005–11.
2. Lund O. Preoperative risk evaluation and stratification of long term survival after valve replacement for aortic stenosis: reasons for earlier operative intervention. *Circulation*. 1990;82:124–39.
3. Frey N, Steeds RP, Rudolph TK, Thambyrajah J, Serra A, Schulz E, et al. Symptoms, disease severity and treatment of adults with a new diagnosis of severe aortic stenosis. *Heart*. 2019;105(22):1709–16.
4. Cribier A, Eltchaninoff H, Bash A, Borenstein N, Bauer F, Derumeaux G, et al. Percutaneous transcatheter implantation of an aortic valve prosthesis for calcific aortic stenosis: first human case description. *Circulation*. 2002;106:3006–8.
5. K Vidal P, Bergström R, Hörte LG, Ståhle E. Observed and relative survival after aortic valve replacement. *J Am Coll Cardiol* 2000; 35: 747-56. 10.1016/s0735-1097(99)00584-7
6. Schwarz F BP, Manthey J, Hoffmann M, Schuler G, Mehmel HC, Schmitz W, Kübler W. The effect of aortic valve replacement on survival. *Circulation*. 1982;66:1105-1110. 10.1161/01.cir.66.5.1105
7. Gehlot A, Mullany CJ, Ilstrup D, Schaff HV, Orzulak TA, Morris JJ, et al. Aortic valve replacement in patients aged eighty years and older: early and long-term results. *J Thorac Cardiovasc Surg* 1996; 111: 1026-36. 10.1016/s0022-5223(96)70379-3
8. Lung B, Baron G, Messika-Zeitoun D, Delahaye F, Tornos P, Gohlke-Barwolf C, Boersma E, Ravaud P, Vahanian A. Decision-making in elderly patients with severe aortic stenosis: Why are so many denied surgery? *Eur Heart J*. 2005;26:2714-2720. 10.1093/eurheartj/ehi471
9. Makkar RR, Jilaihawi H, Kapadia S, Pichard AD, Douglas PS, Thourani VH, Webb JG, Herrmann HC, Bavaria JE, Kodali S, Brown DL, Bowers B DT, Svensson LG, Tuzcu M, Moses JW, Williams MR, Siegel RJ, Akin JJ, Pocock S, Smith CR, Leon MB; PARTNER Trial Investigators. Transcatheter aortic-valve replacement for inoperable severe aortic stenosis. *N Engl J Med*. 2012;366:1696-1704. 10.1056/NEJMoa1202277
10. Aroney NP, Patterson T, Kalogeropoulos A, Allen CJ, Hurrell H, Chehab O, et al. Clinical outcomes following single access transfemoral transcatheter aortic valve implantation. *Catheter Cardiovasc Interv*. (2022) 100:227–32. 10.1002/ccd.30246
11. Vahanian A, Beyersdorf F, Praz F, Milojevic M, Baldus S, Bauersachs J, et al. 2021 ESC/EACTS Guidelines for the management of valvular heart disease. *Eur J Cardiothorac Surg*. (2021) 60:727–800.
12. Freeman, R. V. & Otto, C. M. Spectrum of calcific aortic valve disease: pathogenesis, disease progression, and treatment strategies. *Circulation* 111, 3316–3326 (2005).
13. Nishimura, R. A. et al. 2014AHA/ACC guideline for the management of patients with valvular

- heart disease: a report of the American College of Cardiology/American Heart Association task force on practice guidelines. *J. Am. Coll. Cardiol.* 63, e57–e185 (2014).
14. Ross, J. Jr & Braunwald, E. Aortic stenosis. *Circulation* 38, 61–67 (1968).
  15. Iung, B. et al. Decision-making in elderly patients with severe aortic stenosis: why are so many denied surgery? *Eur. Heart J.* 26, 2714–2720 (2005).
  16. O'Neill, W. W. Predictors of long-term survival after percutaneous aortic valvuloplasty: report of the
  17. Kapadia, S. et al. Outcomes of inoperable symptomatic aortic stenosis patients not undergoing aortic valve replacement: insight into the impact of balloon aortic valvuloplasty from the PARTNER trial (Placement of AoRtic TraNscathetER Valve trial). *JACC Cardiovasc. Interv.* 8, 324–333 (2015).
  18. Nahar S, Momenuzzaman AM, Kabir J, Begum F, Khan KN, Ahmed MI, Ahmad T, Shakil SS. Transcatheter Aortic Valve Implantation (TAVI): First Case in. Bangladesh. *Mymensingh Med J* 2019 ; 28 (1):250-3.PMID: 30755578
  19. El Faquir N, De Backer O, Bosmans J, Rudolph T, Buzzatti N, Bieliauskas G, et al. Patient-specific computer simulation in TAVR with the self-expanding evolut R valve. *JACC Cardiovasc Interv.* (2020) 13:1803–12
  20. Carroll J.D., Mack M.J., Vemulapalli S., Herrmann H.C., Gleason T.G., Hanzel G., Deeb G.M., Thourani V.H., Cohen D.J., Desai N., et al. STS-ACC TVT Registry of Transcatheter Aortic Valve Replacement. *J. Am. Coll. Cardiol.* 2020;76:2492–2516. doi: 10.1016/j.jacc.2020.09.595.
  21. Jones BM, Krishnaswamy A, Tuzcu EM, Mick S, Jaber WA, Svesson LG, Kapadia SR. Matching patients with the ever-expanding range of TAVI devices. *Nat Rev Cardiol* 2017 Oct;14(10):615-626. doi: 10.1038/nrcardio.2017.82.
  22. Reynolds, M. R. et al. Cost-effectiveness of transcatheter aortic valve replacement compared with surgical aortic valve replacement in high-risk patients with severe aortic stenosis: results of the PARTNER (Placement of Aortic Transcatheter Valves) trial (Cohort A). *J. Am. Coll. Cardiol.* 60, 2683–2692 (2012).

**Citation:** Tiwari KK, Shafiu M, Barakoti M, Nema AK, Suresh KA, Razzag DA, Manandhar D, Satish S. Transcatheter Aortic Valve Implantation (TAVI) In Small Island Nation- Maldives, Leading Cardiac Care to A Higher Standard. *JNHLS.* 2024; 3(1):01-06.