

Marfan's Syndrome with Rhegmatogenous Retinal Detachment: A Case ReportKumдини Subedi,^{1*} Parchi Dulal,¹ Sangita Pradhan,¹ Raghunanadan Byanju²¹ Bharatpur Eye Hospital, Bharatpur-10, Chitwan, Nepal² Department of Ophthalmology, KIST Medical College and Teaching Hospital, Kathmandu, Nepal.**Received:** 16th January, 2023**Accepted:** 28th March, 2023**Published:** 30th June, 2023**DOI:** 10.3126/jnhls.v2i1.56212**Correspondence:**

*Dr. Kumдини Subedi, Bharatpur Eye Hospital, Bharatpur-10, Chitwan

Email: subedikumu@gmail.com

Phone: +977-9845100057.

Citation: Subedi K, Dulal P, Pradhan S, Byanju R. Marfan's Syndrome with Rhegmatogenous Retinal Detachment: A Case Report, JNHLS. 2023; 2(1):44-48.**ABSTRACT**

Background: Marfan's syndrome is known to be a rare, multisystem disorder of connective tissue typically affecting cardiac, skeletal and ocular system. The only definitive diagnosis is by gene testing for autosomal dominant mutation of FBN1 gene encoding the regulation of fibrillin 1 located on chromosome 15q.3. A 16 year old male presented with chief complaints of curtain like shadow in temporal visual field with present glasses for past 7 days. He had bilateral ectopia lentis with rhegmatogenous retinal detachment sparing the macula in the left eye. General examination of patient revealed physical features suggestive of Marfan's syndrome. Although genetic testing was not possible, all features were suggestive of Marfan's syndrome according to revised Ghent criteria. Pars plana vitrectomy with lens extraction with silicone oil injection was the treatment of choice. After an eventful post-operative period with silicone oil induced rise in intraocular pressure and 360 degrees peripheral anterior synechiae, early removal of silicone oil led to a good final visual outcome. Thus, with early detection and prompt treatment we were able to restore his visual quality of life. Although serious and vision threatening manifestations may occur in the eye in cases of Marfan's syndrome, early diagnosis and prompt treatment may be able to salvage vision. It is necessary to keep patients on regular follow up and inform them of possible vision threatening ocular manifestations in the eye for early diagnosis and prompt management.

Keywords: Marfan's syndrome; Ectopia lentis; Rhegmatogenous retinal detachment; vitrectomy; Silicone oil.

INTRODUCTION

Marfan's syndrome is a multisystem disorder affecting mainly cardiovascular, skeletal and ocular system. With an incidence of 2-3 per 10000, and no specific gender predilection, this connective tissue disorder is characterized by autosomal dominant mutation of FBN1 gene encoding the regulation of fibrillin 1 located on chromosome 15q.3.¹⁻³ Patients with MFS (Marfan's syndrome) display multiple deformities of the skeleton including dolichostenomelia (long limbs compared to trunk), arachnodactyly (abnormally long and thin digits), thoracolumbar scoliosis, and pectus deformities (excavatum and carinatum).^{4,5,6} Aortic regurgitation, dilatation, and aneurysms are most common in the cardiovascular system.^{7,8} Mitral valve prolapse can also occur.⁹ Ocular findings include dislocation of the lens, cataract, myopia, and retinal detachment.¹⁰ The diagnosis of MFS is usually made clinically based on typical abnormalities. Craniofacial characteristics, thumb and wrist signs, severe hindfoot valgus, and pectus carinatum are the physical features with the highest diagnostic yield.¹¹ However, there is a broad range of clinical severity associated with MFS, ranging from isolated monosystemic features of MFS to neonatal presentation of severe and rapidly progressive disease involving multiple organ systems.¹² Even though the syndrome is classically described as having ocular, cardiovascular, and musculoskeletal manifestations, involvement of the lung, skin, and central

nervous system may also occur.¹³ There is no specific laboratory test except for molecular genetic testing for the diagnosis of MFS.^{1-3,14} As genetic testing is not feasible worldwide, modified Ghent criteria has been widely accepted for the diagnosis of Marfan's syndrome. This employs a set of 'major' and 'minor' manifestations for the diagnosis of Marfan's syndrome.¹⁵

Case report

A 16 year old boy presented to the hospital with complaints of discomfort in visual field in left eye for past 7 days. Discomfort of left eye was described as a curtain like shadow in the temporal visual field. Patient had previously had regular ocular examinations and had been diagnosed with bilateral ectopia lentis with dense amblyopia with 60 degrees exotropia in the right eye. Uncorrected visual acuity (UCVA) was 2/60 in RE and 2/60 in LE. Best corrected visual acuity (BCVA) was 3/60 with +8.00 DS in RE and 6/6 with +9.00 DS in LE. Intraocular pressure was 36mm Hg in the right eye and 23 mm Hg in the left eye. Further examination of anterior segment revealed quiet anterior chamber with bilaterally absent lens in physiological position (Figure 1). Posterior segment evaluation under mydriatics of RE revealed posterior dislocation of lens into the vitreous cavity. Optic nerve head was well delineated pink with cup disc ratio (CDR) 0.8:1 with inferior rim loss. Macula was within normal range. Posterior segment

evaluation of LE under mydriatics revealed posterior dislocation of lens into vitreous cavity and rhegmatogenous retinal detachment of the inferior and inferonasal quadrant of retina, involving 5-11 clock hours from periphery to optic disc sparing the macula. Horse shoe tear (HST) was seen at 9:30 o'clock just posterior to the equator. Optic nerve head was well delineated, pink with cup disc ratio 0.8:1 with inferior rim thinning. Gonioscopy showed peripheral anterior synechiae in all quadrants of the anterior chamber angle. Patient was thin and tall with apparently disproportionately long arms and legs as compared with the trunk. His arm span, 71cm, was more than his height 69cm. However his floor to pubis measurement/pubis to vertex measurement

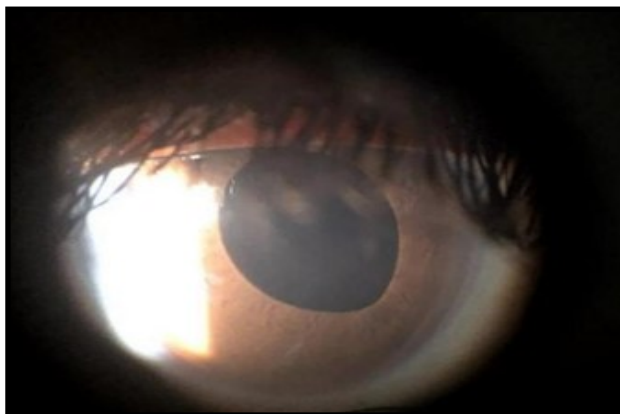


Figure 1 –Absence of crystalline lens in physiological position.

was 1.2 which leans towards the upper range of the limit of 0.3. This may be explained by the young age, hence final growth spurt yet to occur. (Figure 2)

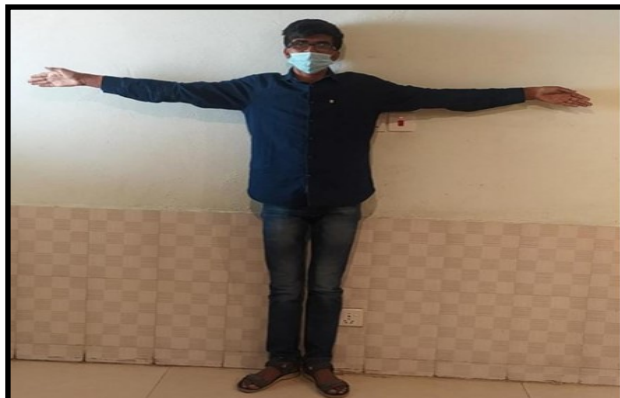

Figure 2. Physical appearance.

Mild hunching of the back was also noticed. Examination of his hands revealed elongated fingers with thickening of interphalangeal joint. (Figure 3A) A positive Steinberg thumb sign, that is, extension of the distal phalanx of the thumb beyond the ulnar border of the hand when apposed across the palm was observed indicating extreme ligament laxity. (Figure 3B) A positive Walker Murdoch wrist sign that is overlapping of thumb and fifth finger around the wrist was observed. (Figure 3C)

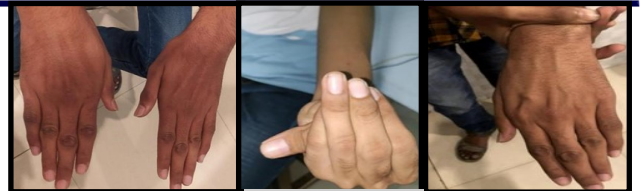

Figure 3A. Elongated fingers . Figure 3B. Steinberg thumb sign. Figure 3C. Walker Murdoch wrist sign.

On further inquiry and examination with consent, similar ocular and physical features were present in younger brother of the patient. The unaided visual acuity (UCVA) was 2/60 on RE and 2/60 on LE. Best corrected visual acuity (BCVA) was 6/6 with +12.00 DS on RE and 6/6 with +12.50 DS on LE. Further examination of anterior segment revealed quiet anterior chamber with bilaterally absent crystalline lens in physiological position due to posterior dislocation of the crystalline lens into the vitreous cavity which was seen after fundus evaluation under mydriasis (Figure 4).



Figure 4. Bilateral crystalline lens drop in younger brother.

Optic nerve head was well delineated, pink, with cup disc ratio (CDR) 0.2:1. He was also thin and tall with disproportionately long arms and legs as compared with the trunk. His arm span, 69cm, was more than his height 66.8cm. (Figure 5)

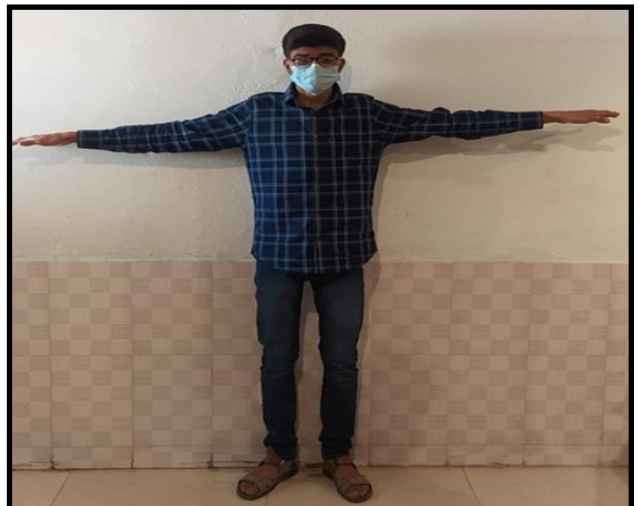

Figure 5 – Physical appearance of younger brother.

Examination of his hands revealed presence of elongated fingers with thickening of interphalangeal joint (Figure 6A), positive Steinberg thumb sign (Figure 6B) and a positive Walker Murdoch wrist sign (Figure 6C) as well. On further questioning, the mother of the patient stated that the patients' father also had similar built, had been diagnosed with lens dislocation and was also wearing thick glasses for optical correction. USG B scan revealed

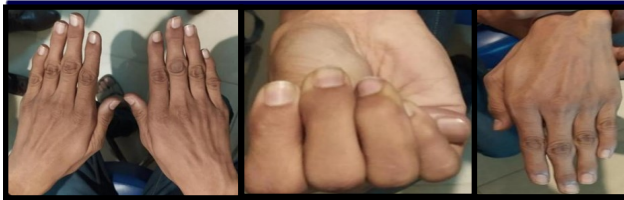

Figure -6. Signs in younger brother A) Elongated fingers B) Steinberg thumb sign C) Walker Murdoch wrist sign.

posterior dislocation of the lens into the vitreous cavity in RE (Figure 7A)

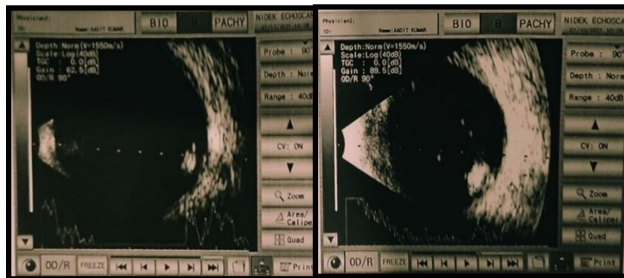


Figure 7A. USG Bscan RE.

and posterior dislocation of lens into the vitreous cavity with retinal detachment in the inferior pole in LE (Figure 7B).

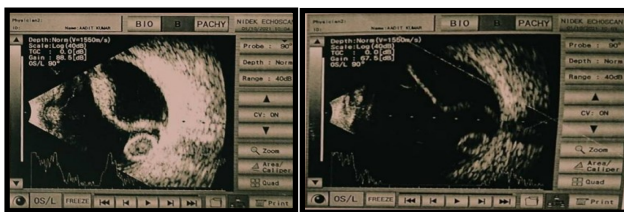

Figure 7B. USG Bscan LE.

The central corneal thickness of RE was 585µm and in LE was 564µm, so the corrected IOP by Goldmann Applanation tonometry taking Central Corneal Thickness into account was 31.8mmHg in RE and 19mmHg in LE. Optical coherence Tomography of optic disc of both eyes revealed vertical and horizontal cup disc ratio to be 0.9 with decreased retinal nerve fiber layer (RNFL) thickness in all quadrants of optic nerve head suggesting glaucomatous changes (Figure 8).

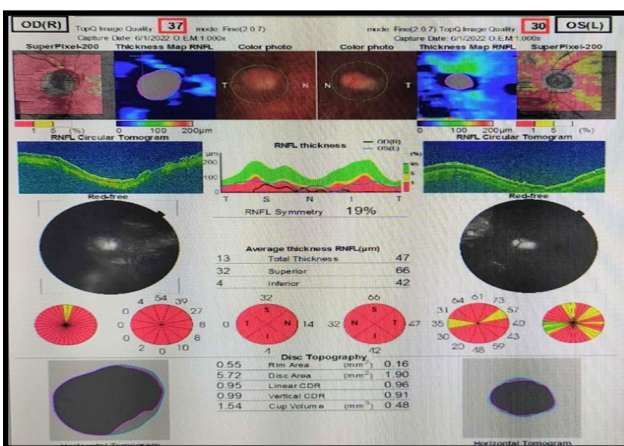


Figure 8- Optical Coherence Tomography of Optic Nerve Head.

The younger brother also underwent USG B scan of the posterior segment for documentary evidence of bilateral posterior dislocation of the lens into the vitreous cavity. (Figure 9)

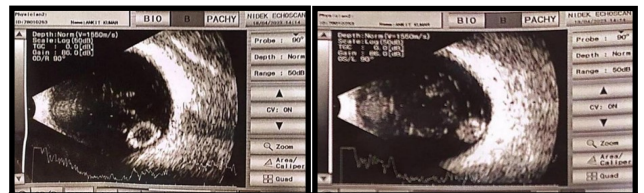

Figure 9-USG B-scan of younger brother showing dislocated lens in vitreous A)RE B)LE.

Patient was referred to cardiologist for further evaluation to rule out any significant systemic anomalies that would affect feasibility for surgical intervention in the eye. There was mild mitral regurgitation and aortic regurgitation but no sign of aortic dissection. Other systemic evaluation was normal and there were no contraindications to surgery. Patient was diagnosed with Marfan's syndrome with Ectopia Lentis with Lens in vitreous with Secondary Angle Closure Glaucoma with ametropic amblyopia in Right Eye and Ectopia Lentis with Lens in vitreous with macula sparing inferior and inferonasal rhegmatogenous retinal detachment with secondary Angle Closure glaucoma in Left Eye. Patient was started with Eyedrop Brimonidine tartrate 0.2% and Timolol Maleate 0.5% BD for BE. Patient underwent LE Pars Plana Vitrectomy + Lens aspiration + Subretinal fluid drainage through drainage retinotomy at 9:30 o'clock + Endolaser + Inferior Peripheral Iridectomy + Fluid Air exchange + Silicon Oil Insertion (6 ml) under monitored anesthesia care. No intraocular lens was placed. Patient was advised strict head down position post operatively. On 1st post-operative day, the operated eye had retina on status however crystalline lens dislocation into AC was noted in RE (contralateral eye). This was most likely due to strict head down position post-operatively along with dilated pupil status. Patient underwent RE Lens aspiration under local anesthesia. No intraocular lens was placed. Post operatively raised IOP 40mm Hg in LE was noted so topical dorzolamide(2%) three times a day and bimatoprost (0.03%) once daily were added to treatment regimen on LE. IOP was constantly monitored during hospital stay. Patient was discharged with topical steroid and antibiotics on 7th Postoperative day (Figure 10).

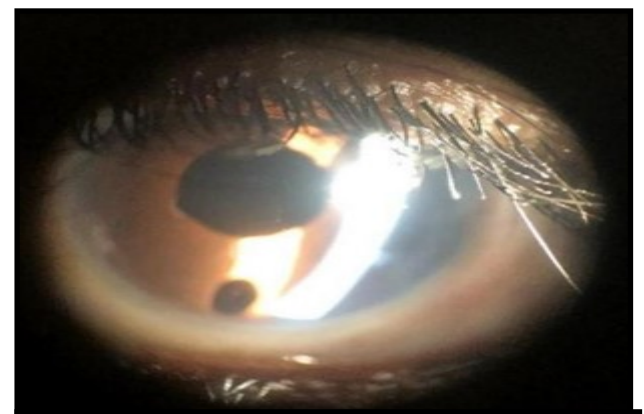


Figure 10. 7th Post-operative day findings.

On 10th postoperative day, patient was brought in our hospital with chief complaints of headache and blurring of vision. On examination VA on BE was 1/60 (FC). Intraocular pressure on RE was 38 mm Hg and on LE was 28mmHg. Patient had corneal epithelial and stromal edema in both eyes. The patient was admitted. Topical steroids were tapered and patient was started on maximum topical antiglaucoma medications (brimonidine+timolol, dorzolamide and bimatoprost) in RE as well along with tab acetazolamide 500mg BD. IOP was noted 28mm Hg on RE and 20 mm Hg on LE after starting additional antiglaucoma medications. However, after 24 hour IOP was still observed to be on higher side for LE that is 42mmHg and 30mm Hg. Therefore, Patient required oral Glycerol 3mg/kg i. e 30ml along with Lemon juice over 15 minutes BD. Nd:YAG Laser Peripheral Iridotomy was done in RE. After 9 days of monitoring and systemic antiglaucoma medications, patient's IOP stabilized and patient was discharged on topical antiglaucoma medications. Patient required early silicon oil removal due to recurrent flares of high IOP. Silicone oil removal was done at 2 months postoperatively. At 1 month post silicon oil removal, best corrected visual acuity of patient was 3/60 (FC) for RE and 6/6p for LE. Poor vision in RE was due to pre-existing ametropic amblyopia and left eye had good vision as macula was on throughout the course of events. No further damage to the already glaucomatous optic disc was noted due to silicone oil insertion.

DISCUSSION

Marfan's syndrome was first described by French pediatrician Marfan in 1896 in a 5 and half year old boy child who had long, thin extremities. The term "Marfan syndrome" was first introduced by Weve of Utrecht, The Netherlands, who used the term "dystrophia mesodermalis congenita, typus Marfanis," conceiving of it as a generalized defect of mesenchymal tissues.¹⁰ The incidence of classic Marfan's syndrome is about 2-3 per 10000 individuals with no gender predilection.¹⁻³ Marfan's syndrome is a connective tissue disorder characterized by autosomal dominant mutation of FBN1 gene encoding the regulation of fibrillin 1 located on chromosome 15q.3.1^{1-3,12} Fibrillin 1 is main constituent of microfibrils in extracellular matrix contributing in incorporation of elastin to elastic fibres.^{2,12} Mutation of this protein thus results in impaired protein synthesis, secretion and defective integreition in connective tissue leading to disintregation and fragility of tissues, clinically manifests as Aortic root aneurysm, joint hypereflexibility and ectopia lentis.^{2-5,12} Fibrillin 1 also an important structural component of extracellular matrix involved in regulation Transforming Growth Factor β (TGF β)^{1,2,3} Alteration in fibrillin 1 protein alters intercellular communication leading to increased amount of TGF β in extracellular space leading to enhancement of collagen synthesis and extracellular matrix remodeling which may be the pathophysiology behind musculoskeletal features in Marfan's syndrome.¹⁻⁵ The only true diagnosis of Marfan's syndrome is a presence of suggestive clinical features along with detection of a genetic

defect by gene analysis. This is neither affordable, nor available for every suspected patient. Hence, he modified Ghent criteria was formulated which employs a set of 'major' and 'minor' manifestations in skeletal, ocular, cardiovascular, and pulmonary systems and the dura, skin and integument system for the diagonosis of Marfan's syndrome.^{11, 15, 17} Major manifestations include ectopia lentis, aortic root dilatation/dissection, dural ectasia or a combination of 4 or more out of eight major skeletal features (Box 2).^{11, 15, 17} The most common ocular manifestation seen in Marfan patients is ectopia lentis, occurring in 50–80% of affected individuals. Myopia is the second most common ocular manifestation in Marfan syndrome is myopia, found in 34–44%.¹⁶ Retinal detachment, the most serious and vision threatening ocular manifestation, occurs in 5–11% of patients with increased incidence to 8–38% in the presence of ectopia lentis.¹⁶ Other ocular conditions like strabismus, is present in 19–45%, glaucoma most commonly primary open-angle glaucoma is will develop in about 35% of people with the syndrome during their lifetime. Other ocular conditions like flat cornea, megalocornea, hypoplastic iris and ciliary body are minor features of Marfan's syndrome.^{16, 17} Complete bilateral spontaneous posterior lens dislocation is a rare manifestation.¹⁶ In the present case, the child had Marfan's syndrome with bilateral spontaneous posterior dislocation of lens with associated aphakic hypermetropia and secondary glaucoma. The patient had ametropic amblyopia in right eye and rhegmatogenous retinal detachment in left eye. Salvaging good vision after retinal detachment surgery in a case of marfan's with established glaucoma had been possible due to early diagnosis and prompt treatment.

CONCLUSION

Marfan's syndrome diagnosis and management involves multidisciplinary approach for survival and better quality of life. Although cardiovascular complications are life threatening and the cause of mortality in these patients, it is important to improve the quality of life with regular medical checkup and special emphasis on vision and ophthalmological screening. Early diagnosis and prompt treatment can be vision saving as well as lifesaving.

Strength/ highlights of study

Documentation of a rare disease. Eventful post-operative course with difficulty in management of complications-special emphasis on anticipation of complications. Final visual outcome even though early removal of silicone oil was needed was worth special mention.

Limitations

Gene testing could not be carried out due to the limitations of economic and logistic resources.

Conflict of Interest: None.

References

1. Pepe G, Giusti B, Sticchi E, Abbate R, Gensini GF, Nistri S. Marfan syndrome: current perspectives. *Appl Clin Genet.* 2016; 9: 55–65. DOI: 10.2147/TACG.S96233
2. Benke K, Ágg B, Szilveszter B, Tarr F, Nagy ZB, Pólos M, Daróczi L, Merkely B. 278 Szabolcs Z. The role of transforming growth factor-beta in Marfan syndrome. *Cardiol J.* 2013;279(20):227-34. DOI: 10.5603/CJ.2013.0066
3. Judge DP, Dietz HC. Marfan's syndrome. *Lancet.* 2005;366(9501):1965-1976. doi:10.1016/S0140-6736(05)67789-6 DOI: 10.1016/S0140-6736(05)67789-6
4. Sponseller PD, Hobbs W, Riley LH, Pyeritz RE. The thoracolumbar spine in Marfan syndrome. *J Bone Joint Surg Am.* 1995 Jun;77(6):867-76. DOI: 10.2106/00004623-199506000-00007
5. Robins PR, Moe JH, Winter RB. Scoliosis in Marfan's syndrome. Its characteristics and results of treatment in thirty-five patients. *J Bone Joint Surg Am.* 1975 Apr;57(3):358-68. Google Scholar
6. Demetracopoulos CA, Sponseller PD. Spinal deformities in Marfan syndrome. *Orthop Clin North Am.* 2007 Oct;38(4):563-72, vii. DOI: 10.1016/j.ocl.2007.04.003 Google Scholar
7. Ammash NM, Sundt TM, Connolly HM. Marfan syndrome-diagnosis and management. *Curr Probl Cardiol.* 2008 Jan;33(1):7-39. DOI: 10.1016/j.cpcardiol.2007.10.001 Google Scholar
8. McKUSICK VA. The cardiovascular aspects of Marfan's syndrome: a heritable disorder of connective tissue. *Circulation.* 1955 Mar;11(3):321-42. DOI: 10.1161/01.cir.11.3.321 Google Scholar
9. Taub CC, Stoler JM, Perez-Sanz T, Chu J, Isselbacher EM, Picard MH, Weyman AE. Mitral valve prolapse in Marfan syndrome: an old topic revisited. *Echocardiography.* 2009 Apr;26(4):357-64. DOI: 10.1111/j.1540-8175.2008.00825.x Google Scholar
10. Maumenee IH. The eye in the Marfan syndrome. *Birth Defects Orig Artic Ser.* 1982;18(6):515-24.
11. Sponseller PD, Erkula G, Skolasky RL, Venuti KD, Dietz HC. Improving clinical recognition of Marfan syndrome. *J Bone Joint Surg Am.* 2010 Aug 04;92(9):1868-75. DOI: 10.2106/JBJS.I.00892.
12. Child AH, Aragon-Martin JA, Sage K. Genetic testing in Marfan syndrome. *Br J Hosp Med (Lond).* 2016 Jan;77(1):38-41. DOI: 10.12968/hmed.2016.77.1.38
13. Dietz H. FBN1-Related Marfan Syndrome. In: Adam MP, Everman DB, Mirzaa GM, Pagon RA, Wallace SE, Bean LJH, Gripp KW, Amemiya A, editors. *GeneReviews®* [Internet]. University of Washington, Seattle; Seattle (WA): Apr 18, 2001. Google Scholar
14. Dietz HC, Cutting GR, Pyeritz RE, Maslen CL, Sakai LY, Corson GM, Puffenberger EG, Hamosh A, Nanthakumar EJ, Curristin SM. Marfan syndrome caused by a recurrent de novo missense mutation in the fibrillin gene. *Nature.* 1991 Jul 25;352(6333):337-9. DOI: 10.1038/352337a0
15. Loeys BL, Dietz HC, Braverman AC, Callewaert BL, De Backer J, Devereux RB, Hilhorst-Hofstee Y, Jondeau G, Faivre L, Milewicz DM, Pyeritz RE. The revised Ghent nosology for the Marfan syndrome. *Journal of medical genetics.* 2010 Jul 1;47(7):476-85. DOI: 10.1136/jmg.2009.072785