

## A Case Report on Coronary Artery Perforation During Percutaneous Intervention

Asraf Hussain,<sup>1\*</sup> Shyam Raj Regmi,<sup>1</sup> Bishnu Mani Dhital,<sup>1</sup> Shovit Thapa,<sup>1</sup> Sagar Thapa,<sup>1</sup> Rohit Murarka,<sup>1</sup> Ramgobind Chaudhary,<sup>1</sup> Ashok Shrestha,<sup>1</sup> Roshan Shrestha,<sup>1</sup> Bishwaraj adhikari<sup>1</sup>

<sup>1</sup>Department of Cardiology, Chitwan Medical College, Bharatpur, Chitwan Nepal.

**Received:** 5<sup>th</sup> August, 2022

**Accepted:** 6<sup>th</sup> December, 2022

**Published:** 28<sup>th</sup> December, 2022

**DOI:** <https://doi.org/10.3126/jnhls.v1i1.52899>

**Correspondence:**

\*Dr. Asraf Hussain, Department of Cardiology, Chitwan Medical College, Bharatpur, Chitwan, Nepal.

Email: asrafjeevanjyoti2060@gmail.com  
m. Phone: +977-9807225300

**Citation:** Hussain A, Regmi SR, Dhital BM, Thapa S, Murarka R, Chaudhary R, Shrestha A, Shrestha R, adhikari B, A Case Report on Coronary Artery Perforation during Percutaneous Intervention. JNHLS. 2022; 1 (1):32-34.

**ABSTRACT**

Coronary artery perforation (CAP) is one of the most dreadful complications encountered during Percutaneous Coronary Intervention (PCI). Though being rare, the high mortality rate associated with CAP makes it one of the most important complications that should be well known to all the coronary interventionist.

The treatment modalities range from balloon tamponade, reversal of anticoagulation, coils, microbeads, pericardiocentesis, covered stents and in desperate situations, coronary artery bypass graft. We present here a case of 65 year old male with extensive anterior wall myocardial infarction who developed CAP of proximal left anterior descending artery during PCI. The case was successfully managed with covered stent.

**Keywords:** coronary artery perforation; covered Stent; percutaneous intervention.

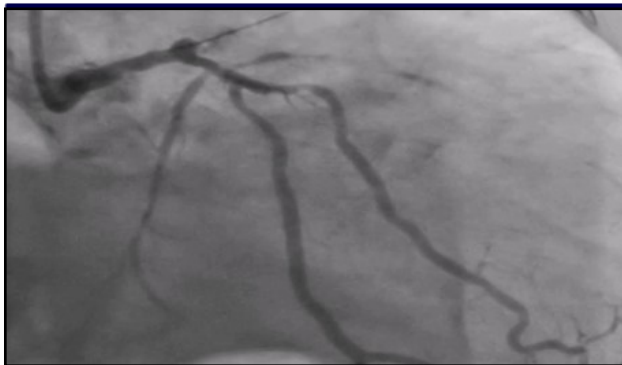**INTRODUCTION**

Coronary artery perforation (CAP) is a rare complication that can lead to cardiac tamponade, myocardial infarction (MI), cardiogenic shock, cardiac arrest, and/or death.<sup>1-3</sup> Ellis classification is the most commonly used for CAP.<sup>5</sup> Grade I/ II perforations usually can be managed with reversal of anticoagulation and/or prolonged balloon inflation or delivery of occlusive coils, fat, or beads. If these perforations do not get sealed with above interventions and small endovascular leak persists the use of covered stents is warranted. Sometimes, such perforations may require emergency CABG. Grade III perforations are more notorious and may need pericardiocentesis, polytetrafluorethylene (PTFE)-covered stent, and/or referral for CABG.<sup>6</sup>

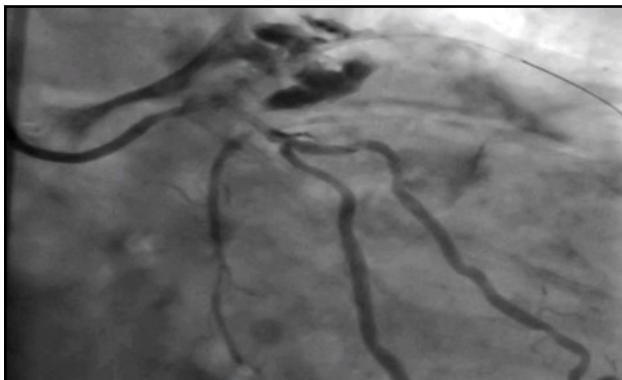**CASE PRESENTATION**

A sixty five year old male presented to emergency department with typical chest pain of two hours duration. He was a known case of hypertension for five years and diabetes mellitus for four years. He was non compliant to his usual medications. He was current smoker. On examination, patient was anxious, diaphoretic. His pulse was 108 beats per minute, regular. Blood pressure (BP) was 80 mm of Hg systolic and 60 mm of Hg diastolic. His lungs were clear, cardiovascular examination revealed normal 1<sup>st</sup> and 2<sup>nd</sup> heart sound. No s3 and s4 were heard. There was no appreciable murmur. ECG was done which revealed ST segment elevation in precordial leads V1 to V6. Echocardiographic evaluation revealed hypokinesia of left anterior descend-

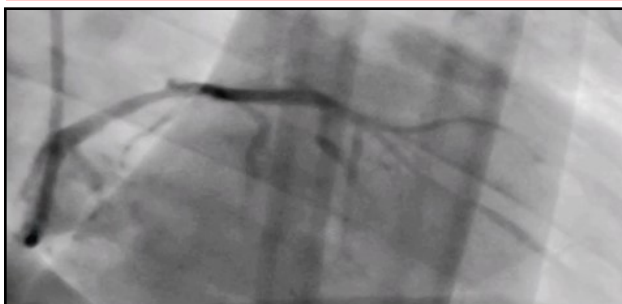ing artery territory. Estimated ejection fraction was 45%. Patient was shifted to cath lab for coronary angiogram and primary percutaneous intervention. On coronary angiogram of right coronary artery, minor plaques were seen. Left coronary circulation angiography revealed total occlusion of proximal segment of left anterior descending artery. Left circumflex coronary artery was found to have diffuse lesion. Left anterior descending artery primary PCI was planned. Left main coronary artery was engaged with JL3.5 guiding catheter. Whisper guide wire was crossed across the lesion and non-compliant balloon of size 2 was inflated to 8 atm pressure. Immediately after deflation of the balloon, injection of contrast revealed extravasation into the pericardial space. Diagnosis of coronary artery perforation (Ellis type 3) was made. Balloon tamponade was done using same NC balloon at 6 atm pressure which achieved absence of leakage from perforation. Meanwhile, Echocardiography was done and no evidence of pericardial effusion was seen. Patient did not deteriorate haemodynamically till this point of time. Even after three cycles of inflation deflation of balloon at interval of 10 minutes each, perforation was not sealed. Decision was made to reverse anti coagulant effect of unfractionated heparin by Infusion of protamine sulphate. Total 50 mg of protamine sulphate was given via IV infusion. Even after protamine therapy, perforation was not sealed. However, patient vitals were stable and only minimal pericardial effusion without evidence of tamponade was noted on Echocardiography. Finally, decision



**Figure 1. Wire crossed across the lesion in LAD.**



**Figure 2. Coronary artery perforation (Ellis type III)**



**Figure 3. Left anterior descending artery coronary artery perforation sealed with covered stent.**

to use covered stent was made and a covered stent (of size 3\*30) was used. After deployment of covered stent, perforation was sealed and TIMI grade 3 flow was achieved distal to lesion. Echocardiographic evaluation was continued every 15 minutes during and 3 hours after procedure. No features of significant pericardial effusion or cardiac tamponade were noticed. Patient was shifted to CCU and was started on guideline directed therapy with Dual antiplatelets, HMG CoA reductase inhibitors, Beta blockers and Angiotensin receptor blockers were introduced subsequently during hospital stay. Further hospital stay was uneventful, and patient was discharged on day six of admission. On Follow up, after one week, one month, three month patient was doing fine. His Echocardiographic evaluation revealed no evidence of pericardial effusion.

## DISCUSSION

While Performing Percutaneous Coronary Intervention (PCI) one of the most catastrophic complication is iatrogenic coronary artery perforation (CAP). Luckily it is a rare complication. Incidence of CAP is 0.43% with PCI and it may rise up to 2.9% in chronic total occlusion interventions.<sup>2</sup> CAP can lead to cardiac tamponade, myocardial infarction (MI), cardiogenic shock, cardiac arrest, and/or death. CAP carries high mortality risk which can be upto 21.2%.<sup>3</sup>

Risk Factors associated with CAP can be categorized as mentioned below.<sup>4</sup> Non-modifiable risk factors: Old age, Female gender, History of previous coronary artery bypass graft (CABG), Use of clopidogrel. Modifiable risk factors: Presence of hypertension, Presence of peripheral artery disease, Presence of congestive heart failure, Lower body mass index, Lower creatinine clearance. Risk factors associated with coronary anatomy and catheterization: Complex coronary lesions (ACC/AHA Type B2, C) Chronic total occlusions, heavily calcified lesions, angulated, tortuous lesions, narrow coronary arteries, Aggressive use of oversized balloons and stents, Use of atheroablative devices and hydrophilic guidewires.

Ellis classification is the most commonly used for CAP.<sup>5</sup>

Type I: Presence of extraluminal crater without extravasation

Type II: Presence of pericardial or myocardial blush without contrast jet extravasation

Type III: Presence of contrast jet extravasation through frank perforation ( $\geq 1$  mm)

Type III (CS): Presence of contrast jet extravasation into the cavities like a cardiac chamber or coronary sinus.

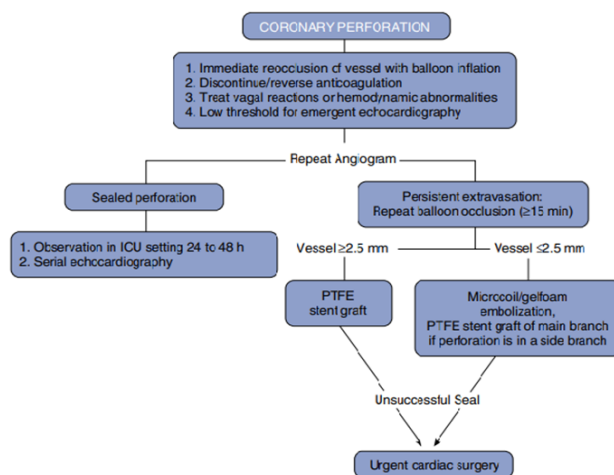
Clinical features may range from hypotension, severe chest pain, dizziness, or nausea disproportional to symptoms. There may be persistent ST segment changes after balloon deflation. Vasovagal reactions may also accompany perforations along with severe bradycardia and hypotension.<sup>6</sup>

## Management

Grade I perforations usually can be managed with reversal of anticoagulation and/or prolonged balloon inflation at/or proximal to the perforated vessel segment or delivery of occlusive coils, fat, or beads. If these perforations do not get sealed with above interventions and small endovascular leak persists the use of covered stents is warranted. Sometimes, such perforations may require emergency CABG. Grade III perforations are more notorious and may need pericardiocentesis, polytetrafluoroethylene (PTFE)-covered stent, and/or referral for

CABG.<sup>6</sup>

In case of perforation operator needs to remain calm and remember the fundamental that balloons should remain in the guide or within the lesion following any inflation until angiography confirms there is no perforation. Once perforation is recognized, balloon expansion to a pressure sufficient to occlude flow (usually 2 to 4 atm) is the urgent step.



Once all interventional devices are removed reversal of anticoagulation is indicated. The usual reversal agent for heparin is protamine, Glycoprotein IIb/IIIa inhibitors -abciximab can be reversed with an infusion of platelets. The effects of tirofiban and

eptifibatid cannot be reversed with platelet infusions, but both have a shorter half-life compared to abciximab.<sup>7</sup> If bivalirudin is used, fresh frozen plasma is the only mean to reverse.<sup>8</sup>

In case of development of pericardial effusion associated with tamponade, emergency pericardiocentesis should be attempted. Development of PTFE-covered stents is a major advance in the treatment of CAP. Before the era of PTFE stents, the presence of a grade III perforation often required emergency CABG and carried significant mortality.<sup>9</sup> In case of Perforations in small vessels, additional prolonged balloon inflations or the injection of thrombin, polyvinyl alcohol, Gelfoam, collagen, or the embolization of microcoils or beads may be effective options in management.<sup>10, 11</sup>

## CONCLUSION

Coronary artery perforation carries high risk of mortality during PCI. Hence, Anticipation and Early detection of perforation is key for successful management. In case of CAP, the operator and the team need to remain calm and follow the algorithm stepwise. All cath labs need to be equipped with modalities required for management of this catastrophic complication.

**Conflict of Interest:** None.

## REFERENCES

- Shimony A, Joseph L, Mottillo S, Eisenberg MJ. Coronary artery perforation during percutaneous coronary intervention: a systematic review and meta-analysis. *Can J Cardiol.* 2011; 27:843–850.
- Patel VG, Brayton KM, Tamayo A, Mogabgab O, Michael TT, Lo N, Alomar M, Shorrocks D, Cipher D, Abdullah S, Banerjee S, Brilakis ES. Angiographic success and procedural complications in patients undergoing percutaneous coronary chronic total occlusion interventions: a weighted meta-analysis of 18,061 patients from 65 studies. *JACC Cardiovasc Interv.* 2013; 6:128–136.
- Shimony A, Joseph L, Mottillo S, Eisenberg MJ. Coronary artery perforation during percutaneous coronary intervention: a systematic review and meta-analysis. *Can J Cardiol.* 2011 Nov-Dec;27(6):843-50.
- Nagalli S, Hajouli S. Coronary Artery Perforation. [Updated 2022 Jul 4]. In: StatPearls [Internet]. Treasure Island (FL): StatPearls Publishing; 2022 Jan -. Available from: <https://www.ncbi.nlm.nih.gov/books/NBK554476/>
- Ellis SG, Ajluni S, Arnold AZ, Popma JJ, Bittl JA, Eigler NL, Cowley MJ, Raymond RE, Safian RD, Whitlow PL. Increased coronary perforation in the new device era. Incidence, classification, management, and outcome. *Circulation.* 1994 Dec;90(6):2725-30.
- Klein, L.W. (2006), Coronary artery perforation during interventional procedures. *Cathet. Cardiovasc. Intervent.*, 68: 713-717.
- Dippel EJ, Kereiakes DJ, Tramuta DA, et al. Coronary perforation during percutaneous coronary intervention in the era of abciximab platelet glycoprotein IIb/IIIa blockade: an algorithm for percutaneous management. *Catheter Cardiovasc Interv.* 2001;52:279–286.
- Annappoorna SK, Oana CR, Kunal S, et al. Changing outcomes and treatment strategies for wire induced coronary perforations in the era of bivalirudin use. *Catheter Cardiovasc Interv.* 2009;74:700–707.
- Fejka M, Dixon SR, Safian RD, et al. Diagnosis, management, and clinical outcome of cardiac tamponade complicating percutaneous coronary intervention. *Am J Cardiol.* 2002;90:1183–1186.
- Gaxiola E, Browne K. Coronary artery perforation repair using microcoil embolization. *Cathet Cardiovasc Diagn.* 1998;43:474–476.
- Pravin KG. Delayed and repeated cardiac tamponade following microleak in RCA successfully treated with intra arterial sterile glue injection. *Catheter Cardiovasc Interv.* 2009;73:797–800