

## A Rare Case Report on Pyopericardium Progressing to Cardiac Tamponade

Krishna Yadav,<sup>1</sup> Shankar Laudari<sup>1\*</sup><sup>1</sup>Chitwan Mutu Aspatal Private Limited, Bharatpur, Chitwan, Nepal.Received: 19<sup>th</sup> August, 2022Accepted: 4<sup>th</sup> December, 2022Published: 28<sup>th</sup> December, 2022DOI: <https://doi.org/10.3126/jnhls.v1i1.52898>**Correspondence:**

\*Dr. Shankar Laudari, Consultant Cardiologist Chitwan Mutu Aspatal Pvt. Ltd., Bharatpur, Chitwan, Nepal

Email: lshankar2@gmail.com

Phone: +977-9845112909

**Citation:** Yadav K, Laudari S, A Rare Case Report on Pyopericardium Progressing to Cardiac Tamponade. JNHLS. 2022; 1(1):30-31.**ABSTRACT**

Pyopericardium is a rare condition with a high mortality in which infection propagates in the pericardial space leading to pus filled pericardial effusion and cardiac tamponade, which can cause cardiogenic shock and death. We present a case of previously healthy 79 years old male, who was diagnosed as Tubercular Pericardial effusion in IOM-TUTH, Maharajjung and on Antitubercular Therapy since 2 months. The patient didn't respond well with the therapy and eventually presented to Chitwan Mutu Aspatal emergency with features of cardiac tamponade. It was confirmed on Two-Dimensional transthoracic Echocardiography and emergency pericardiocentesis drained frank pus around 1000ml. The patient was administered intravenous antibiotics along with continuation of Antitubercular Therapy and other supportive measures leading to gradual recovery of the patient and then discharged on antibiotics.

**Keywords:** pyopericardium; tuberculosis; cardiac tamponade; pericardiocentesis.

**INTRODUCTION**

Since the advent of antibiotics, pyopericardium is a rare phenomenon.<sup>1</sup> It has a high mortality rate of 40% in treated patients, and nearly 100% in untreated patients. Therefore, it is important not to miss the diagnosis. In the current era of antibiotic resistance, we may see a resurgence of this rare infective condition.

**CASE PRESENTATION**

A 79 years old man, chronic smoker being treated in IOM-TUTH with 2 months history of left sided pleuritic chest pain, increased shortness of breath on exertion and dry cough. At emergency, he was in respiratory distress with tachypnoea, raised JVP, basal crackles, distended abdomen, pedal edma, hypotension with sinus tachycardia and desaturation. Blood tests revealed anemia (chronic) with severe hyponatremia with severe hypothyroidism (Serum TSH>100mIU/L). Contrast enhanced Computed Tomography (CECT) chest reveals multiple pre-tracheal, sub-carinal lymphadenopathy, collapsed right middle lobe, B/L centi-lobular nodules (tree in buds appearance) with gross pericardial effusion with maximum thickness of 40mm and left sided pleural effusion. Chest X-ray PA view reveals enlarged cardiac shadow with left sided lower zone haziness (Figure 1). Figure 2 demonstrates Chest X-ray after pericardial and left sided pleural tapping with marked reduction in cardiac silhouette and better visualization of left costophrenic and cardiophrenic angles. ECG shows low voltage QRS with sinus tachycardia with electrical alternans. 2D-Transthoracic Echocardiography shows massive circumferential pericardial effusion with RA and

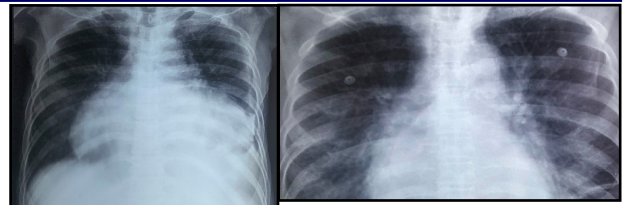


Figure 1. gross cardiomegaly.

Figure 2. Chest X-ray after pericardial tapping with water bottle sign.

RV diastolic collapse, distended IVC and hepatic veins with marked respiratory variation of tricuspid and mitral flow suggestive of pericardial tamponade (Figure 3). Patient was then shifted to

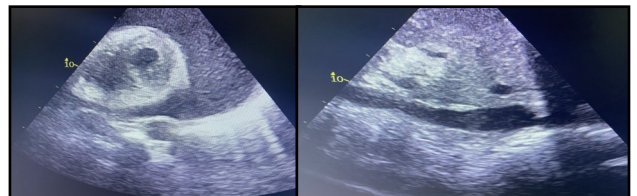



Figure 3. Massive circumferential Pericardial effusion with RA and RV diastolic collapse, Dilated IVC.

CCU and emergency pericardiocentesis was performed under ultrasound guidance. Frank pus of about 1000ml was aspirated from pericardial space through subcostal approach. The purulent fluid was sent for relevant investigations including culture sensitivity, ADA and cytology. Patient was started on iv antibiotics along with continuation of ATT. Levothyroxine 50mcg once a day was added and dose was titrated after few weeks. Examination of pericardial fluid analysis revealed high WBCs compromising of polymorphs and lymphocytes. ADA was very high(75). LDH was marked-

ly elevated with low glucose and plenty of pus cells  $>25/\text{hpf}$  on gram stain. About 500ml of straw colored pleural fluid was aspirated from left intercostals space which on evaluation was suggestive of tubercular in origin. Patient improved gradually after pericardiocentesis and pleural tapping with resolution of the symptoms.

#### Outcome and follow-up



**Figure 4. Pyopericardium** **Figure 5. Aspirated Pleural fluid.**

#### DISCUSSIONS

Pyopericardium is diagnosed when pus is drained from the pericardium or bacteria are grown from pericardial space. It is rare accounting for  $<1\%$  of causes of pericarditis.<sup>4</sup> The mortality rate can reach 100% if left untreated due to cardiogenic shock as increasing amount of pus in the pericardial space causes tamponade.<sup>3</sup> Other imaging such as CT and MRI be used to aid diagnosis. The condition generally presents with fever, chest pain, congestive cardiac failure, cardiac tamponade and later with sepsis and cardiogenic shock.<sup>5</sup> Diagnosis can be delayed due to initial source of infection distracting from underlying cardiac problem. The likely reason for lack of ability to culture organism in the case of our patient was due to the high dose of antibiotics

that the patient was receiving, which may have impeded growth of the organism in the sample sent. The most common organism reported to cause pyopericardium in most of cases is staphylococcus aureus.<sup>7</sup> It has been reported that Gram –negative bacteria, TB and fungi are becoming more frequent due to infection in immunocompromised host.<sup>7</sup> Causes linked to pyopericardium are pneumonia, TB, empyema thoracis, thoracic surgery, and hematogenous spread through the sepsis. More rare causes include perivalvular abscess rupture in endocarditis and spreading along fascial plane from the oral cavity. In our case, the source of infection could be through pulmonary TB. Treatment is based around drainage of the pyopericardium, antibiotics therapy and ATT and pericardiotomy.<sup>6</sup> The risk of these can be reduced with ECHO guided placement of catheter.<sup>9,10</sup> The pericardial catheter is left in situ to allow further drainage and prevent an effusion recurring (which can occur in up to 75% of cases).<sup>11</sup> The turtle cage technique has also been suggested to an alternative to epicardectomy, in which slits are made to allow movement of fibrotic sections.<sup>12</sup> Our patient was advised for epicardial debridement which may have a good outcome.

#### CONCLUSION

Coexisting infection can be mask symptoms of a more sinister pathology. When a previously healthy patient is becoming fluid overloaded, look for an underlying cause with echocardiography. Be aware that the patient may present with atypical chest pain, fever and cardiogenic shock.

**Conflict of Interest:** None.

#### REFERENCES

1. Krassas A, Sakellaridis T, Argyriou M et al. Pyopericardium followed by constrictive pericarditis due to *Corynebacterium diphtheriae*. *Interact Cardiovasc Thorac Surg* 2012;14:875–7.
2. Kodan E, Tadera T, Ubuki C et al.. A case of slowly progressive purulent pericarditis in an elderly healthy woman. *J Gen Pract* 2014;2:149.
3. Bhaduri-McIntosh S, Prasad M, Moltedo J et al. Purulent pericarditis caused by group A streptococcus. *Tex Heart Inst J* 2006;33:519–22.
4. Imazio M, Brucato A, Mayosi BM et al.. Medical therapy of pericardial diseases: part I: idiopathic and infectious pericarditis. *J Cardiovasc Med (Hagerstown)* 2010;11:712–22.
5. Hall IP. Purulent pericarditis. *Postgrad Med J* 1989;65:444–8.
6. Smith Z, Wimbush S. Pneumococcal pyopericardium masquerading as acute coronary syndrome. *Intensive Care Soc* 2012;13:43–7.
7. Farhat F, Dubreuil O, Durand PG et al.. Constrictive pericarditis following a pyopericardium due to *Staphylococcus aureus*. *Interact Cardiovasc Thorac Surg* 2003;2:626–8.
8. Sparrow R. Red blood cell storage and transfusion related immunomodulation. Kabukcu M, Demircioglu F, Yanik E et al.. Pericardial tamponade and large pericardial effusions: causal factors and efficacy of percutaneous catheter drainage in 50 patients. *Tex Heart Inst J* 2004;31:398–403.
9. Salem K, Mulji A, Lonn E. Echocardiographically guided pericardiocentesis—the gold standard for the management of pericardial effusion and cardiac tamponade. *Can J Cardiol* 1999;15:1251–5.
10. Sagrista-Sauleda J, Merce AS, Soler-Soler J. Diagnosis and management of pericardial effusion. *World J Cardiol* 2011;3:135–43.
11. Faggian G, Mazzucco A, Tursi V et al.. Constrictive pericarditis after open heart surgery: the turtle cage operation. *J Card Surg* 1990;5:318–20.