

Infected Dentigerous Cyst in a 14-year-old Child Associated with Unerupted Third Molar: A Case Report

Subhani Vaidya,¹ Senchhema Limbu,² Parajeeta Dikshit,³ Manisha Malla,⁴ Lokesh Verma⁵

¹Postgraduate Resident, ^{2,3}Associate professor, ^{4,5}Lecturer

¹⁻⁴Department of Pedodontics and Preventive Dentistry, Kantipur Dental College and Hospital, Kathmandu, Nepal

⁵Department of Oral and Maxillofacial Surgery, Kantipur Dental College and Hospital, Kathmandu, Nepal.

ABSTRACT

The dentigerous cyst is a developmental odontogenic cyst, accounting for 10% of all cysts of the jaws, being the vast majority of current odontogenic cyst. Its characteristic features are unilocular radiolucent lesion which encloses permanent tooth buds or, under certain circumstances, displaced tooth buds. This paper presents a case of an infected dentigerous cyst associated with right mandibular unerupted third molar in a pediatric patient with various clinical and radiographic characteristics. The treatment comprised of proper evaluation of the past medical history, clinical, radiographic, histological examinations that helped to administer appropriate diagnosis and treatment plan; followed by complete removal of the cyst along with the involved tooth structure under general anesthesia.

Keywords: Dentigerous cyst, enucleation, impacted tooth, mandible, unerupted third molar.

INTRODUCTION

Dentigerous cysts (DC) are the most common type of developmental odontogenic cysts arising from the crowns of impacted, embedded, or unerupted teeth.¹ DC usually occurs in the permanent dentition, especially in association with third molars, maxillary canines or mandibular premolars.² The decision of the treatment procedure takes into account different factors, which includes; cyst size, location, removal of unerupted tooth and follow-ups. One of the treatment options, is enucleation which includes removal of all the cystic capsule.² This paper aims to highlight the features of an infected dentigerous cyst in the mandible associated with unerupted third molar and its management.

CASE REPORT

A 14-year-old female child presented to the Department

of Pedodontics and Preventive Dentistry, Kantipur Dental College and Hospital with the chief complain of swelling in the lower right back region of the jaw, which was gradual and progressive in nature since 1 month. It was associated with pain which was sudden on onset, intermittent in nature, aggravated while chewing and relieved on taking analgesics. Medical history was non-contributory.

Extraoral examination revealed facial asymmetry with swelling in the lower right jaw region extending from the corner of the mouth to the angle of the mandible; approximately 3 cm x 3 cm in size (Figure 1). The swelling was firm, hard and tender on palpation. Submandibular lymph nodes were palpable, mobile and tender bilaterally.

Intraoral examination revealed dental caries in 36, sinus opening in the vestibular area with respect to 47 and poor

Correspondence

Dr. Subhani Vaidya
Postgraduate Resident,
Department of Pedodontics and Preventive Dentistry
Kantipur Dental and College and Teaching Hospital,
Kathmandu, Nepal
E-mail: subhanivaidya@gmail.com

Citation

Vaidya S, Limbu S, Dikshit P, Malla M, Verma L. Infected Dentigerous Cyst in a 14-year-old Child Associated with Unerupted Third Molar: A Case Report. J Nepal Assoc Pediatr Dent. 2021;2(2):85-9.

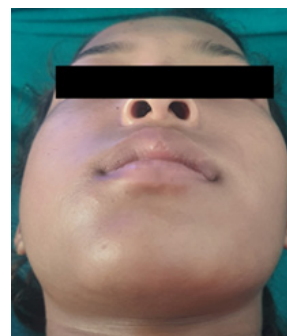

Figure 1. Extra-oral photograph.

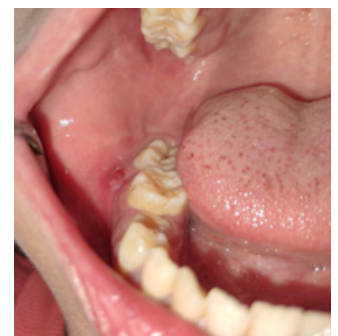

Figure 2. Intra-oral photograph showing sinus with pus discharge.

oral hygiene (Figure 2). No clinical finding related to the sinus was observed with respect to 46 and 47, therefore an orthopantomogram (OPG) was advised for definitive diagnosis.

Orthopantomogram revealed a radiolucent, spherical well-defined and well-demarcated unilocular lesion around the crown of unerupted 48 which was seen extending from the distal root surface of 47 till the ramus area with an approximate size of 27.6 mm x 21.5 mm (Figure 3). Further, cone beam computed topography (CBCT) was done to observe the vital structures and extension of the lesion to aid in treatment planning. It revealed findings similar to OPG, with dimension of the lesion as 21.22 mm x 23.4 mm x 22.3 mm; additionally, it showed perforation of buccal and lingual cortical plates along with displacement of mandibular canal below the lesion, though the canal was not involved (Figure 4,5). The differential diagnosis of unicystic dentigerous cyst, unicystic ameloblastoma or odontogenic keratocyst was considered. Considering the interim diagnosis, treatment plan of enucleation followed by extraction of the involved third molar was planned.

An informed consent from the parents and assent from the patient was taken for the procedure which was planned under general anesthesia. After induction of the anesthetic drug, at stage 3 of anesthesia, crevicular incision was given in the region 46 and 47 and enucleation of the cystic lesion, followed by extraction of the impacted tooth 48 was done. Then closure of the site was done with 3.0 resorbable suture (Figure 6-8). The specimens were sent for histopathologic evaluation (Figure 9-11).

Histological specimens included multiple pieces of soft and hard tissue mass, together measuring 4.8 cm x 3.2 cm in size and extracted 48. Histopathologically, the soft tissue section showed non-keratinized stratified squamous epithelium, 2-3 cell layers. Few areas showed epithelial hyperplasia along with arcading pattern in the area of inflammation with areas of odontogenic rests and islands showing embryonic ecto-mesenchymal tissue (Figure 12).³ Based upon the above findings along with clinical correlation, the diagnosis of infected dentigerous cyst was made. The patient was kept on observation for a period of 6 months.

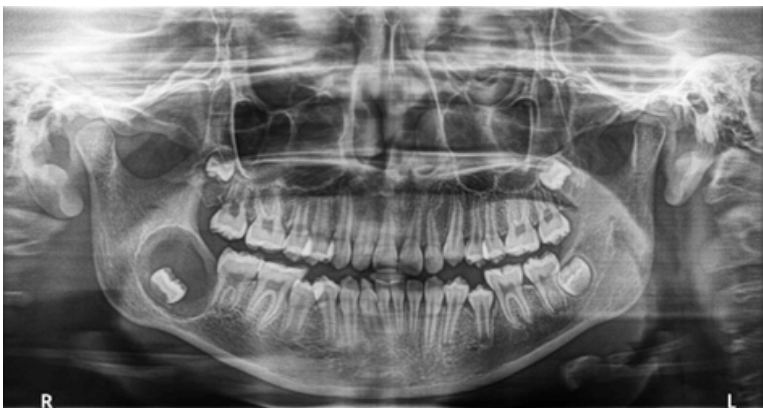

Figure 3. Orthopantomogram showing radiolucency of the lesion wrt 48.

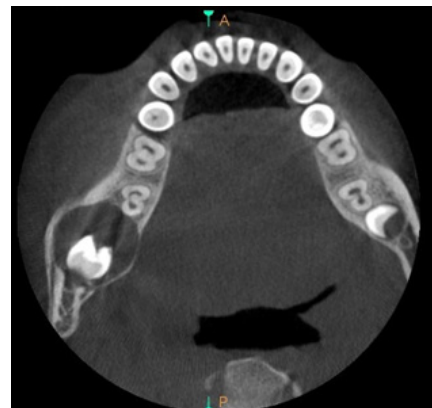

Figure 4. Axial section of CBCT showing bucco-lingual expansion and cortical thinning of the mandible involving third molar.

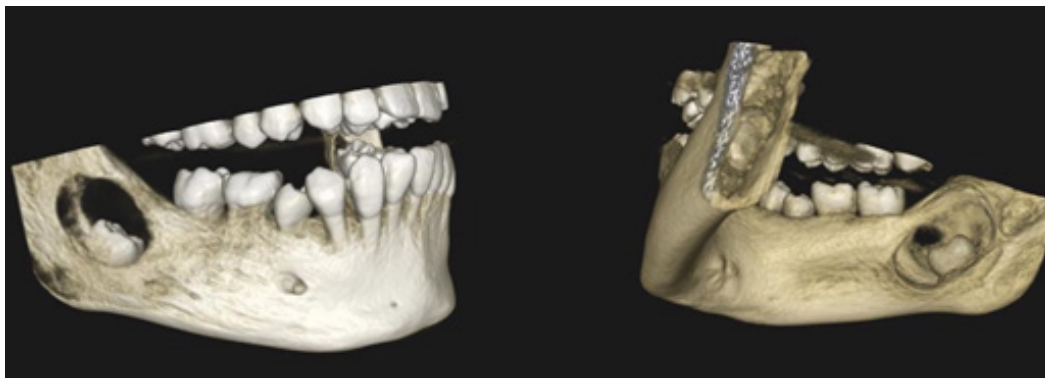


Figure 5. 3D view in CBCT showing perforation of cortical bones from vestibular and lingual sides by the lesion.

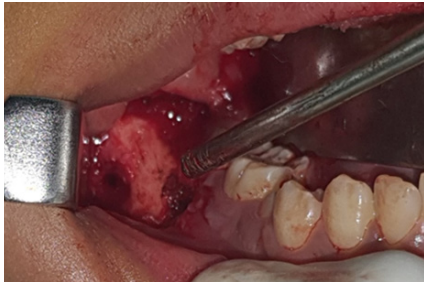

Figure 6. Intra-operative picture - flap raised.

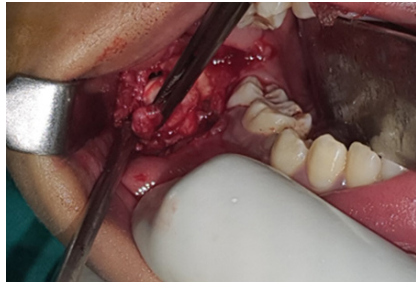

Figure 7. Intra-operative picture - enucleation of cyst.

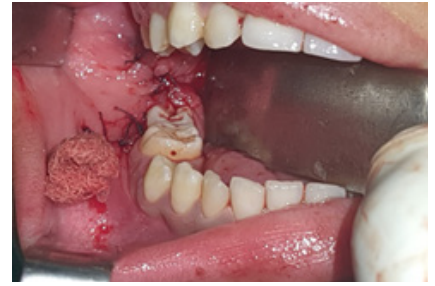

Figure 8. Intra-operative picture - suturing and closure of surgical site.

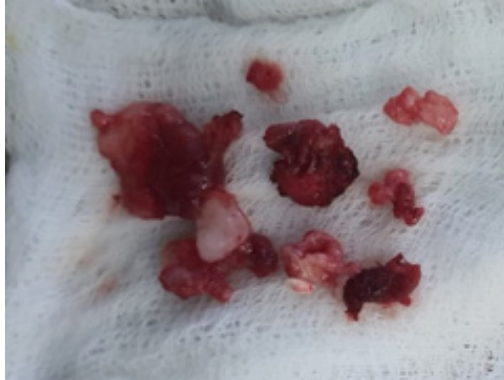

Figure 9. Enucleated cystic mass with extracted 48.

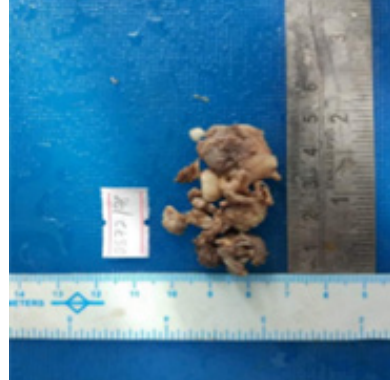

Figure 10. Macroscopy of the cystic lesion

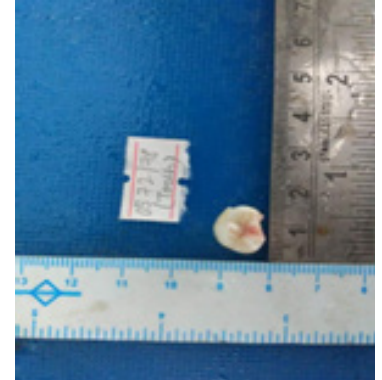


Figure 11. Macroscopy of extracted 48.

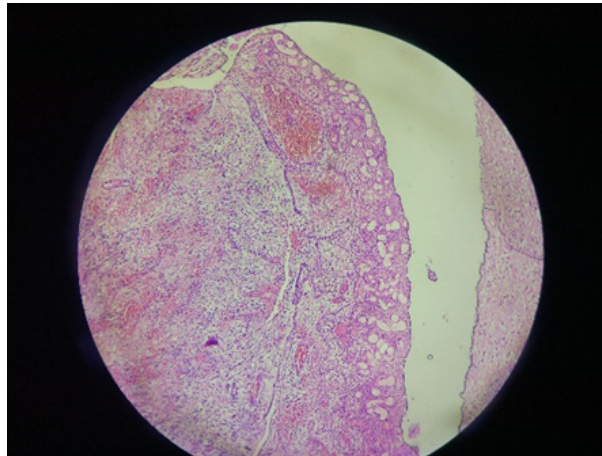


Figure 12. Histological section of the specimen showing hyperplastic epithelial lining of dentigerous cyst and underlying connective tissue (H&E staining, original magnification 10x).

DISCUSSION

Kramer (1974) has defined a cyst as a pathological cavity having fluid, semifluid or gaseous contents which is not created by the accumulation of pus.³ The prevalence of cysts in the jaws is usually related to the proliferation of abundant epithelium in the bone during the process of tooth formation and along the lines where the surfaces of embryologic jaw processes fuse.⁴

DC also known as “follicular cyst” is an odontogenic cyst of developmental origin. It is usually detected as an accidental finding when radiographs are taken to investigate the adjacent tooth for either being infected, carious, or mal-aligned. These cysts are known to enclose impacted, embedded, or submerged tooth by the expansion of its follicle.⁵ In this case bony expansion was seen with swelling of the right cheek in the mandibular area which was firm, hard and tender. Buccal bony expansion and

a missing tooth are the most common clinical features.⁶ The normal follicular space is approximately 3-4 mm but in case of dentigerous cyst, it is more than 5 mm⁵ and in this case, the size of the cyst was 27.6 mm x 21.5 mm radiographically thus implying that it was a dentigerous cyst.

The accumulation of fluid between the reduced enamel epithelium and the enamel or between the layers of the enamel organ is the most common pathogenesis of dentigerous cyst.⁶ In this case, pus discharge was not seen on clinical examination but during enucleation, fluid discharge was appreciated from the cystic lesion.

Expansion of the DC is related to epithelial proliferation, release of bone-resorbing factors³ like prostaglandins (PG) E2 and E3, interleukin-1(IL-1) and an increase in cyst fluid osmolality. In this case, bony expansion was observed which on histopathological examination also depicted hyperplastic epithelium. This might suggest the association between epithelial proliferation and expansion. Continued expansion of this cyst can lead to consequences like expansion of bone with facial asymmetry, extreme displacement of teeth, and less commonly pain. "Hollowing-out" of the entire ramus is seen due to pressure exertion by the cystic lesion associated with impacted third molar.⁷

The radiographic features of these dentigerous cysts includes the presence of a unilocular radiolucent lesion of varying size, with well-defined sclerotic borders around the crown of an unerupted permanent tooth.¹ This case showed spherical, well-demarcated unilocular lesion surrounding tooth 48 whose root was not developed, showing the features of DC. According to the location of radiolucency around the crown of an unerupted tooth, there are three main variants and they are central type, lateral type, and circumferential types.⁸ The present case falls under central type where the tooth crown is seen to be enclosed by the radiolucency and the crown protrudes into the cystic lumen.⁹

The histopathological image of cyst evaluated in this case report showed non-keratinized stratified squamous epithelium with epithelial hyperplasia and arched with areas of inflammation.³ Hence, the diagnosis as infected dentigerous cyst was made.

There are many treatment modalities which include decompression, marsupialization and complete enucleation. Before considering the treatment options, many factors are to be kept in mind such as age of the patient, location of the cyst, tooth position and its relation to the cyst and root formation of the involved tooth.

In this case, root of the third molar was not developed and there was no destruction of the nearby vital structures, thus enucleation of the cystic lesion followed by extraction of the involved third molar was done as suitable and approachable treatment. Motamedi and Talesh (2005)³ have reported treating 40 large dentigerous cysts involving three or more teeth. They reported that dentigerous cysts were usually easy to treat when small, but were difficult to manage when extensive. Cyst enucleation along with extraction of the impaction(s) was indicated among 34 patients.³ In those patients the impacted teeth were deemed unlikely to be useful, or lacked space for eruption.³ If the cyst is very large and preservation of the displaced teeth is to be considered then marsupialization is rather a better and conservative treatment option.⁶

Diagnosing and discriminating DC from an enlarged dental follicle, keratocystic odontogenic tumor, ameloblastic fibroma, unicystic ameloblastoma, adenomatoid odontogenic cyst, and calcifying odontogenic cysts is very important, hence careful observation of factors such as size, site of attachment with the involved tooth, and internal contents aids in proper diagnosis of the pathology.⁷ According to Muller and Waldron, 70% of primary intraosseous carcinomas develop from pre-existing cysts, accounting for 1 to 2% of overall oral cancers. However, it has been reported that up to 50% of central mucoepidermoid carcinoma originates from odontogenic cysts or impacted teeth.¹⁰ Thus, early diagnosis and proper treatment plan should be made to prevent further expansion of the lesion which may lead to "hollowing out" of the entire ramus and complicated treatment needs.

CONCLUSIONS

Dentigerous cyst is one of the commonly occurring odontogenic cysts seen in routine dental radiographs. However, it is important to note that neoplastic transformation (benign or malignant) is possible in due course of time. Thus, it's very important to make an early

diagnosis and proper treatment plan. Here, the location of the cyst and its involvement with an unerupted third molar led us to adopt the surgical procedure of enucleation of the cystic lesion along with extraction of the offending tooth. CBCT as diagnostic imaging tool was very much useful in surgical planning. Regular follow ups with radiographic

review are necessary as the accidental remnants of cystic lining during surgery can bring about malignant changes.

Conflict of Interest: None

INAPD

REFERENCES

1. Kasat VO, Karjodkar FR, Laddha RS. Dentigerous cyst associated with an ectopic third molar in the maxillary sinus: A case report and review of literature. *Contemp Clin Dent.* 2012 Jul;3(3):373-6. [[PubMed](#) | [DOI](#)]
2. Rajae EG, Karima EH. Dentigerous cyst: enucleation or marsupialization? (a case report). *Pan Afr Med J.* 2021 Nov 10;40:149. [[PubMed](#) | [Full Text](#) | [DOI](#)]
3. Shear M and Speight PM. In: *Cysts of the Oral and Maxillofacial Regions.* 4th ed. Singapore: Blackwell Munksgaard; 2007. Retrieved 18 October 2021. Available from: https://www.academia.edu/39842475/Cysts_of_the_Oral_and_Maxillofacial_Regions_4th_Edition. [[Full Text](#) | [Link](#)]
4. James RH, Edward E III, Myron RT. *Contemporary oral and maxillofacial surgery.* 5th ed. Mosby Elsevier; c2008. p. 453-59. Retrieved 21 October 2021. Available from: <https://catalog.lib.uchicago.edu/vufind/Record/7297221/TOC>. [[Link](#)]
5. Shear M. *A textbook of Cysts of the oral regions.* 3rd ed. Oxford: Wright; 1992. p. 75–98. Retrieved 18 October 2021. Available from: https://scholar.google.com/scholar_lookup?title=A+textbook+of+Cysts+of+the+oral+regions,&author=M.+Shear&publication_year=1992;& [[Link](#)]
6. Bhardwaj B, Sharma S, Chitlangia P, Agarwal P, Bhamboo A, Rastogi K. Mandibular dentigerous cyst in a 10-year-old child. *Int J Clin Pediatr Dent.* 2016 Jul-Sep;9(3):281-4. [[PubMed](#) | [DOI](#)]
7. Goel A, Patil P, Bansal R, Sabharwal R. Dentigerous cyst involving mandibular third molar: Conservative treatment with radiologic follow-up and review of literature. *Clin Cancer Investig J.* 2013;2:233-6. [[Full Text](#) | [DOI](#)]
8. Deepa KK, Jannu A, Kulambi M, Shalini HS. A case of dentigerous cyst in a pediatric patient-With an insight into differential diagnostic entities. *Advances in Oral and Maxillofacial Surgery.* 2021 Jul-Sep;1(3):100130. [[Full Text](#) | [DOI](#)]
9. Hasan S, Ahmed SA, Reddy LB. Dentigerous cyst in association with impacted inverted mesiodens: Report of a rare case with a brief review of literature. *Int J Appl Basic Med Res.* 2014 Sep;4(Suppl 1):S61-4. [[PubMed](#) | [DOI](#)]
10. Borrás-Ferreres J, Sánchez-Torres A, Gay-Escoda C. Malignant changes developing from odontogenic cysts: A systematic review. *J Clin Exp Dent.* 2016 Dec 1;8(5):e622-e628. [[PubMed](#) | [DOI](#)]