



## Iatrogenic Displaced Maxillary Third Molar Tooth

Surendra Kumar Acharya<sup>1</sup>, Ongkila Bhutia, Ajoy Roychoudhury, Rahul Yadav, Ankit Arora, Babu Lal

<sup>1</sup>Department of Oral and Maxillofacial Surgery, KISTMCTH, Kathmandu, Nepal.

### ABSTRACT

Minor to major complications may occur during the third molar extraction but should be optimized. Surgeons should know how to diagnose the case and manage the complications. We hereby report one of the rare complications of upper third molar extraction; iatrogenic displacement in infratemporal space. We emphasized hence on management of such technically sensitive case using 3D virtual surgical planning. The use of computer-assisted three-dimensional surgical planning to reconstruct the tooth in its localized position and orientation makes the operation more accurate, more convenient, and avoids damage to vital structures.

**Keywords:** 3D virtual planning; Infratemporal space; Maxillary third molar.

### INTRODUCTION

Complications rate associated with extraction of third molar tooth ranges from 2.6% to 30.9 %.<sup>1</sup> The most common complications are hemorrhage, pain, infection, trismus, fracture of root and maxillary tuberosity, prolapsed of buccal pad of fat, maxillary sinus perforation and displacement in maxillary sinus, infratemporal space, pterygomandibular space. Displacement is usually iatrogenic.<sup>2</sup> Commonly used radiographic methods are orthopantomogram, cone beam computerized tomography and computerized tomography.<sup>3</sup> Computer-assisted surgical planning and simulation have been extensively used in field

of Oral and Maxillofacial Surgery for a wide range of conditions.<sup>4</sup> However, there have been no reports of the computer-assisted preoperative planning of management of displaced third molar. Here we report a case of iatrogenically displaced maxillary third molar tooth and management using 3d virtual surgical planning.

### CASE REPORT

A 32 year-old female reported to department of Maxillofacial Surgery with problem of reduced mouth opening and swelling in left cheek region for about 20 days. On examination there was diffuse swelling in

**Citation:** Acharya SK, Bhutia O, Roychoudhury A, Yadav R, Arora A, Lal B. Iatrogenic Displaced Maxillary Third Molar Tooth .JKISTMC 2020;2(2)4: 84-86

### Correspondence

Dr. Surendra Acharya

Lecturer, Department of Oral and Maxillofacial Surgery  
KISTMCTH, Kathmandu, Nepal

Email : surendra.arogin@gmail.com ,info@drsuredraomfs.com

Mobile: +977 9863032533

Conflict of interest: None

Source of support: None

### Article info

Received: 24 June, 2020.

Accepted: 7 July, 2020.

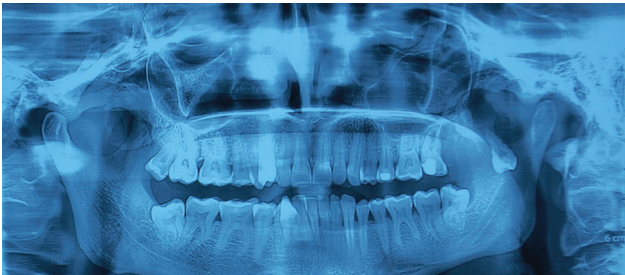Published: 31 July, 2020.

### Copyright

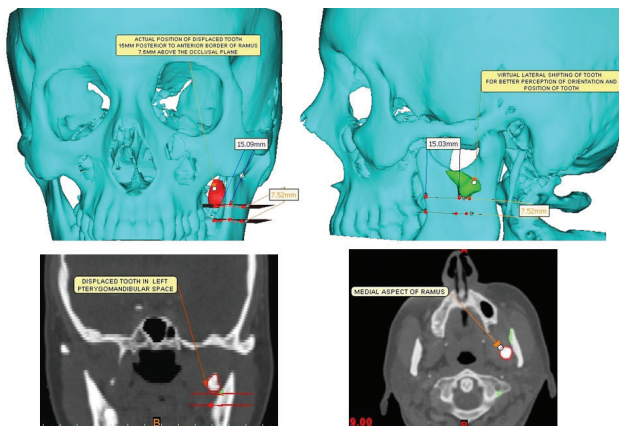
JKISTMC applies the Creative Commons Attribution- Non Commercial 4.0 International License (CC BY) to all works we publish. Under the CC BY license, authors retain ownership of the copyright for their article, but authors allow anyone to download, reuse, reprint, distribute, and/or copy articles in JKISTMC, so long as the original authors and source are cited.



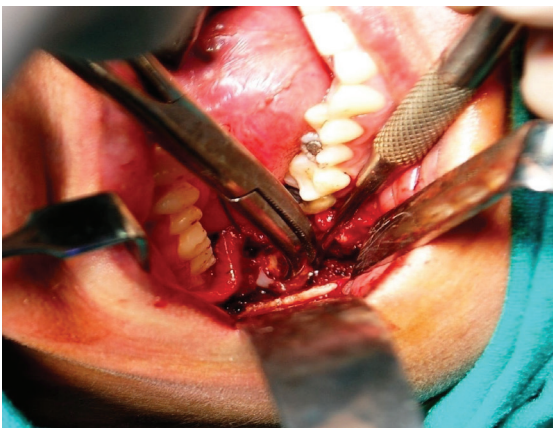
left buccal and posterior maxillary region and mouth opening was 15 mm. For the diagnostic purpose orthopantomogram was done (Figure 1). The slice data are acquired using a helical, high resolution CT at 0.5 mm intervals, stored in Digital Imaging and Communications in Medicine (DICOM) format, and then imported into a Mimics® software package (Materialise NV, Leuven, Belgium), which enables the imported data to be viewed in the sagittal, coronal, and axial planes. This 3D virtual pre surgical planning allows accurate and intuitive three-dimensional orientation and position of displaced tooth to optimize surgical approach.



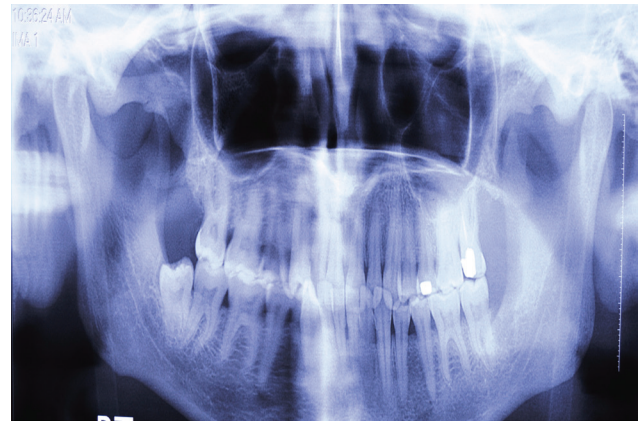
**Figure 1. Pre operative orthopantomogram.**



**Figure 2. 3D virtual model showing the displaced tooth.**



**Figure 3. Vestibular approach and tooth removal using hemostat forceps.**



**Figure 4 .Post operative orthopantomogram.**

We segmented the DICOM data in such a manner that only bone and tooth material formed the expected 3D virtual model. Displaced tooth was located in left infratemporal space in oblique manner with occlusal surface oriented downward and posteriorly and root tip oriented upward and anteriorly. Tooth has single fused root and is positioned about 15 mm from anterior border of ramus, 7.5 mm above the occlusal surface and lateral surface of tooth crown just touching the medial surface of ramus above the level of lingula. Virtually tooth was shifted laterally out of ramus in parallel direction for better perception of orientation and location (Figure 2).

We have applied whole virtual planning to intraoperative procedure and exploration and retrieval of displaced tooth was done via intraoral standard posterior buccal vestibular approach extended up to anterior border of ramus and posterior surface of maxilla, under general anaesthesia. After tissue dissection inferior alveolar nerve was protected, the tooth was visualized and removed by curved hemostat forceps without any added procedure (Figure 3). Orthopantomogram confirmed complete extraction of the tooth (Figure 4). Follow up of six months revealed patient's swelling subsided and significant improvement of mouth opening.

## DISCUSSION

Displacement of maxillary third molar occurs buccally in the maxillary sinus, and palatally. Furthermore, maxillary teeth that are trapped under the mucoperiosteal flap may be pushed during attempts of retrieval as in present case. Such intricacies can be prevented by taking absolute care during extraction with use of distal retractor (Laster retractor).

The surgical approaches for retrieval of displaced maxillary third molars are intraoral vestibular<sup>5</sup>, Caldwell-luc, Gillie's temporal, hemicoronal<sup>6</sup>, bicoronal<sup>7</sup>. Immediate removal can avoid subsequent hospitalization, associated complications and financial inconvenience for the patient.

Despite the use of ultrathin CT slices, they may not provide accurate representation of the tooth's true anatomy. Virtual surgical planning is becoming more common in a number of surgical scenarios. Various software allows a large degree of versatility that was not previously possible with orthodox models and techniques.<sup>8</sup> In this case, three dimensional virtual planning was recommended to use for reduction of operative time, accurate surgical guide and approach which in turn helps to prevent important structures. It also helped in providing orientation, which further strengthen confidence, to the patient who was already in mental traumatic state after going through failed procedures.

Displacement of maxillary third molar into infratemporal space is a rare but serious complication. With the application precise surgical technique and 3D virtual planning we can extract tooth accurately without causing further complications.

## REFERENCES

1. Primo BT, Stringhini DJ, Kluppel LE, Da Costa DJ, Rebellato NLB, Moraes RS de. Delayed removal of maxillary third molar displaced into the infratemporal fossa. *Rev Esp Cir Oral Maxillofac Surg*. 2014; 36(2):78-81.
2. Bui CH, Seldin EB, Dodson TB. Types, frequencies, and risk factors for complications after third molar extraction. *J Oral Maxillofac Surg*. 2003; 61(12):1379-1389.
3. Patel M, Down K. Accidental displacement of impacted maxillary third molars. *Br Dent J*. 1994; 177(2):57-59.
4. Ren W, Gao L, Li S, et al. Virtual Planning and 3D printing modeling for mandibular reconstruction with fibula free flap. *Med Oral Pathol Oral Cirurgia Bucal*. 2018; 23(3):e359-66.
5. Sverzut CE, Trivellato AE, Sverzut AT, de Matos FP, Kato RB. Removal of a maxillary third molar accidentally displaced into the infratemporal fossa via intraoral approach under local anesthesia: report of a case. *J Oral Maxillofac Surg*. 2009; 67(6):1316-1320.
6. Gulbrandsen SR, Jackson IT, Turlington EG. Recovery of a maxillary third molar from the infratemporal space via a hemicoronal approach. *J Oral Maxillofac Surg*. 1987; 45(3):279-282.
7. Gomez-Oliveira G, Arribas-García I, Alvarez-Flores M, Gregoire-Ferriol J, Martínez-Gimeno C. Delayed removal of a maxillary third molar from the infratemporal fossa. *Med Oral Pathol Oral Cir Bucal*. 2010; 15(3):e509-11.
8. Haq J, Patel N, Weimer K, Matthews NS. Single stage treatment of ankylosis of the temporomandibular joint using patient-specific total joint replacement and virtual surgical planning. *Br J Oral Maxillofac Surg*. 2014; 52(4):350-355.