

Case Report

Traumatic abdominal wall hernia Repair: An Experience in remote hospital of karnali Academy of health science Teaching Hospital.

Menyangbo S, Devkota H, Neupane M

Department of General surgery, karnali Academy of health science Teaching Hospital, Jumla Nepal

Correspondence: Dr. Suryaman Menyangbo

Email: suryaman77@gmail.com

Introduction

Traumatic abdominal wall hernia (TAWH) is a rare event and is caused by blunt trauma to the abdomen. Although, TAWH was first explained by Selby a century ago, fewer cases have been reported in English literatures [1]. TAWH is defined as “Herniation through disrupted fascia along with musculature, associated with adequate trauma, without skin penetration and no evidence of a prior hernia defect at the site of injury”[2]. Skin can be bruised but normally remains intact. Most TAWH are diagnosed on presentation with contrast enhanced computed tomography of abdomen in advanced center, however, the clinical examinations and high index of suspicion in blunt abdomen trauma can be considered as an important method for diagnosis where no CT is available, and most authors advocate immediate laparotomy if high incidence of intra-abdominal injuries is in favor. We present one case of TAWH managed by only meshplasty, 6 days after initial trauma.

Case presentation

A 35 years old slim male, presented to emergency after a hit by a flying stone 6 days ago. He was conscious, oriented and complained of right sided abdominal pain. On examination his pulse was 102/min and blood pressure was 125/74 mm Hg. Initial survey of the abdomen revealed a mild swelling over right flank extending over to right inguinal with abrasion and ecchymosis of the overlying skin. The swelling was tender but was soft and cystic. There was no guarding

or rigidity over the abdomen. Examination of all other systems was unremarkable. An initial diagnosis of subcutaneous hematoma was made and patient was assessed further in details when he complained of swelling on right lower hypogastric region as he was to discharge.

His hemoglobin was 15.4 gm/dl and rests of the haematological profiles were within normal range. Skeletal survey did not reveal any bony injury. Focus ultrasound of the abdomen revealed no free fluid in abdominal cavity. Routine urine examination also showed negative for blood. As CT is not available in our hospital, we suspected of local hematoma. As the swelling is cystic in nature, reduced on given-pressure and USG negative for local collection over swelling area, a high index of suspicion of hernia due to trauma was made. A final diagnosis of TAWH was confirmed after the exploration (Fig. 2).

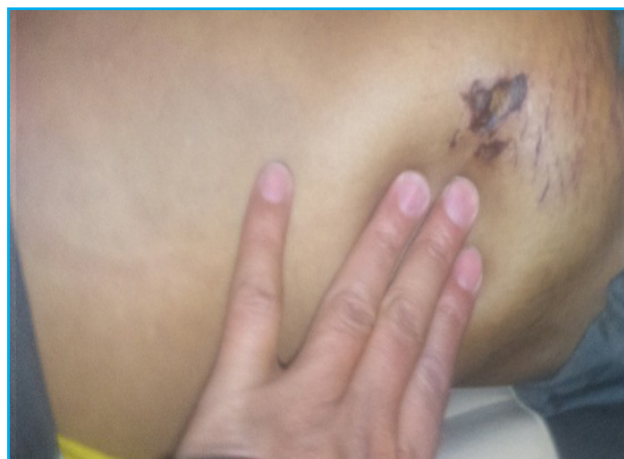

Fig. 1. Showing hernial defect before exploration

In view of early presentation and a small overlying skin with abrasion, a decision was made to mesh repair. Patient was taken up for surgery. He was positioned in supine position and with a transverse incision overlying the defect, the skin was opened. As the skin was opened, we tried to find the subsequent layer of external oblique aponeurosis, internal oblique muscle and transversus fascialis but there were none. The thin layer peritoneum was the first layer seen during dissection. A defect of 3 cm × 4 cm was found extending from lateral border of rectus anteriorly to anterior axillary line posteriorly in transverse axis and from 3 cm down costal margin to inguinal ligament in craniocaudal axis was present. Defect was lined by rectus muscle in the anterior midline, few part erector spinae muscle posteriorly, 3 cm downright costal margin cranially and inguinal ligament caudally. Rectus muscle of ipsilateral side was normal with good fascia. The oblique muscles were completely disrupted with no adequate fibres. Through this defect, in the subcutaneous plane, there was a peritoneum sac containing loops of small bowel and clear straw colored fluid (Fig. 2). Dissection done between peritoneum and subcutaneous tissue towards lateral side as far as possible and towards medial side upto the lateral border of rectus muscle transversely and upto 3 cm down costal margin and just above inguinal ligaments cranio-caudally made a space of 6cm × 7cm. There was no way to close or even approximate this defect in muscular level. The open peritoneum of hernial sac was approximated to each other. A 6cm × 7cm prolene mesh was placed onlay over the peritoneum and sutured to the margins of the defect as well as the mesh was sutured with the subcutaneous tissue (Fig. 3). The overlying skin approximated with interrupted prolene suture. Thus we were able to close the muscular defect with help of a mesh and manage to place mesh between peritoneum and subcutaneous tissue.

Patient was cared in surgical ward for 3 days. On 4th post-operative day he developed superficial bluish skin below the incision site as well as redness at the ecchymosed skin, quite horrified of developing mesh infection. But, daily dressing with IV antibiotic controlled the redness. On 7th post-operative day he was discharged in healthy condition [Fig. 4].

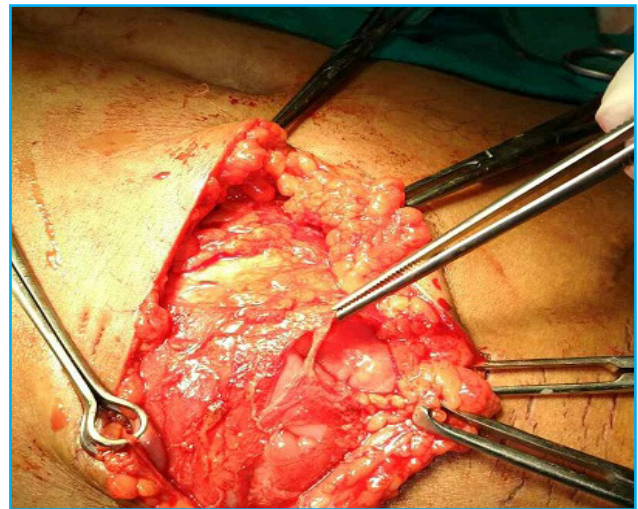


Fig. 2 Intraoperative picture showing hernial sac

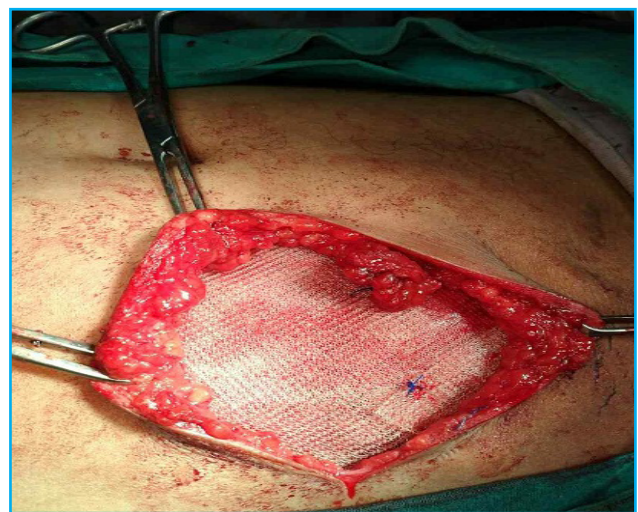


Fig. 3 Intraoperative photograph showing prolene mesh being fixed.

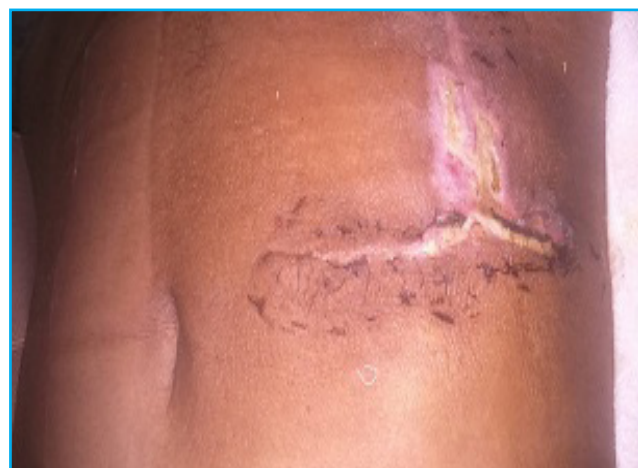

Fig. 4 Post discharge picture

Discussion

Although blunt trauma is not uncommon, TAWH remains rare. It involves application of blunt force to the abdomen over an area large enough to prevent skin penetration. These tangential force is an ultimate culprit to cause pressure induced disruption of abdominal wall muscles and fascia and result in a hernia [3]. As skin is more elastic than other layers it remains intact. Although, most TAWH are reported following high velocity vehicle accidents, seat belt or handle bar injuries in city, however, it should be also considered TAWH in blunt abdominal trauma post hit by a fall stone. Herniation is seen at anatomically weak points due to blow out and not at site of injury [4]. TAWH usually occur either lateral to the rectus, in lower abdomen or in inguinal region.

Wood et al. [5] classified TAWH in 3 major types: Type I: sustained from high energy injuries and are commonly associated with intra-abdominal injuries. Type II: sustained due to low energy injuries example handle bar hernias. Type III: resulted from deceleration injuries and are associated with intra-abdominal Herniation.

Although TAWH usually present as tender palpable lump with ecchymosis of overlying skin, CT scan is the most accurate diagnostic tool [6]. It can define the anatomy of disrupted abdominal wall, differentiates hernia from hematoma and identifies intra-abdominal injuries. However, clinical findings such as swelling with ecchymosis after a high velocity trauma and high index of suspicion are helpful in places where there is no facility for CT scan.

Surgery is primary modality of treatment which can be emergent or delayed. Probability of intra-abdominal injuries plays the most important role in deciding the timing of operative intervention. Immediate exploration with hernia repair is generally accepted as favorable choice as it allows to rule out any intra-abdominal injury and prevents strangulation of herniated bowel which may occur hours to days after injury [7,8]. The period of hospitalization and disability is also shortened. But debridement of devitalized tissue may be required and placement of mesh is contraindicated due to fear of infectious

complications. Most authors have reported immediate exploration with layer-by-layer closure of defect with or without mesh as the preferred procedure. However, patients with large defects (low chances of strangulation and no intra-abdominal injuries) can be managed by delayed elective repair [9,10]. The only possibility in large hernias if repaired under tension may cause abdominal compartment syndrome. In this case the defect was not so large and CT was not available to fully know the herniated anatomy decision was made for mesh Repair.

Type of incisions, suture material to be used and the role of mesh are also debatable issues. In emergency settings, one may prefer midline incisions as exploration of intra-abdominal injuries is easier and defect can be repaired from inside [10]. However, as in present case, a transverse incision overlying the defect is preferred [11]. Choice of suture material depends on surgeon's preference and most authors advocate use of non-absorbable monofilament for repair of the defect [3]. Mesh is usually preferred if defect is large or musculature is weak [11] but layer by layer closure without tension also provides acceptable results [12]. Use of mesh is contraindicated in patients with associated bowel perforations or necrotic tissue due to chances of infectious complications.

Thus, there is no defined protocol for surgical management but most authors advocate emergency exploration using midline incision and repair with non-absorbable suture and mesh.

Conclusion

TAWH, although rare, should be thought with high index of suspicious in all cases of high velocity injuries with abdominal wall swellings and ecchymosis where CT is unavailable for diagnosis. Emergency midline exploration with examination of abdominal contents and repair of hernia with non-absorbable sutures with or without use of mesh is favored. Delayed repair may be considered in selected cases but the hernia may enlarge and defect may widen over time, making repair technically demanding and exhaustive. Thus,

TAWH are best managed surgically repairing as early as trauma if not contraindicated.

Written consent was obtained from the patient for publication of this case report and accompanying images.

References

1. Selby C.D. Direct abdominal hernia of traumatic origin. *JAMA*. 1906; 47:1485-1486.
2. Damschen D.D et al. Acute traumatic abdominal hernia: case reports. *Journal of trauma*. 1994;36: 273-276
3. Shiomi H et al. Handle bar hernia with intra-abdominal extra luminal air presenting as novel form of traumatic abdominal wall hernia: report of a case. *Surgery Today*. 1999; 29:1280–1284.
4. Ganchi P.A., Orgill D.P. Auto penetrating hernia: a novel form of traumatic abdominal wall hernia: case report and review of literature. *Journal of Trauma*. 1996; 41:1064–1066.
5. Wood R.J., Ney A.L., Bubrick M.P. Traumatic abdominal hernia: a case report and review of literature. *American Surgeon*. 1988; 54:648–651.
6. ME baker et al. Lumber hernia: diagnosis by CT. *American journal of Roentgenology*. 1987;565-567.10.2214?ajr.148.3.565
7. Tan et al. Traumatic abdominal wall Herniation. *Singapore Medical Journal*. 2007; 48:e270–e272.
8. Lane et al. Management of traumatic abdominal wall hernia. *American Surgeon*. 2003; 69:73–76.
9. Sahdev, P., Garramore, R.R. Jr., Desani, B., Ferris, V., Welch, J.P. Traumatic abdominal hernia: report of three cases and review of literature. *American Journal of Emergency Medicine*. 1992; 10:237–241.
10. Kubalak, G. Handlebar hernia: Case report and review of the literature. *Journal of Trauma*. 1994; 36:438–439.
11. Drago, S.P., Nuzzo, M., Grassi, G.B. Traumatic ventral hernia: report of a case, with special reference to surgical treatment. *Surgery Today*. 1999; 29:1111–1114.
12. Mahajana, A., Ofer, A., Krausz, M.M. Traumatic abdominal hernia associated with large bowel strangulation: case report and review of literature. *Hernia*. 2004; 8:80–82.