

Case Report

Tuberculous pericarditis: a case report

Paudel S¹, Pal A², Neupane M³

1. Lecturer, Department of Internal Medicine, 2. Lecturer, Department of Surgery, Karnali Academy of Health Sciences, Jumla, Nepal

Corresponding author: Dr. Sunanda Paudel

Email: sunandabishal0@gmail.com

Introduction

Tuberculous pericarditis is caused by Mycobacterium Tuberculosis, it is found in approximately 1% of all cases of tuberculosis and 1 to 2% of cases of pulmonary tuberculosis.¹ It can be fatal even with proper diagnosis and treatment.² Although there has been a significant decline in wealthy industrialized countries over years, Africa, Asia and Latin America with 86% of world's population, comprise 95% of all cases of tuberculosis and 98% of nearly 2 million fatalities from the tuberculosis each year.³

We are reporting this case because the patient was diagnosed and managed in the resource limited settings, guided mostly by clinical judgement and there has been a good response to therapy.

Case Presentation

A 35 years male, without past comorbid medical conditions, presented to our outpatient clinic with the history of nonproductive cough associated with pleuritic chest pain for 3 months. Patient also had progressive dyspnea for the same duration. Patient had low grade fever associated with night sweats and had anorexia with weight loss of 10 kg within that period. On examination, he was tachypneic with raised jugular venous pressure, however, he had blood pressure of 100/70mmHg. Cardiac auscultation revealed normal first and second heart sound and the presence of pericardial friction rub.

Patient was then evaluated with available laboratory tests and radiological imaging. Chest radiograph revealed cardiomegaly with globular heart shadow.

Since echocardiogram was not available in our setting, he underwent cardiac ultrasound screening which revealed the presence of pericardial collection suggestive of pericardial effusion. Then patient was advised for further evaluation with echocardiogram followed by pericardiocentesis in other centers with available facility but was unable to do so because of his personal constraints.

Patient was informed about his current disease condition and probable future outcome. Then he was planned for antitubercular treatment along with a course of steroids with presumed diagnosis of tuberculous pericarditis based upon his clinical and supportive imaging clues.

During follow up with the antitubercular treatment, patient was found to be clinically improving and became afebrile with improvement in clinical symptoms of dyspnea and had weight gain and better appetite. His follow up x-ray revealed signs of improvement with regression of cardiomegaly. Hence, patient was continued with antituberculous treatment.

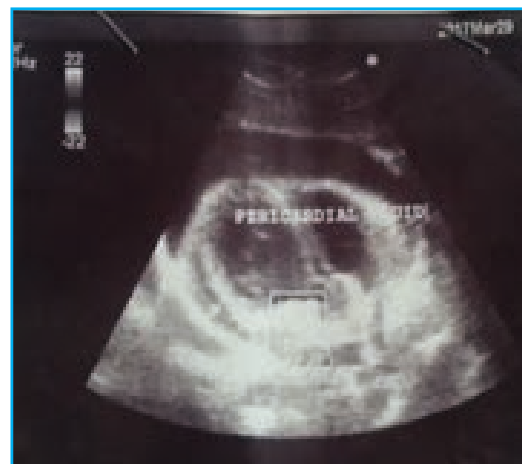

Figure 1. Ultrasound scan of heart showing fluid collection in the pericardial space

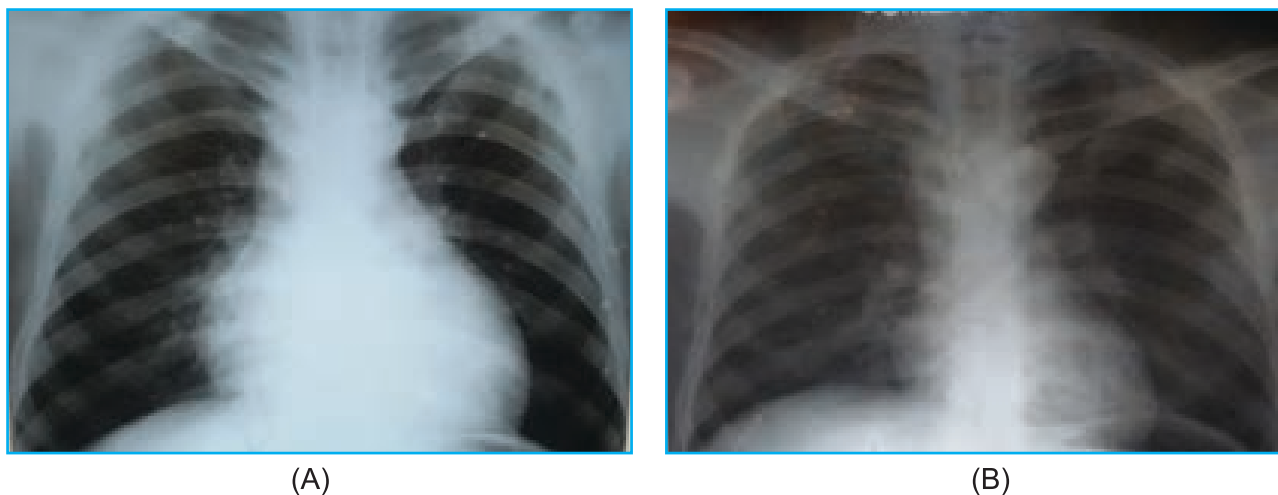


Figure 2. Chest x-ray PA view of the patient at presentation and after 2 months of therapy:
(A) Before treatment: with cardiomegaly
(B) After 2 months of treatment: reduced cardiac size

Discussion

Pericardial tuberculosis is a rare manifestation of extrapulmonary tuberculosis. It has an incidence of 1 to 4% of all cases of pericarditis and usually develops by dissemination of mediastinal lymph nodes, lung, spine, sternum or during miliary infection. Tuberculous pericarditis has variable clinical presentation and should be considered while evaluating patients with pericarditis.⁴ Early diagnosis and treatment is important because it may complicate into constrictive pericarditis in upto 30 to 60 percent of the patients, despite prompt antituberculous therapy and use of corticosteroids.⁵

Symptoms in patient with tuberculous pericarditis can be non specific; fever, weight loss, and night sweats generally precede cardiopulmonary symptoms like dyspnea, chest pain and orthopnea.⁶ Physical findings in patients with tuberculous pericarditis usually are fever, tachycardia, elevated jugular venous pressure, hepatomegaly, ascites and peripheral edema.⁷ A pericardial friction rub and distant heart sounds are often found.⁸ In advanced stage, heart failure may be present.⁹

Tuberculous pericarditis should be considered in the evaluation of patients with pericarditis who do not have self limiting course and in the settings of risk factors for tuberculosis exposure.⁵ The diagnosis is established by detection of tubercle bacilli in smear

or culture of pericardial fluid and/or by detection of tubercle bacilli or caseating granuloma on histological examination of the pericardium. Pericardial biopsy or lymph node biopsy may be considered if diagnosis remains uncertain after initial evaluation for tubercle bacilli in sputum, pericardial fluids or other body sites specimen. For patients in areas where TB is endemic and for whom clinical suspicion of tuberculous pericarditis is high, pericardial biopsy may not be required prior to starting empiric antituberculous therapy.¹⁰

Tuberculous pericarditis is treated with antituberculous therapy and has been shown to dramatically reduce mortality.¹¹ The treatment approach of tuberculous pericarditis is same as pulmonary tuberculosis.¹² Adjunctive corticosteroids may have a role in preventing constrictive pericarditis and can be used selectively in patients with highest risk of inflammatory complications.¹³

Our case was evaluated in a resource limited clinical setting with associated patient constraints, moreover, he had history and clinical examination findings suggestive of tuberculosis with pericardial involvement. Ultrasound screening and chest radiograph findings were also supportive of pericardial involvement. Then patient was started with antituberculous treatment on the basis that of

probable high endemicity of tuberculosis in this part of our country. Patient showed significant signs of both clinical and radiological improvement after initiation of antituberculous treatment. Hence, in resource limited clinical setting, thorough history and clinical examination including use of simple tests may be of importance in diagnosing and treating tuberculous pericarditis.

References

1. Denk A, Kobat MA, Balin SO, Kara SS, Dogdu O. Tuberculous pericarditis: a case report. *Infez Med* 2016; 4:337-39.
2. Traunter BW, Darouiche RO. Tuberculous pericarditis: Optimal Diagnosis and Management. *Clin Infect Dis* 2001; 33:954-61.
3. Wanjari K, Baradkar V, Mathur M, Kumar S. A case of Tuberculous Pericardial Effusion. *Indian J Med Microbiol* 2009;27(1):75-77.
4. Farnetano BDS, Farias ML, Mota GSM, Leao CN, Machareth MMV. Pericardial Tuberculosis: A Case Report. *J Tuberc Ther* 2017;1(1).
5. Sagrista-Sauleda J, Permanyer-Miralda G, Soler-Soler J. Tuberculous Pericarditis: ten year experience with a prospective protocol for diagnosis and treatment. *J Am Coll Cardiol* 1988; 11:724.
6. Diagnostic Standards and Classifications Tuberculosis in Adults and Children. This official statement of American Thoracic Society and the Centers for Disease Control and Prevention was adopted by the ATS Board of Directors, July 1999. This statement was endorsed by the Council of the Infectious Disease Society of America, September 1999. *Am J Respir Crit Care Med* 2000; 161:1376.
7. Fowler NO, Manitsas GT. Infectious pericarditis. *Prog Cardiovasc Dis* 1973;16:323.
8. Strang JI, Kakaza HH, Gibson DG, et al. Controlled clinical trial of complete open surgical drainage and of prednisolone in treatment of tuberculous pericardial effusion in Transkei. *Lancet* 1988;2:759.
9. Desai HN. Tuberculosis Pericarditis. A review of 100 cases. *S Afr Med J* 1979; 55:887.
10. Mayosi BM, Burgress LJ, Doubell AF. Tuberculous pericarditis. *circulation* 2005; 112:3608.
11. Ortbals DW, Avioli LV. Tuberculous pericarditis. *Arch Intern Med* 1979; 139:231.
12. Nahid P, Dorman SE, Alipanah N, et al. Official American Thoracic Society/Centers for Disease Control and Prevention/Infectious Disease Society of America Clinical Practice Guidelines: Treatment of Drug-Susceptible Tuberculosis. *Clin Infect Dis* 2016; 63:e147.
13. Mayosi BM, Ntsekhe M, Bosch J et al. Prednisolone and Mycobacterium indicus pranii in tuberculous pericarditis. *N Engl J Med* 2014; 371:112