

Treatment of Morell Lavallee Lesion (MLL) with Arthroscopy

Kandel R¹, Zhang Dezhi², Liu Danping³, Ma Wen⁴, Guo Zhanpeng⁵, Zhang Yuqiang⁶, Yam Gurung⁷, Wang Qian⁸

¹⁻⁸Department of Orthopaedic surgery, the 1st affiliated hospital of Liaoning medical university, jinzhou city, liaoning province, P.R China.

Correspondent Author:

Dr. Rupak Kandel

Email: rpkkd1978@gmail.com

ABSTRACT

Background: Previous approval for treatment of persistent Morell lavallee soft tissue degloving lesion has included open debridement or simple compression or serial aspiration under USG guidance or insertion of surgical vacuum or sclerodesis with tetracycline/doxycycline. None of them had proven the minimally invasive surgical technological effect of arthroscopy.

Purpose of study: This study evaluates the minimally invasive surgical effectiveness and use of radio frequency ablation under arthroscopy for treatment of persistent Morell lavallee soft tissue degloving lesion. This technique provides satisfactory cosmetic and functional effect as overall outcome.

Methods: We treated 7 cases of persistent Morell lavallee lesion between Nov 2010 to March 2013. These lesions developed in 5 male and 2 female patients (Mean age 36.57yr, Range 23-48 yrs) due to various mode of trauma. The lesion involved the thigh region in 3 patients with gluteal, distal leg, knee and forearm being other region involved. An area of palpable fluctuance was the most coherent examination finding. MRI and Ultrasonography confirmed the diagnosis with clinical evidences. Treatment was achieved by placement of arthroscope, aspiration of fluid and radio frequency ablation of inner layer of capsule and proceed with compressive elastic bandaging. Healing was defined as the loss of fluctuation with complete absence of fluid on ultrasonography (USG).

Result: The average duration of the persistence of the lesion was 3 month. All lesions were evacuated arthroscopically and found to be negative on culture. The mean follow up period was 11 month (Range 6-24 month). All patients showed complete resolution of fluid collection and no contour deformity at final follow up. All the lesions healed exclusive of any infections or other complication. No recurrences were detected during the follow up period. A persistent feeling of tightness was the most common problems faced on long term follow up.

Conclusion: The persistent closed degloving lesion can be managed easily, conveniently and effectively with radio frequency ablation under arthroscopy. Patients were satisfied with cosmetic problems like contour deformity, tightness of skin, rough scar mark, diminished sensation and skin mobility at site of lesion.

Keywords: *Morell Lavallee Lesion (MLL), Arthroscopy, Radiofrequency ablation*

INTRODUCTION

The Morel-Lavallee Lesion (MLL) is a post-traumatic soft tissue injury first described by the French Physician Maurice Morell-Lavallee in 1853¹. Morell lavallee lesion are well known to orthopaedic surgeons but are rarely mentioned in the medical literature². MLL is defined as the detachment of skin and subcutaneous tissues from underlying fascia with resultant a closed space in which haematoma and liquefied fat tissues accumulates. Deforming forces of pressure and shear due to direct, tangential trauma result in a closed soft-tissue degloving injury, in which the skin and subcutaneous tissue are separated from the underlying fascia, disrupting the perforating vessels. The space created can fill with blood, lymph and necrotic fat, potentially leading to bacterial colonization and infection. Pseudocysts can form at the site of the original lesion, resulting in recurrent fluid accumulation^{3,4}. Missed diagnosis can lead to delayed presentation as a contour deformity due to local tissue necrosis. Morel-Lavallee lesions have most commonly been reported to involve the soft-tissues surrounding the greater trochanter, the flank, ankle, knee and the buttock^{3,5,6,7,8,9}.

The principles of our management approach are with in cosmetic effectiveness. Historical treatment of a MLL involved open serial debridement with subsequent healing by secondary intension. Recently, there has been a trend toward less invasive approaches like elastic compression bandage; percutaneous drainage with debridement, irrigation and suction drainage, and liposuction or drainage followed by pressure therapy. However MLL injury poses unique challenges on patients cosmetic dissatisfaction like rough scar mark, decreased skin mobility, diminished sensation and contour deformity at lesion site when requiring invasive management for expeditious resolution and return to normal daily lifestyle. So we aim to improve the cosmetic and functional effect by arthroscopic assisted technique.

MATERIALS AND METHOD

We treated 7 persistant Morell lavallee lesion in first affiliated hospital, Jinzhou, China between Nov 2010

to March 2013. These lesions developed in 5 male patients and 2 female patients (Mean age 36.57yr, Range 23-48 year) including 2 fresh trauma and 5 old trauma The average size was 10cm (Range 7-20cm) due to various modes of trauma (crush under a vehicle, games or a traffic accident). The lesion involved in thigh region in 3 patients with gluteal, knee, forearm and distal leg being other regions involved. Two patients had surgery due to pelvic fracture previously. One of them had done twice open debridement for persistent MLL on right medial aspect of thigh (Figure 8) and another had done simple compression and aspiration, which failed due to recurrence. The inclusion criteria were: a persistent Morel-Lavallee lesion for three months after the initial trauma. MRI and Ultrasonography (USG) were routinely performed in all patients to objectify the effusion, clarify its scope and confirm the presence of a capsule¹⁰. The main exclusion criterion was the absence of a capsule on MRI and USG.

Hallmark on examination finding was palpable more squishable fluctuant area and mostly diminished cutaneous sensation on affected area. After clinical assessment MRI and USG has been done to find out actual location, relation with other tissue, grading and amount of fluid collection. On MRI finding, 5 of them were type 3 and remaining 2 were type 2 and 5. Size varying from 7cm to 20 cm, average being 10cm in USG finding.

All patients were admitted and treated with arthroscopy under subarachnoid block (SAB), brachial block (BB) or regional anesthesia according to site of lesion. Under full aseptic technique patients were draped on operation table. A 20ml Syringe was injected into the cavity and fluid was aspirated from it. Than normal saline was injected into the cavity to expand the cavity for proper visualation. 1 cm incision was made at 2 to 3 places.

Treatment was proceed by placement of arthroscope. The cavity was irrigated with normal saline and aspiration of fluid hematoma, hanging fat cells and necrotic debris was done. With the arthroscope, cavity was observed thoroughly. Inside the cavity there were

mixed fluid, bleeding vessels, inflammatory cells and certain secretory cells which were responsible for production of toxic substance and fluid, Debridement of the cavity was done with arthroscopy shaver and with the help of radiofrequency ablation, inner layer of capsule was removed and hemostasis maintained (Figure 3,4,5). Outer layer of capsule was kept intact. For the lesion on gluteal and trochanteric region, excessive sero hemorrhagic fluid was aspirated (Figure1). Cavity was lavaged with normal saline. The incised 1 cm site was sutured with 1 stitch silk and compression bandage was then applied. All lesion were healed properly, non became chronic or repeated and remained sterile.

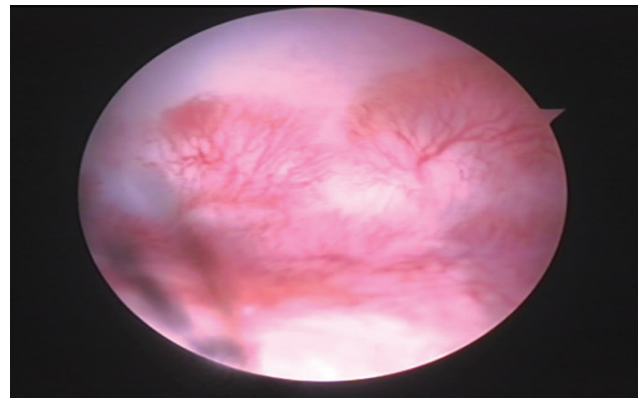


Figure 3: Arthroscopy view showing inner wall of capsule with branching vessels.

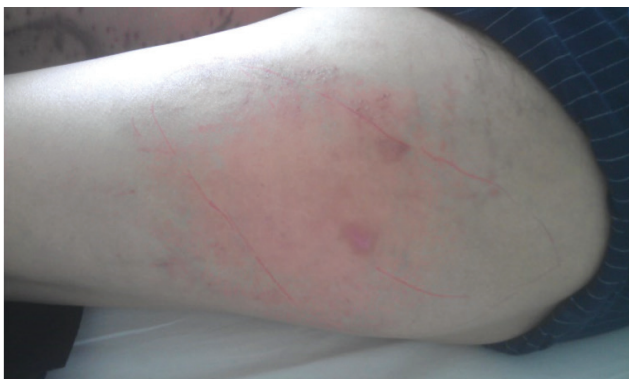

Figure 1: Morell Lavallee lesion at left proximal lateral thigh (preoperatively).

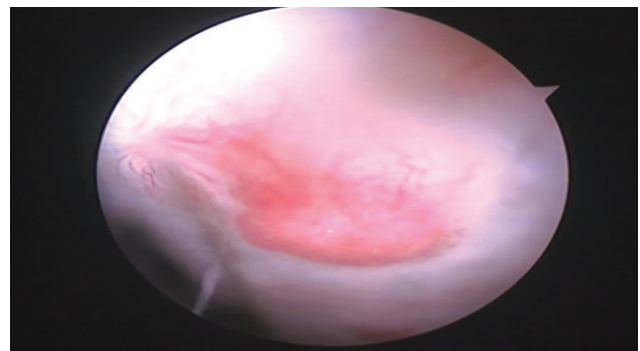


Figure 4: Arthroscopy view showing inner capsule with liquefied fat tissue, inflammatory and secretory cells.

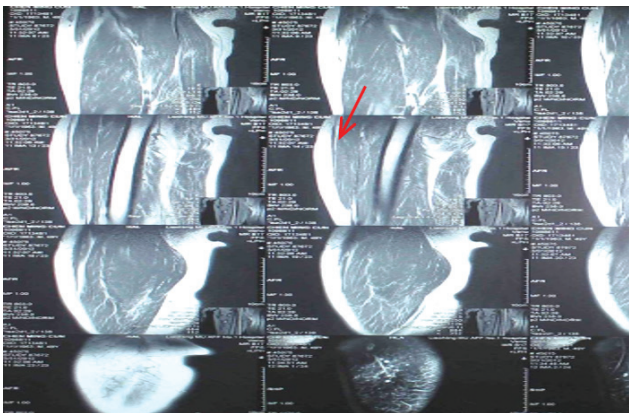


Figure 2: Sagittal MRI view showing degloving lesion at left proximal thigh near greater trochanteric region

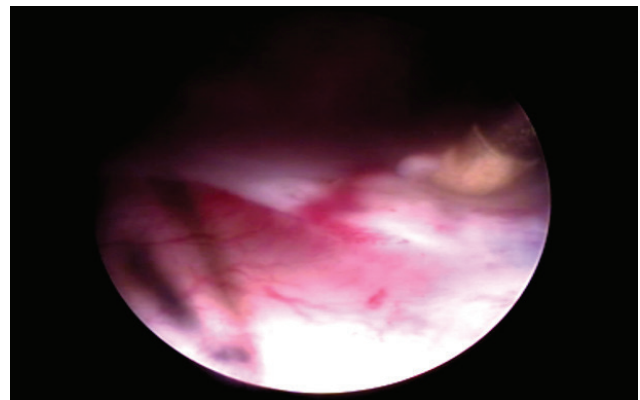


Figure 5: Arthroscopy view showing radio frequency ablation done in inner wall of capsule.

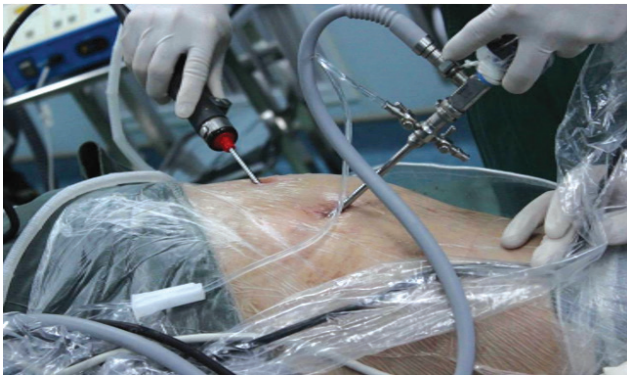

Figure 6: Arthroscopy procedure intra-operatively.

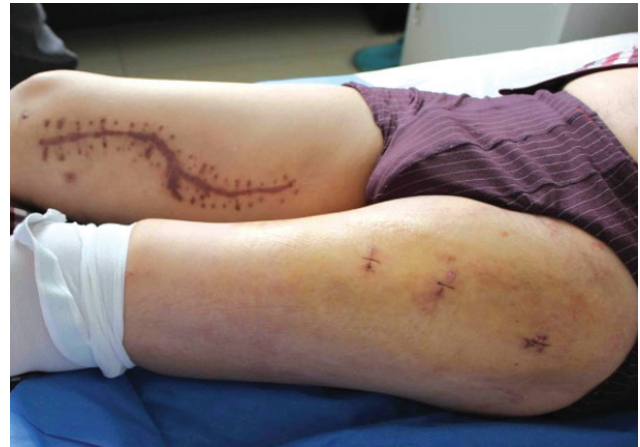

Figure 8: Comparison of open debridement versus arthroscopic technique of MLL. Post-operative scar mark after arthroscopy on left proximal thigh and scar mark on contra-lateral part after open debridement, which was done previously (2 weeks post-op).

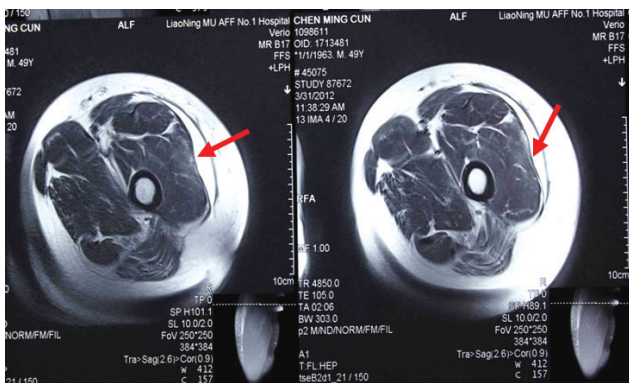


Figure 7: Axial MRI view showing a well defined crescentic fluid collection extending along the superficial fascia. Images show an encapsulated subcutaneous fluid collection, with a fluid-fluid level suggestive of Morell Lavallee Lesion.

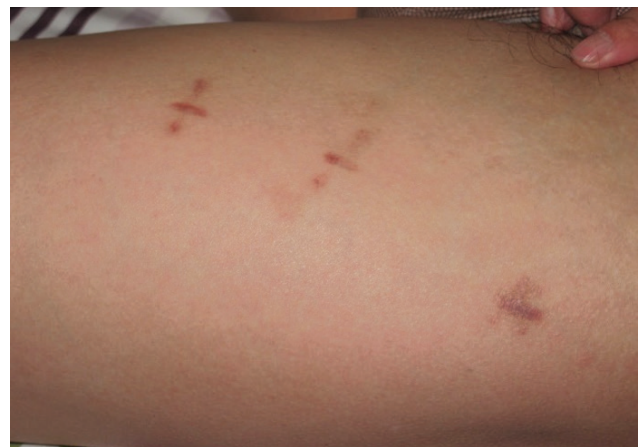

Figure 9: Scar mark and skin contour after Arthroscopy on left thigh (32 weeks post-op)

Case age/sex	Etiology	Site of lesion	Associated injuries	Treatment	Healing time	Complication
23/m	Soccer	knee	—	arthroscopy	3 wks	-
33/f	Crush under automobile	gluteal	Pelvic#	arthroscopy	4 wks	-
42/f	Crush under automobile	Lat. thigh	—	arthroscopy	4 wks	-
36/m	Crush under automobile	Lat. thigh	Pelvic#	arthroscopy	6 wks	hypersensitivity
35/m	In car traffic accident	Lat. thigh	—	arthroscopy	4 wks	-
39/m	Fall from bicycle	Lat. malleous	Tibia#	arthroscopy	4 wks	-
48/m	Blunt trauma by rigid rod	forearm	—	arthroscopy	4 wks	-

RESULT

The mean follow up period was 11 month (Range 6-24 month). Patient post-operative pain analysis subjectively evaluated by the visual analog pain scale (VAS) revealed non-significant post-operative pain, which rapidly decreased at nearly 0 after 2-3 post-operative days. All of the patients were recovered favorably. None of the patients were detected recurrence during the period of follow up. No any signs of palpable fluctuant were on examination finding and there was no fluid detected on ultrasonography. In all cases the lesions were compressed with elastic bandages and limb elevated above the level of heart by keeping some cotton pad below the limb. Post operatively compression bandage was continued with antibiotic for 24 hours and analgesic medication for 1 week. The patients were kept in a limited motion and were instructed not to bear weight for 2 weeks. At this time, patients were began a range of motion exercise and partial weight bearing, which were increased to full weight bearing as tolerated. Wound was completely healed. Full weight bearing given after 2 weeks. Culture and analysis of aspirated fluid were all negative. The only complication was hypersensitivity in one patient during post-operative period might be due to intravenous antibiotics which led to delayed in recovery but was recovered on subsequent addition of vitamin and protein diet.

Attempts were made to interview all patients in the initial series or to contact their families. The patients were asked to return for clinical and radiographic evaluation. Those who were unable to return were asked to have USG made locally and sent to us for evaluation. All of the patient who were treated with arthroscopy were evaluated either clinically or by telephone. Members of families of the patient who were out of contact were also interviewed to determine condition of patients. A complete functional assessment through either a personal interviewed or an interview with family member on telephone was possible for all patients.

Observation and Measurement were based on Ultrasonography of surgical sites that had been made early post operatively and at the latest follow

up evaluation. All observation and evaluation were agreed upon Professor Zhang dezhi and his residents. On 7th and 14th post operative day Ultrasonography was checked which shows almost resolved fluid or <1 to 2 ml. Patients were advised to follow up at 6 weeks interval. Patients who had came to department were evaluated with clinical assessment and Ultrasonography. 6 out of 7 patients who had came to department at first 6 weeks check up had completely resolved symptoms and signs. There was no discomfort or fluctuant swelling. Better compliance from the patient and ultrasonography result shows no fluid collection and remaining 1 patient was asked to ultrasonography locally available and result was no collection of fluid and patient compliance was far better than previous. Again at 6 month interval 5 out of 7 patients were available at department for check up. Ultrasonography and clinical assessment were done. The symptom and signs were completely resolved. Other were assessed on telephone as previously done.

DISCUSSION

History of trauma is helpful in directing the clinician to the appropriate diagnosis, the diagnosis of MLL may initially be missed. The age at which these lesions are noted has not been formally addressed. However, reports indicate that they most commonly occur in patients in the 3rd decade. Clinically Morell lavallee lesion usually are identified within several hours to days after the initial trauma, however up to one- third of the patient may not present until months or years after the initial trauma. Typically on physical examination, patients have a squishable soft fluctuant area with localized contour deformity or swelling with or without contusion or abrasions. Superficial cutaneous sensation over the area is commonly decreased because of shearing injuries of cutaneous nerves. Overlying skin necrosis may occur either due to direct trauma or in a delayed fashion because of the swelling and resultant ischemia to the overlying skin. Although these lesion are not unknown, they are rarely diagnosed which results in delay in their treatment [10]. Diagnosis of Morell lavallee lesion is made with combination of clinical examination, history and imaging studies. MRI is the diagnostic modality of choice. Ultrasonography shows the

amount of collection of fluid. Depending on the age of the hematoma, the lesion appears on sonography as anechoic relative to hyperechoic mass. It is located to anterior to the muscle layer and posterior to the hypodermis, a hypoechoic layer showing as thin bands of echoes that represent connective tissue. The mass may contain fat globules that appear as hyperechoic nodules along its wall 6. Mellado and Bencardino proposed an MRI classification system of Morell lavallee lesion based on lesion shape, signal and enhancement characteristic, and presence or absence of a capsule. Six types of lesion were described 10. Based on this classification we had 5 patients of type 3 and remaining 2 patients of type 2 and type 5.

Generally when traumatized patients were seen at emergency service, trauma team concentrate on severe injuries or hemodynamic stability at first, but possible associated injuries which are not so severe or not life threatening may be missed especially in patients who were unconscious or in bad general status. Contusions or abrasions of the skin over the different sites of the body when overdiagnosed or missed initially, may result as severe decubitus ulcer in the following days. In a polytraumatised patient whose fractures and hemodynamic status was stabilized, open or closed skin lesions on the whole body or over the possible surgical sites should be evaluated carefully. Overdiagnosed or despised closed degloving wounds may result with severe complications.

Different treatment modalities of MLL were reported in the literature, while some authors advocated compressive bandaging or open drainage [4, 11]. More invasive methods such as open debridement from a small incision followed by compressive bandaging were also advocated since the accumulated fluid was found to be infected initially by some authors [3, 12]. In order to prevent the widening of central skin necrosis over the lesion site the evacuation of the lesion was also advocated [13]. Hat et al in 1997 presented a series of 24 patients with closed degloving injuries that were debrided and left open to heal by secondary intention. They suggested that open debridement should be considered over techniques involving percutaneous drainage because open debridement

allows for infection 11. Alternatively, Tseng and Tornetta in 2006 described a percutaneous technique for the management of Morel-Lavallee lesions that involved small incisions at the proximal and distal aspects of the lesion. Following drainage of the hematoma, a plastic brush was used to percutaneously debride any devitalized or necrotic fatty tissue. The wound was irrigated, and a suction drain was placed. The drain was removed when output was <30 mL in a 24-hour period. Of note, all patients in their series were treated within 3 days of injury [14]. Luria et al in 2006 reported that talc sclerotherapy was effective in managing large post traumatic Morel-Lavallee lesions. This technique has the advantage of avoiding the need for an open procedure. In 4 patients who had failed simple drainage of their lesion, the authors evacuated the lesion with suction, and then injected talc into the wound. All patients treated in this manner showed an arrest in fluid accumulation. The authors cautioned that it was critical for the suction to obtain complete collapse of the walls of the cavity or risk potential failure as the remaining fluid may prevent scar formation and adhesion of the fascial layers. The authors note that the above method is contraindicated if infection is suspected [15]. Carlson et al reported that Morel-Lavallee lesions could be treated safely with debridement and meticulous dead-space closure in lesions that were both acute and chronic. Open lesions tended to be treated earlier. Closed lesions were left alone to spontaneously resolve and were only treated if the lesion became symptomatic. They had excellent results, with no infections or re-accumulation of fluid [16]. But this technique was limited to small lesion only. Small lesions may resolve completely with a small incision, drainage, and application of a compression bandage. However, persistent lesions may contain a pseudocapsule that makes them refractory to conservative treatment. Injection of sclerosing substances or internal drainage with surgical fascial fenestration was also reported in the management of closed degloving skin lesions^{4,17} although such skin lesions were reported to be infected by some authors [3,12]. Harma et al described the treatment of five MLLs located in the flank, buttock and gluteal regions with compressive elastic bandages or corsets¹⁸. One patient was aspirated because of a

wide fluctuating lesion; the culture was negative but the lesion re-occurred early. The capsule helps maintain the mass and explain why conservative therapy such as the application of a compression bandage is ineffective⁷. Treatment option of such lesion is not well established so our concern was treating and evaluating such lesion with arthroscopy. Arthroscopic assisted treatment of MLL has satisfactory result in our study. Arthroscopic assisted procedure is a good cosmetic technique over the previous techniques. Cosmetic dissatisfaction like rough scar mark, decreased skin mobility, contour deformity at site of lesion were minimized. Additionally it provide direct visualization than other blind techniques. Morel-Lavallee lesions could be treated safely with debridement and meticulous dead-space closure in lesions that were both acute and chronic. Arthroscopic shaver was used percutaneously to debride any devitalized or necrotic tissue. By radiofrequency ablation we removed only entire inner layer of capsule, but remaining outer part of capsule was left behind. By only removing inner surface of capsule integrity of skin contour could be well reserved. Arthroscopic assisted procedure helps to overcome the rough scar formation over skin as well as is less invasive with lesser soft tissue damage, shorter hospital stay and immobilization time.

From our study as mention above by maintaining the capsule intact with only removing entire inner layer of capsule, the patient follow up shows no any recurrence, no infection or any cosmetic dissatisfaction as mentioned above. This may suggest that the inner layer is vital part for recurrence, infection and persistence. To prove whether inner surface really responsible for recurrence and persistant of lesion research based study should be our future work.

Though there are many beliefs as to the desires of the patient's postoperative expectations, scientific research is lacking. Millions of patients are wasting financially for cosmetic dissatisfaction yearly so this current study evaluates patient's preoperative perception and postoperative expectation of cosmetic effectiveness following arthroscopic assisted MLL surgery.

CONCLUSION

Although there are some different techniques to treat the closed degloving soft tissue lesion as mentioned above, this study suggest that the inner layer of capsule is only the active part which contain certain secreting, inflammatory and toxic substance which were responsible for recurrence, infection and persistence of lesion.

Hence the arthroscopic assisted cosmetic surgery will be able to recover those severe injuries by reducing recovery time and may increase the rate of surgical success due to fewer traumas to the connective tissue with good visualization and also less scarring because of small incision. Moreover it will increase the fame of patient's satisfaction regarding post-operative rough scar mark, contour deformity of skin and diminished sensation over the skin.

ACKNOWLEDGEMENT

Our team like to thanks Yogesh Bajracharya, Rishiswor shrestha, Chitra adhikari, Anil ghmire for their assistance in data collection and support.

REFERENCE

1. Morel-Lavallee VAF. [Decollements traumatiques de la peau et des couches sous-jacentes]. Arch Gen Med. 1863;1:20-38, 172-200, 300-32[in French].
2. Gosain AK, Yan JG, Aydin MA, Das DK, Sanger JR. Plastic Reconstruction Surg2002 ;110:1655 –1661
3. Hak DJ, Olson SA, Matta JM. Diagnosis and management of closed internal degloving injuries associated with pelvic and acetabular fractures: the Morel-Lavallee lesion. J Trauma. 1997; 42: 1046-1051.
4. Ronceray J. Active drainage by partial aponeurotic resection of Morel-Lavallee effusions. [Article in French] Nouv Presse Med 1976;5:1305-6
5. Parra JA, Fernandez MA, Encinas B, Rico M. Morel-Lavallee effusions in the thigh. Skeletal Radiology. 1997; 26:239-241.

6. Tejwani SG, Cohen SB, Bradley JP. Management of Morel-Lavallee Lesion of the Knee Twenty-Seven Cases in the National Football League. *The American Journal of Sports Medicine*. 2007; 35:1162-1167.
7. Tsai JC, Dalinka MK, Fallon MD, Zlatkin MB, Kressel H. Fluid-fluid level: a nonspecific finding in tumors of bone and soft tissue. *Radiology* 1990 ;175:779 –782
8. Sterling A, Butterfield WC, Bonner R Jr, Quigley W, Marjani M. Post-traumatic cysts of soft tissue. *J Trauma* 1977 ;17:392 –39
9. Letournel E, Judet R. Fractures of the acetabulum, 2nd ed. Berlin, Germany: Springer-Verlag, 1993
10. Mallado JM, Bencardino JT. Morel-Lavallee Lesion: Review with Emphasis on MR Imaging. *Magn Reson Imaging Clin N Am*. 2005; 13: 775-782.
11. Mata JM. Surgical treatment of acetabulum fractures. In: Browner DB, Jupiter JB, Levine AM, Trafton PG, editors. *Skeletal trauma*. Philadelphia. W. B. Saunders; 1992. p. 899-992.
12. Hudson DA, Knottenbelt JD, Krige JE. Closed degloving injuries: results following conservative surgery. *Plast Reconstr Surg* 1992;89:853-5.
13. Mir y Mir L, Novell AM. Repair of necrotic cutaneous lesions, secondary to tangential traumatism over detachable zones. *Plast Reconstr Surg* 1950;6:264-74.
14. Tseng S, Tornetta P. Percutaneous management of Morel-Lavallée lesions. *J Bone Joint Surg Am*. 2006; 88(1):92-96.
15. Luria S, Applbaum Y, Weil Y, Liebergall M, Peyser A. Talc sclerodhesis of persistent Morel-Lavallée lesions (posttraumatic pseudocysts): case report of 4 patients. *J Orthop Trauma*. 2006; 20(6):435-438.
16. Carlson DA, Simmons J, Sando W, Weber T, Clements B. *J Orthop Trauma*. 2007; 21(2):140-144.
17. Kottmeier SA, Wilson SC, Born CT, Hanks GA, Iannacone WM, DeLong WG. Surgical management of soft tissue lesions associated with pelvic ring injury. *Clin Orthop* 1996; (329):46-53.
18. Harma A, Inan M, Ertem K. The Morel-Lavallee lesion: a conservative approach to closed degloving injuries. *Acta Orthop Traumatol Turc*. 2004;38:270-3.