

CASE REPORT III



OPEN ACCESS

Tumor Induced Osteomalacia: A Rare Case of Metabolic Bone Disease, often Underdiagnosed or Misdiagnosed

Wasti KP¹, Nepal R¹, Malla D², Karki BB³

¹ Senior resident, Diabetes and Endocrine unit, Department of Internal Medicine, National Academy of Health Sciences (NAMS), Kathmandu, Nepal, ² Assistant Professor, Diabetes and Endocrine unit, Department of Internal Medicine, National Academy of Health Sciences (NAMS), Kathmandu, Nepal. ³ Associate professor, Diabetes and Endocrine unit, Department of Internal Medicine, National Academy of Health Sciences (NAMS), Kathmandu, Nepal.

Abstract

Background: We present a case of a 42-year female with Tumor induced osteomalacia (TIO) who presented with multiple fragility fractures and decrease in height. The duration from symptom onset to the diagnosis and treatment was 5 years. It is imperative to keep TIO as differential in patients with chronic hypophosphatemia and osteomalacia.

Key words: Tumor induced osteomalacia, hypophosphatemia, fragility fracture, FGF-23

Introduction

A 42-year female, was apparently well till 5 years back, when she had pain over both knees. The pain was of variable intensity, aggravated by walking but not interfering with daily activities. After 3 months, she experienced pain over bilateral hip which was of similar intensity. The pain persisted and after 1 year she had to use over the counter analgesics. She also developed easy fatigability and generalized body ache. On evaluation, her HLAB27 was positive and she was managed in line of inflammatory arthritis with steroids and DMARDs. However, there was no improvement in symptoms.

3 years back, she had difficulty in climbing upstairs and developed limping over left leg. Xray pelvis showed healed fracture over left iliac bone. Then she required wheelchair for movement. Bone mineral density (BMD) showed severe osteoporosis over spine and hips, and she received Intravenous Zoledronic

acid. However, the symptoms persisted. Her further workup was delayed due to ongoing COVID pandemic at that time.

4 months back she presented to our OPD. She was still in wheelchair. Her husband had also noticed a decrease in height. History and examination didn't reveal any gross neurological abnormality. There was no bowing of knees, no bending of spine/knees, no dental abscess or malformations. There was no history of chronic diarrhea, night blindness or delayed wound healing. No history of similar illness in the family.

Correspondence Author

Dr. Kushal Prasad Wasti, kopnepal@gmail.com, Senior resident, Diabetes and Endocrine unit, Department of Internal Medicine, National Academy of Health Sciences (NAMS), Kathmandu, Nepal, Contact number: +9779841756825

CASE REPORT III



OPEN ACCESS

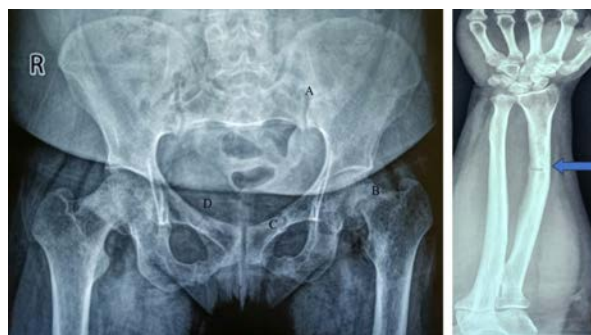Table 1: Investigations: Before and after treatment

Investigations	Before surgery			After surgery	
Corrected total serum calcium (8-11 mg/dl)	8.2	8.2	8.5	9.4	8.8
Serum Phosphorous (2.5-3.5 mg/dl)	1.5	1.6	1.7	3.7	3.6
25 hydroxy Vitamin D (30-100 ng/ml)	41	55		30.3	
iPTH (7.5-53.5 pg/ml)	167	121		67	
Alkaline Phosphatase (35-150 U)	212	250	320	104	98
1,25 dihydroxy Vitamin D (19.9-79.3 pg/ml)	18				
Serum Potassium (3.5-5 meq/L)	3.8				
Serum creatinine (0.3-1.4 mg/dl)	0.5			0.6	
FGF 23 (8.2-54.3 pg/ml)	155			15	15
TmP/gFR (2.5-3.4 mg/dl)	1.18			3	2.9

Her investigations showed hypophosphatemia with raised alkaline phosphatase and iPTH with low activated vitamin D. Her 24-hour urine phosphorous excretion 937 mg/24 hours. The tubular reabsorption of phosphate was 47% (Normal range = 80-90%). The ratio of tubular maximum reabsorption of phosphate (TmP) to GFR was 1.18 (2.5-3.4 mg/dl). Serum Fibroblast growth factor-23 (FGF-23) was elevated 155 pg/ml (normal – 8.2-54.3 pg/ml). Urine analysis showed urine pH of 5.7 and no evidence of albuminuria or glycosuria. Blood gas analysis showed a normal serum pH and serum bicarbonate. Skeletal survey showed cod fish vertebra, pseudo fractures over bilateral neck of fibula, left ulna, ischium and wedge collapse over T⁵.

In summary, her clinical, biochemical and radiological assessment revealed recurrent fragility fracture, chronic hypophosphatemia and elevated FGF23 levels. This suggested a provisional diagnosis of tumor induced

osteomalacia (TIO). The further evaluation required DOTATATE PET scan as well as systemic venous sampling. The case was referred to AIIMS, New Delhi for further management. Ga DOTA scan showed DOTA avid hypoechoic lesion 1.2 x 1.8 cm in right medial thigh with ill-defined margins. Systemic venous sampling also localized the lesion to right thigh. The lesion was then mapped with MRI and intraoperative USG and then excised with a 2 cm margin.



CASE REPORT III



OPEN ACCESS

Figure 1: Xray Pelvis AP view

- Fracture of left ilium extending medially to articular surface of Sacroiliac joint
- Minimally displaced fracture of neck of left femur at sub-capital region
- Healed fracture over bilateral superior pubic rami

Xray Right forearm AP view

Healed fracture involving the medial cortex of radius

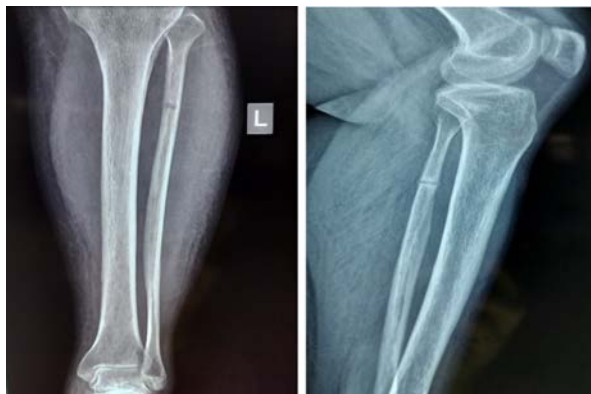

Figure 2:

- Focal lucent area in proximal shaft of left fibula involving the medial cortex- stress fracture (4 years prior to surgery)
- Progression of fracture (just before surgery)

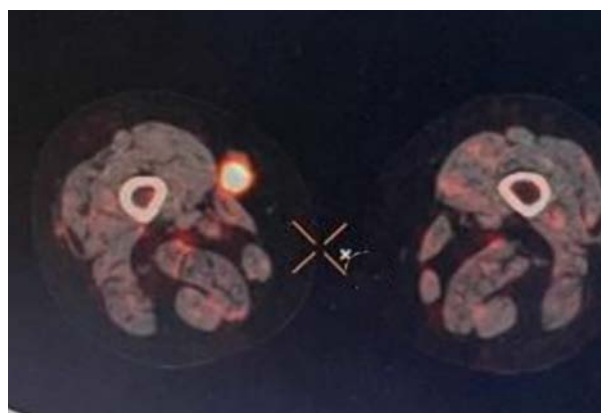


Figure 3: DOTATE scan showing DOTA avid hypochoic lesion 1.2 x 1.8 cm in right medial thigh with ill-defined margins.

Post-surgery the phosphate and FGF23 levels have normalized. Her pre surgery and post-surgery lab reports are compared in Table 1. The histopathology report is suggestive of phosphaturic mesenchymal tumor.

The patient has had symptomatic benefit in the form of decrease in generalized body ache and further improvement in clinical condition is expected.

Discussion

Tumor induced osteomalacia (TIO), also known as oncogenic osteomalacia is a rare paraneoplastic syndrome characterized by severe hypophosphatemia and osteomalacia, with renal phosphate wasting, occurring in association with mesenchymal bone or soft tissue tumors. These tumors are also called phosphaturic mesenchymal tumors (PMTs) ⁽¹⁾. It is a rare condition which is often underdiagnosed. The mean age of presentation is 40-45 years ⁽²⁾ and the condition is more prevalent among males- 58% ⁽³⁾. The median time gap between initial presentation and tumor related treatment is 3.5 years ⁽³⁾.

FGF23 is the most important regulator of phosphorous homeostasis in the body. The overexpression of FGF23 in these mesenchymal tumors or PMTs is regarded as the key factor in pathogenesis of TIO ⁽⁴⁾. FGF23 reduces the phosphorous reabsorption in kidney. It also leads to inhibition of 1 α hydroxylase in the kidney thus reducing conversion of 25 OH vitamin D to activated vitamin D thus inhibiting phosphate reabsorption from intestine as well ⁽⁵⁾. So, the overexpression of FGF23 leads to phosphorous wasting in both kidneys and GI tract leading to chronic hypophosphatemia and osteomalacia.

The clinical presentation is non-specific leading to a delay in diagnosis. Symptoms range from muscle fatigue, bone pain and multiple

CASE REPORT III



OPEN ACCESS

pathologic fractures. Most common site of involvement of mesenchymal tumors is thigh and femurs (22.7%) followed by craniofacial region (20%), ankle and foot (8.8%) followed by pelvis (8.2%)⁽⁶⁾.

The typical biochemical abnormalities include low serum phosphate, low to normal calcium, normal to slightly raised parathyroid hormone, low activated vitamin D, elevated alkaline phosphatase, low tubular reabsorption of phosphate and elevated FGF23⁽⁶⁾. For diagnosis, localization of tumor is essential by both functional and anatomical imaging. For functional imaging, Ga DOTATATE PET/CT is the modality of choice. Once lesions are identified on functional imaging, anatomical images with MRI are required for tumor mapping⁽²⁾ and in some cases systemic venous sampling of FGF23 may be required⁽⁷⁾.

The definitive treatment is surgical resection. With complete resection, the FGF23 and Phosphate levels normalizes within days and patient's symptoms will get alleviated. After complete resection, the BMD of hip and spine have shown improvement up to 30.9% and 49.3% respectively⁽²⁾. Periodic monitoring with serum phosphorous is essential as there are chances of recurrence. In cases of incomplete resection or when surgery isn't possible, radiofrequency ablation is an alternative⁽⁸⁾. Medical management includes activated Vitamin D and phosphorous supplementation.

Conclusion

TIO, is a rare, challenging but a potentially curable condition and has high morbidity if left undiagnosed. In any case of hypophosphatemia with osteomalacia or fractures or muscle pain, the treating physician should keep TIO as a differential. The patients with TIO are often misdiagnosed as osteoporosis or any

inflammatory pain syndromes and there is a significant delay in diagnosis. Physicians, endocrinologists, orthopedicians as well as rheumatologists should be aware of this condition.

Consent for publication

Consent for publication of the patient's data has been obtained from the patient herself.

Competing interests

The authors declare that they have no competing interests.

References

1. Folpe AL, Fanburg-Smith JC, Billings SD, Bisceglia M, Bertoni F, Cho JY, Et al. Most osteomalacia-associated mesenchymal tumors are a single histopathologic entity: an analysis of 32 cases and a comprehensive review of the literature. *Am J Surg Pathol.* 2004 Jan;28(1):1-30. doi: 10.1097/00000478-200401000-00001. PMID: 14707860.
2. Yin Z, Du J, Yu F, Xia W. Tumor-induced osteomalacia. *Osteoporosis and Sarcopenia.* 2018 Dec;4(4):119-127. doi: 10.1016/j.afos.2018.12.001. Epub 2018 Dec 12. PMID: 30775554
3. Bosman A, Palermo A, Vanderhulst J, De Beur SMJ, Fukumoto S, Minisola S, Et al. Tumor-Induced Osteomalacia: A Systematic Clinical Review of 895 Cases. *Calcif Tissue Int.* 2022 Oct;111(4):367-379. doi: 10.1007/s00223-022-01005-8. PMID: 35857061
4. Shimada T, Mizutani S, Muto T, Yoneya T, Hino R, Takeda S et al. Cloning and characterization of FGF23 as a causative factor of tumor-induced osteomalacia. *Proc Natl Acad Sci U S A.* 2001 May 22;98(11):6500-5. doi: 10.1073/pnas.101545198. PMID: 11344269

CASE REPORT III



OPEN ACCESS

5. Shimada T, Hasegawa H, Yamazaki Y, Muto T, Hino R, Takeuchi Y, et al. FGF-23 is a potent regulator of vitamin D metabolism and phosphate homeostasis. *J Bone Miner Res.* 2004 Mar;19(3):429-35. doi: 10.1359/JBMR.0301264. PMID: 15040831.
6. Dadoniene J, Miglinas M, Miltiniene D, Vajauskas D, Seinins D, Butenas P, Kacergius T. Tumour-induced osteomalacia: a literature review and a case report. *World J Surg Oncol.* 2016 Jan 8;14(1):4. doi: 10.1186/s12957-015-0763-7. PMID: 26744291.
7. Takeuchi Y, Suzuki H, Ogura S, Imai R, Yamazaki Y, Yamashita T, Et al. Venous sampling for fibroblast growth factor-23 confirms preoperative diagnosis of tumor-induced osteomalacia. *J Clin Endocrinol Metab.* 2004 Aug;89(8):3979-82. doi: 10.1210/jc.2004-0406. PMID: 15292336.
8. Jadhav S, Kasaliwal R, Shetty NS, Kulkarni S, Rathod K, Popat B, Et al. Radiofrequency ablation, an effective modality of treatment in tumor-induced osteomalacia: a case series of three patients. *J Clin Endocrinol Metab.* 2014 Sep;99(9):3049-54. doi: 10.1210/jc.2013-4515. PMID: 24960541.