

Morphological evaluation of styloid processes and their correlation with gender and age using Multidetector Computed tomography.

Prakash Sharma¹, Subita Lalchan², Subash KC², Merina Gyawali², Asheem Poudel³, Krishna Koirala⁴

¹Associate Professor & Head, ²Assistant Professor, ³Resident, Department of Radiology, ⁴Professor & Head, Department of ENT, Manimal Teaching Hospital, Pokhara, Nepal.

Received: November 10, 2021

Accepted: November 31, 2021

Published: December 30, 2021

Cite this paper:

Sharma P, Lalchan S, KC S, Gyawali M, Poudel A, Koirala K. Morphological evaluation of styloid processes and their correlation with gender and age using Multidetector Computed tomography. *Journal of Brain and Spine Foundation Nepal*. 2021;2(2):12-17.

Correspondence:

Prakash Sharma

Associate Professor & Head

Department of Radiology,

Manimal Teaching Hospital, Pokhara, Nepal.

Email: prakashshrm@yahoo.com

ORCID: <http://orcid.org/0000-0001-6917-7750>

ABSTRACT:

Introduction: The styloid process (SP) extends inferiorly from the temporal bone. Many neurovascular structures are closely related to its tip. Alteration in the length, angle and morphology of styloid process may lead to symptoms related to neurovascular compression. Hence it is necessary to know the normal variations before delineating the exact cause of symptoms related to head and neck region. This study was conducted to assess the variations in length, angle and morphology of styloid process and to correlate it with gender and age group. **Methods:** The Patients of trauma undergoing Paranasal Sinus Computed Tomography (CT) scan who were otherwise asymptomatic prior to the trauma were included in the study. Images were evaluated in dedicated work station. Length of bilateral styloid process were measured. Angulation of the SP was defined in the coronal and sagittal planes, respectively and morphology was identified as type I, II, III and IV. Findings were correlated with gender and age group. **Results:** A total of 192 patients were included in the study. The age of the patients ranged from 13 to 86 years. Mean length of right styloid process was 26.6 ± 8.6 mm and mean length of left styloid process was 27.0 ± 8.2 mm. There was no significant difference between the length of styloid process in males and females. Males had a significantly larger coronal angle as compared to females. There was a linear, weak, positive correlation between the length of styloid process and advancing age.

Conclusion: There was a wide variation in length, angle and morphology of styloid process.

Keywords: Angle, Length, Styloid process, Temporal bone.

Introduction:

The styloid process (SP) is a cylindrical bone that extends from temporal bone in front of the stylomastoid foramen. The SP tapers toward its tip, which is located lateral to the tonsillar fossa in the pharyngeal wall. The stylohyoid ligament, which extends to the lesser cornu of the hyoid bone, is connected to the tip of the SP. The stylomandibular ligament connects to the SP and extends

to the mandibular angle. Many key neurovascular structures are located near the tip of the SP, including the internal carotid artery, internal jugular vein, and cranial nerves X, XI, and XII. The presence of an elongated styloid process is linked to a variety of symptoms.^{1,2,3} A computed tomography (CT) scan can be used to determine its length and angulation. Clinicians, surgeons, and radiologists must have a thorough understanding of the anatomy of both normal and

pathological styloid. Hence, the purpose of this study was to investigate the morphological characteristics of the mineralized styloid process with the help of CT scan. It aims at measuring the length and angle of styloid process and to correlate the length and angle of styloid process with age and gender. This study adds important information about the diversity of the styloid process in the Nepalese population.

Methods:

This observational study was conducted in the Department of Radiology of Manipal teaching hospital, Pokhara from July 1st 2020 to June 30th 2021. Ethical approval was obtained from the institutional review board of Manipal Teaching Hospital. Patients of trauma undergoing Paranasal Sinus Computed Tomography (CT) scan who were otherwise asymptomatic prior to the trauma were included in the study.

Non-probability sampling technique was used for sample collection. CT scan of paranasal sinuses were done using standard protocol. Scans of paranasal sinuses were obtained with collimation: 128 x 0.6 mm scan time: 5.0 s scan length: 116 mm rotation time: 1.0 s tube settings: 120 kV, 380 eff. mAs in 128 Philipps CT scanner. Multi-detector 3D and Maximum intensity projection (MIP) images were reconstructed from each individual using multiplanar reconstruction. Styloid length from temporal bone junction to tip of the process was measured using CT image analysis workstation (Philips) in coronal and sagittal reconstruction plane. Ossification of stylohyoid ligament if present was recorded. The length of each SP was measured on both sides. If ossification of stylohyoid ligament was present, then the length of the ossified portion was added to styloid process length.

Angulation of the SP was defined in the coronal and sagittal planes, respectively. The angle between the long

axis of the SP and a line connecting the bases of both SP was defined as the transverse angle. Similarly, the angle between the long axis of the SP and the skull base line connecting the nasion and the opisthion was defined as the sagittal angle. The inner transverse angle was measured in coronal plane and anterior sagittal angle was measured in sagittal plane.

Patients were grouped according to sex and age and length and morphology of SP. We evaluated the SP for their average lengths, angles and morphology in different sex and age groups. Patients were divided into four groups according to the length and morphology of the SP. Morphology of styloid process was classified as type I, II, III or IV. ⁴

- Type I: normal (less than 30 mm)
- Type II: elongated (more than 30 mm)
- Type III: pseudoarticulated
- Type IV: segmented

IBM SPSS Statistics 20 (SPSS Inc., Chicago, IL, USA) was used to examine the data. All categorical data were expressed in percent and absolute number. The number and mean angle values of SP in each group were determined. T test was used to see the association between angle of styloid process and gender, length of styloid process and gender. ANOVA test was used to see the association between the angle of styloid process and the age group, length of styloid process and the age group. The Pearson correlation test was used to assess the relationship between length of styloid process and age. Statistical significance was defined at a P value of less than 0.05.

Results:

There was a total of 192 patients in our study. Age of the patients ranged from 13 to 86 years and mean age was 44.99±18.9 years. There were 85 (43.3%) females and

107 (55.7%) males. The mean length of the left styloid process was greater than that of the right styloid process. The angle of styloid in coronal plane was greater on the right side as compared to the left. But Angle of left styloid in sagittal plane was greater than of right side (Table 1).

Table 1: length and angles of styloid process on right and left side

	Mini mum	Maxi mum	Mean±SD
Right Styloid length (mm)	4.6	65.3	26.6±8.6
Left Styloid length (mm)	6.9	51.5	27.0±8.2
Angle of right styloid in coronal plane (degree)	55.1	85.9	68.4±5.5
Angle of left styloid in coronal plane(degree)	25.4	83.4	68.3±6.2
Angle of right styloid in Sagittal plane (degree)	54.0	97.2	82.9±5.9
Angle of left styloid in sagittal plane (degree)	70	291.9	85.3±15.7

There was no significant difference in the mean length of bilateral styloid processes within gender. Angle of bilateral styloid process in coronal plane was significantly higher in males as compared to females. There was no significant difference between the angle of bilateral styloid processes in sagittal plane (Table 2).

The right styloid process length was significantly longer in 40 to 60 years' age group whereas left styloid length was significantly higher in >60 years' age group. Bilateral styloid angle in coronal plane was greater in <40 years' age group but was not statistically significant. Right styloid angle in Sagittal plane was greater in >60 years' age group whereas left styloid angle in sagittal plane was greater in 40 to 60 years' age group which was also not statistically significant (Table 3). Most of the styloid process were type I in both male and female groups (Table 4).

Table 2: Comparison of length and angles of styloid across the gender

	Mean±SD		P value
	Male (N=107)	Female (N=85)	
Right Styloid length (mm)	27.0± 8.5	26.1±8.9	0.45
Left Styloid length (mm)	27.7±8.6	26.2±7.7	0.21
Angle of right styloid in coronal plane (degree)	69.3±5.3	67.3±5.7	0.01
Angle of left styloid in coronal plane(degree)	69.6±5.4	66.6±6.7	0.01
Angle of right styloid in sagittal plane (degree)	83.1±5.6	82.7±6.2	0.61
Angle of left styloid in sagittal plane (degree)	83.9±4.8	87.1±22.9	0.16

Table 3: comparison of length and angles of styloid in various age groups

	Age group in years			P value
	<40 (N=87)	40 to 60 (N=57)	>60 (N=48)	
Right Styloid length (mm); mean±SD	25.1±8.1	28.0±9.7	27.7±7.9	0.07
Left Styloid length (mm)	25.8±8.2	27.3±8.0	29.0±8.4	0.09
Right styloid angle in coronal plane (degree)	68.9±5.7	67.8±6.0	68.3±4.5	0.49
Left styloid angle in coronal plane (degree)	68.9±5.1	67.4±7.8	68.2±5.9	0.35
Right styloid angle in Sagittal plane (degree)	82.6±6.3	82.8±5.4	83.6±5.7	0.61
Left styloid angle in sagittal plane (degree)	83.5±5.0	88.3±27.8	85.3±4.4	0.20

There was a significant weak positive linear correlation between length of right styloid process and age (r=0.192, P=0.008). Similarly, there was also a significant weak

positive linear correlation between the length of left styloid process and age ($r=0.222$, $p=0.002$) (Fig 1 and 2).

Table 4: Morphological type of styloid process across gender

		Female	Male	Total
Right styloid	Type I	53	63	116
	Type II	13	22	35
	Type III	8	9	17
	Type IV	11	13	24
Left Styloid	Type I	47	63	110
	Type II	22	25	47
	Type III	9	5	14
	Type IV	7	12	19

Discussion:

The symptoms related to elongation of SP were first described by Eagle. Thereafter, the array of symptoms due to the structural changes in SP was named as Eagle’s syndrome. It has been reported that abnormal angulations are responsible for the symptoms.⁵ Some of these symptoms include pain in the throat, ear, face, dysphasia or foreign body sensation in the pharynx.^{6,7} These symptoms arise mainly due to compression on the neurovascular structures. In this study, we have attempted to show the normal variation in styloid process length, morphology and angulation. Its knowledge might be helpful in dealing patients with pain or other symptoms related to the head and neck region. Knowledge of the anatomical diversity of SP is necessary before regarding it as pathological. Awareness about anatomical diversity in the populations is necessary before relating the symptoms to pathological changes in the styloid process.

Eagle stated the normal length of styloid to be 2.5 cm.³ There are several studies done for the measurements of styloid process using different modalities which have shown that the average length of SP varies from 2.0 to 3.2 cm and the normal length of SP varies from 1.5 to 6.0 cm.⁸⁻¹⁵ In our study, the average length was 2.7 cm.

Several studies have reported that the length of SP in different age and sex groups was not significantly different.⁸⁻¹⁶ In our study we also did not observe a gender predilection in length of SP similar to their observation. Ramadoss T et al also did not find a gender predilection in their study.¹⁷ However, we observed that the right styloid process was significantly longer in 40 to 60 years’ age group whereas left styloid process was significantly higher in >60 years’ age group. Bruno G et al observed that in the different age group there was a progressive increase of the prevalence of the elongation with advancing age.¹⁸ Our study also shows a progressive increase in length of styloid process with advancing age.

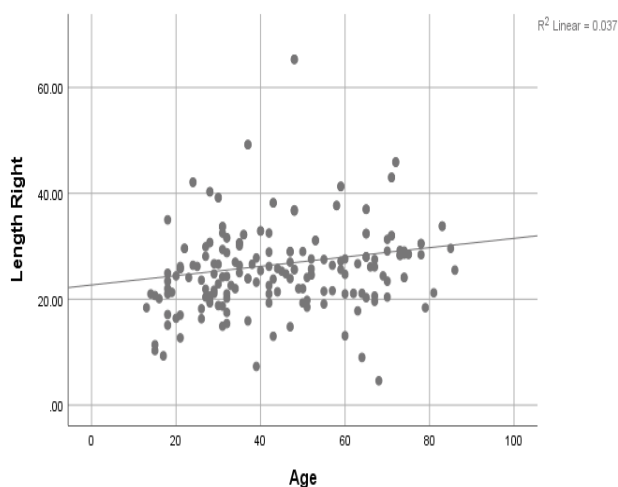


Fig 1: Association between age and length of right

styloid Onbas, O et al found that angulation of styloid process ranged between 55° and 90.5° (72.7 ± 6.6) in the transversal plane and between 76° and 110° (93.5 ± 6.9) in the sagittal plane.¹⁹ In our study the angulation varied between 55° to 89° on right side and 25° to 83° on left side in coronal plane. It varied between 70° to 291° on left side and 54° to 97° on right side in sagittal plane.

Regarding the calcification in SP, many studies have shown elongated being the most common type followed

by pseudo articulated and segmented type, similar to our study.²⁰⁻²⁵

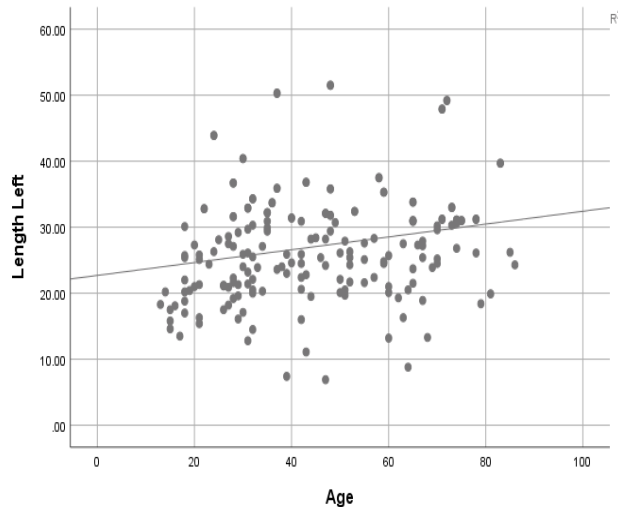


Figure 2: Association between age and length of left styloid process

Conclusions: There was no significant difference between the length of styloid process in males and females. Males had significantly larger coronal angle as compared to females. There was a linear, weak, positive correlation between the length of styloid process and advancing age.

Reference:

1. Kamal A, Nazir R, Usman M, Salam BU, Sana F. Eagle syndrome; radiological evaluation and management. *J Pak Med Assoc.* 2014;64:1315–7. Available from: <https://jpma.org.pk/PdfDownload/7082>.
2. Baig S, Patil N, Considine N. An unusual cause of recurrent throat pain – Calcified stylohyoid ligament. *J Coll Physicians Surg Pak.* 2012;22:258–60. Available from: <https://www.jcpkp.org/archives/2012/Apr2012/16.pdf>
3. Eagle WW. Elongated styloid process; further observations and a new syndrome. *Arch Otolaryngol.* 1948;47:630–40. <https://doi.org/10.1001/archotol.1948.00690030654006>

4. Knipe H, Deng F. Styloid process. Reference article, *Radiopaedia.org.* (accessed on 24 June 2020) Available from: <https://radiopaedia.org/articles/styloid-process>.
5. Yetiser S, Gerek M, Ozkaptan Y. Elongated styloid process: diagnostic problems related to symptomatology. *Cranio* 1997;15:236–41. <https://doi.org/10.1080/08869634.1997.11746017>
6. Balbuena L, Hayes D, Ramirez SG, et al. Eagle’s syndrome (elongated styloid process). *South Med J.* 1997;90(3):331–4. <https://doi.org/10.1097/00007611-199703000-00014>
7. Hossein R, Kambiz M, Mohammad D, Mina N. Complete recovery after an intraoral approach for Eagle’s syndrome. *J Craniofac Surg.* 2010;21(1):275–6. <https://doi.org/10.1097/SCS.0b013e3181c5a444>
8. Gozil R, Yener N, Calguner E, Arac M, Tunc E, Bahcecioglu M. Morphological characteristics of styloid process evaluated by computerized axial tomography. *Ann Anat* 2001;183:527–35. [https://doi.org/10.1016/S0940-9602\(01\)80060-1](https://doi.org/10.1016/S0940-9602(01)80060-1)
9. Bafageeh SA. Eagle syndrome: classic and carotid artery types. *J Otolaryngol* 2000;29:88–94. PMID: 10819106.
10. Keur JJ, Campbell JPS. The clinical significance of the elongated styloid process. *Oral Surg Oral Med Oral Pathol* 1986;67:399–404. [https://doi.org/10.1016/0030-4220\(86\)90426-3](https://doi.org/10.1016/0030-4220(86)90426-3)
11. Camarda AJ, Deschamps C. Stylohyoid chain ossification: a discussion of etiology. *Oral Surg Oral Med Oral Pathol* 1989;67:515–20. [https://doi.org/10.1016/0030-4220\(89\)90265-X](https://doi.org/10.1016/0030-4220(89)90265-X)
12. Klineberg I. The involvement of the styloid process in head and neck pain—a preliminary study. *J Rehabil* 2000;27:275–87. <https://doi.org/10.1046/j.1365-2842.2000.00515.x>
13. Monsour PA, Young WG. Variability of the styloid process and stylohyoid ligament in panoramic radiographs. *Oral Surg Oral Med Oral Pathol*

- 1986;61:522–6. [https://doi.org/10.1016/0030-4220\(86\)90399-3](https://doi.org/10.1016/0030-4220(86)90399-3)
14. Satyapal KS, Kalideen JM. Bilateral styloid chain ossification: case report. *Surg Radiol Anat* 2000;22:211–212. [https://doi.org/10.1016/0030-4220\(86\)90399-3](https://doi.org/10.1016/0030-4220(86)90399-3)
15. Fini G, Gasparini G, Filippini F, Becelli R, Marcotullio D. The long styloid process syndrome or Eagle’s syndrome. *J Craniomaxillofac Surg* 2000;28:123–27. <https://doi.org/10.1054/jcms.2000.0128>
16. Basekim CC, Mutlu H, Güngör A, Şilit E, Pekkaflı Z, Kutlay M, et al. Evaluation of styloid process by three-dimensional computed tomography. *Eur Radiol.* 2005;15:134-9. <https://doi.org/10.1007/s00330-004-2354-9>
17. Ramadoss T, Sha K. Assessment of the styloid process by cone beam computed tomography. *Int J RadiolRadiatTher.* 2017;2(5):123-7. <https://doi.org/10.15406/ijrrt.2017.02.00038>
18. Bruno G, De Stefani A, Balasso P, Mazzoleni S, Gracco A. Elongated styloid process: An epidemiological study on digital panoramic radiographs. *J Clin Exp Dent.* 2017 Dec ;9(12):e1446-e1452. <https://doi.org/10.4317/jced.54370>
19. Onbas O, Kantarci M, Karasen RM, Durur I, Basekim CC, Alper F. Angulation, Length, and Morphology of the Styloid Process of the Temporal Bone Analyzed by Multidetector Computed Tomography *Acta Radiologica Acta Radiologica* 2005;46(8):881-6. <https://doi.org/10.1080/02841850500335085>
20. Shaik MA, Naheeda, Kaleem SM, Wahab A, Hameed S. Prevalence of elongated styloid process in Saudi population of Aseer region. *Eur J Dent* 2013;7:449-54. <https://doi.org/10.4103/1305-7456.120687>
21. More CB, Asrani MK. Evaluation of the styloid process on digital panoramic radiographs. *Indian J Radiol Imaging* 2010;20:261-5. <https://doi.org/10.4103/0971-3026.73537>
22. Shah SP, Praveen NB, Syed V, Subhashini AR. Elongated styloid process: A retrospective panoramic radiographic study. *World J Dent* 2012;3:316-9. <https://doi.org/10.5005/jp-journals-10015-1181>
23. Kursoglu P, Unalan F, Erdem T. Radiological evaluation of the styloid process in young adults resident in Turkey's Yeditepe University faculty of dentistry. *Oral Surg Oral Med Oral Pathol Oral Radiol Endod* 2005;100:491-4. <https://doi.org/10.1016/j.tripleo.2005.05.061>
24. Ilgüy M, Ilgüy D, Güler N, Bayirli G. Incidence of the type and calcification patterns in patients with elongated styloid process. *J Int Med Res* 2005;33:96-102. <https://doi.org/10.1177/147323000503300110>
25. Kashyap RR, Kashyap RS, Naik V, Kini R. The styloid process: Morphological variations in South Indian population. *Indian J Otol* 2015;21:25-8. <https://doi.org/10.4103/0971-7749.152855>