

Case Report

Spinal Epidermoid Cyst in a Child- An Experience with a Rare Case

P Chaudhary, BP Shrestha, GK Khanal, R Maharjan, RPS Kalawar, B Pokharel, A Limbu,
P Baral, AB Shah, D Mishra, A Pandey, YB Gurung

Department of Orthopaedics, BP Koirala Institute of Health Sciences, Dharan

Abstract

Epidermoid cysts are rare benign neoplasm accounting for less than 1% of all intra-spinal tumors. Congenital epidermoid cysts are frequently found with syringomyelia, dermal sinus and spina bifida. Most common etiology for an acquired cyst is repeated lumbar puncture. Congenital epidermoid cysts, often associated with other spinal dysraphisms, are caused by the anomalous implantation of ectodermal cells during closure of the neural tube between the third and fifth week of embryonic life. This is a very rare case. With all these characteristics and literature review, we report this case for its rarity and unique characteristics in this part of world (Nepal). These patients commonly present late to the hospital.

Introduction

Intraspinal epidermoid cyst is a rare benign tumor.¹ The incidence of intraspinal epidermoid cysts in children is 3%.² Usually spinal epidermoid cysts are extramedullary. True intramedullary epidermoid cysts are uncommon. Of these, a very few have detailed radiographic evaluation. Intramedullary epidermoid cyst is common in the dorsal and lumbosacral region.^{3,4} We report the case of a 10-year-old male child with an intramedullary epidermoid cyst in the Lumbar region, which was evaluated by magnetic resonance imaging (MRI).

Case report

A 10 yr old male child who presented to BPKIHS with a 6 month history of LBP associated with moderate right buttock pain, posterior thigh pain, lateral leg pain, and numbness and tingling along the medial border of his foot. Pain gradually increased in intensity from last 1 month, causing difficulty in doing his daily activities. He had normal bladder and bowel functions. Neurologic examination demonstrated decreased sensation in the S1 distribution. Weakness was identified in the lower extremities in L5 region which was 4/5

(power). Ankle jerks were absent bilaterally. X-ray was done and it showed no abnormality. All routine investigations were done and all reports were within normal ranges. MRI was done and it showed evidence of an intradural tumor in the form of widening at L5-S1 levels, the lesion being hypointense on T1 weighted sequence and hyperintense on T2 sequence. The margins of the lesion were well defined but had a shaggy border. The conus-epiconus region was seen to be markedly expanded. Epidermoid cyst was in L5/S1 region.

Patient was posted for operation and was planned for excision of the cyst. The patient underwent B/L partial Laminectomy at L3/L4/L5. There was a distinct bulge of the dura. Following a midline dorsal durotomy, a pearly white and flaky lesion within the cord substance was seen. Near total excision of the lesion, including the capsule, was performed using micro neurosurgical techniques. Extreme care was taken to minimize the residual and prevent the contents of the cyst spreading into the subarachnoid space, which can lead to prolonged chemical meningitis.

He improved and at 1 month of follow-up, there was no ankle weakness with power of grade 5/5, no patchy sensory hypoesthesia and no urinary incontinence. Encouraging result was that radicular pain was nearly disappeared.

Address for correspondence

Dr. Pashupati Chaudhary
Department of Orthopaedics
BP Koirala Institute of Health Sciences, Dharan
Email: pashupati.chaudhary@bпкиhs.edu

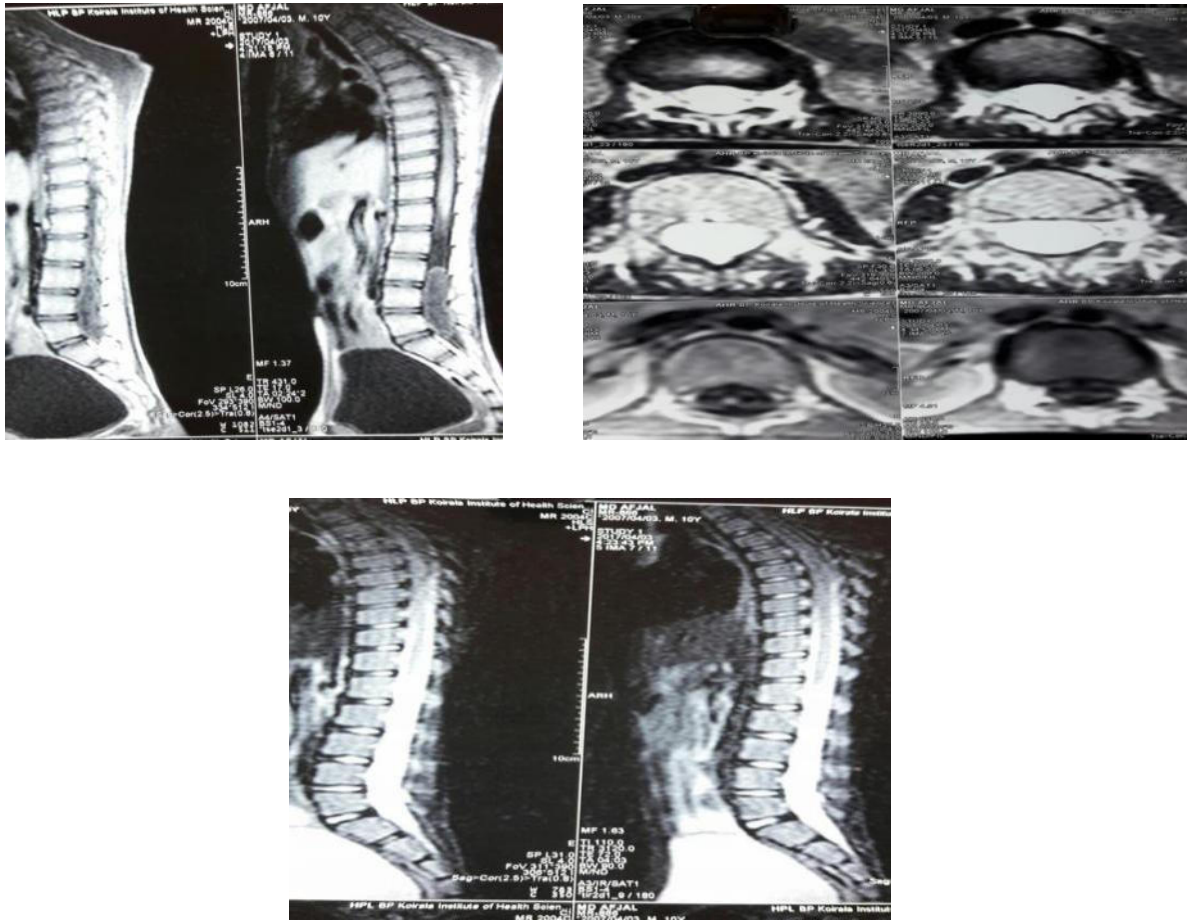

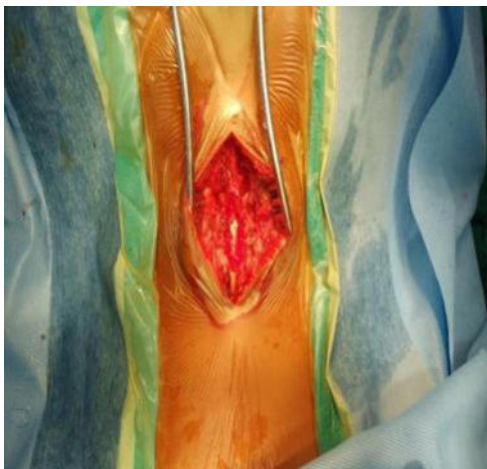
Figure 1: MRI L-S Spine sagittal section and axial image showing Epidermoid Cyst in L5-S1 region. (Intradural tumor at L5-S1 levels, the lesion being hypointense on T1 weighted sequence region was seen to be markedly expanded.)

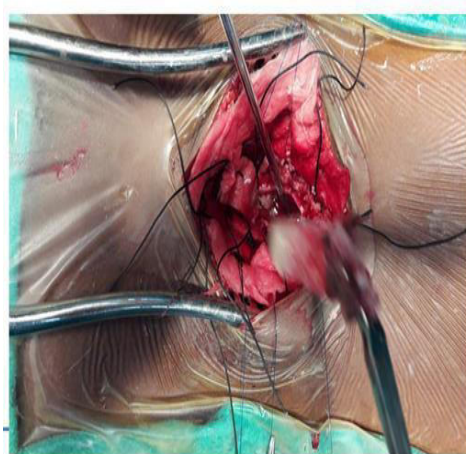

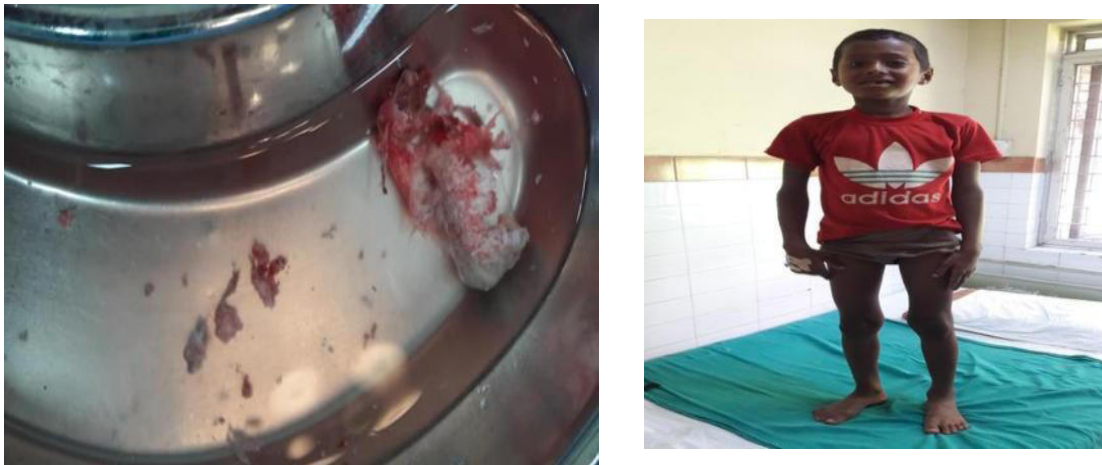


Figure 2: Post-operative image of patient (Partial laminectomy)

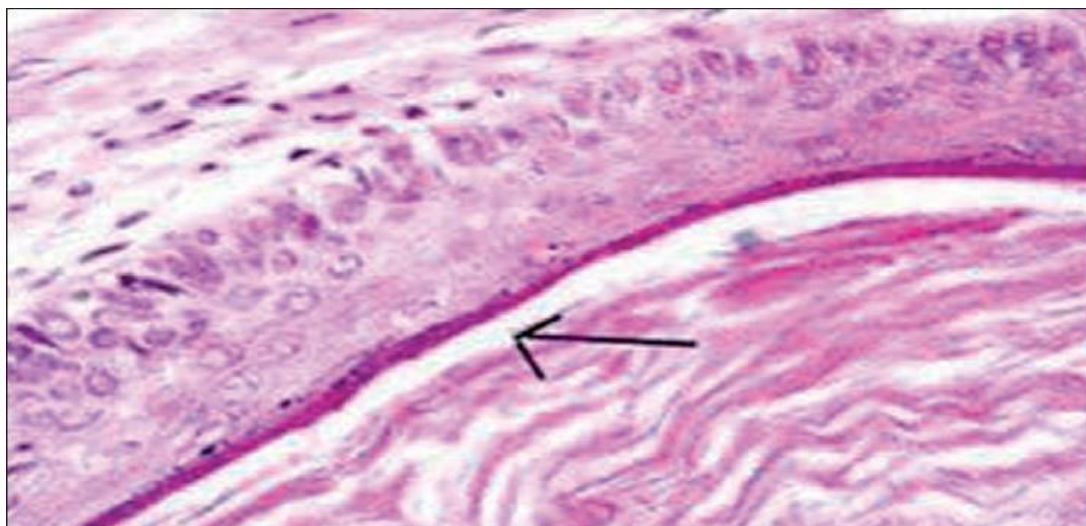


Figure 3: Histopathological findings of fibrous tissue lined in combination with compressed stratified squamous epithelium (arrow), conclusive of epidermoid cyst

Discussion

Epidermoid cysts are mainly congenital as they take origin from anomalous inclusion of the ectoderm tissue during the closure of the neural tube in early fetal life. These cysts may be associated with defective closure of the dural tube. Manifestations of other forms of dysraphism, such as syringomyelia, dorsal dermal sinus, spina bifida and hemivertebrae may be seen.^{5,6}

Epidermoid tumors rarely occur in the central nervous system, and are even rarer in the spinal

canal. Incidence of spinal epidermoid cyst is only 0.7%. Intramedullary localization is extremely rare. Roux *et al.* found 47 cases of spinal intramedullary epidermoid cysts.^{1,3-8} The commonest site of involvement is the thoracic spine usually at D4-6 and D11-12 regions and the next site of predilection is the lumbar region.^{3,4}

Preoperative diagnosis is sometimes difficult as other tumors that are intramedullary may lead to confusion. These include dermoid cyst, teratoma, ependymomas, astrocytomas and hemangioma. However, typical signal intensity,

absence of peritumoral edema, sharp boundaries and minimal peripheral enhancement with gadolinium confine the diagnosis to an epidermoid cyst.^{3,9}

Epidermoid cysts are lined by the stratified squamous epithelium supported by an outer layer of collagenous tissue. There is desquamation of keratin from the epithelial lining toward the interior of the cyst. This produces a soft white material. The diagnosis of dermoid cyst is ruled out by absence of skin adnexa (Figure 3).⁷

The treatment of epidermoid cyst is essentially surgical. Emptying of the cyst material and removal of the capsule is the treatment of choice.^{4,7,10} Literature shows radiotherapy as a modality in only one case.¹¹ In our case, the capsule was removed nearly completely without damaging the neural tissue. Attempts to completely dissect out the remnants of the capsule may result in avoidable sequelae of neural deficit. The benign nature of the epidermoid cysts offers an opportunity for a better neurological outcome if detected early.

Conclusion

It is a rare tumour. Complete excision without neural damage should be the goal of treatment.

References

1. Baba H, Wada M, Tanaka Y, Imura S, Tomita K. Intraspinial epidermoid after lumbar puncture. *Int Orthop*. 1994; 18:116-8.
2. Guidetti B, Gagliardi FM. Epidermoid and dermoid cyst: clinical evaluation and surgical results. *J Neurosurg*. 1977; 47: 12-8.
3. Gonzalvo A, Hall N, McMahon JH, Fabinyi GC. Intramedullary spinal epidermoid cyst of the upper thoracic region. *J Clin Neurosci*. 2009; 16: 142-4.
4. Ogden AT, Khandji AG, McCormick PC, Kaiser MG. Intramedullary inclusion cysts of the cervicothoracic junction. *J Neurosurg Spine*. 2007; 7: 236-42.
5. Manno NJ, Uihlein A, Kernohan JW. Intraspinial epidermoids. *J Neurosurg*. 1962; 19: 754-65.
6. Tekkök IH, Palaoglu S, Erbençi A, Onol B. Intramedullary epidermoid cyst of the cervical spinal cord associated with an extraspinal neuroenteric cyst: Case report. *Neurosurgery*. 1992; 31: 121-5.
7. Roux A, Mercier C, Larbrisseau A, Dube LJ, Dupuis C, Del Carpio R. Intramedullary epidermoid cyst of the spinal cord. *J Neurosurg*. 1992; 76: 528-33.
8. Shaywitz BA. Epidermoid spinal cord tumours and previous lumbar punctures. *J Pediatr*. 1972; 80: 638-40.
9. Gupta S, Gupta RK, Gujral RB, Mittal P, Kuriyal M, Krishnani N. Signal intensity patterns in intraspinal dermoids and epidermoids on MR imaging. *Clin Radiol*. 1993; 48: 405-13.
10. Lunardi P, Missori P, Gagliardi FM, Fortuna. Long-term results of the surgical treatment of spinal dermoid and epidermoid tumors. *Neurosurgery*. 1989; 25: 860-4.
11. Bretz A, Van den Berge D, Storme G. Intraspinial epidermoid cyst successfully treated with radiotherapy. *Neurosurgery*. 2003; 53: 1429-32.