

## **Laryngeal Amyloidosis- an Unusual Cause of Hoarseness: a Case Report**

S Mishra<sup>1</sup>, SP Shah<sup>1</sup>, ST Chhetri<sup>1</sup>, R Shah<sup>2</sup>, A Sanjel<sup>1</sup>

<sup>1</sup>Department of Otolaryngology, <sup>2</sup>Department of Pathology  
BP Koirala Institute of Health Sciences

### **Abstract**

Amyloidosis is a benign condition with abnormal deposition of extracellular protein in various parts of the body. Laryngeal amyloidosis is a rare clinical condition. Hoarseness of voice is one of the most common symptoms presenting to a clinician. The clinical appearance mimics the early laryngeal carcinoma. It remains a diagnostic challenge to the clinician. It is essential to differentiate laryngeal amyloidosis from malignancy as most of the findings mimic laryngeal carcinoma. We report a case of laryngeal amyloidosis that presented with hoarseness, to differentiate it from laryngeal malignancy for effective management.

**Keywords:** Amyloidosis, hoarseness, larynx

### **Introduction**

The term ‘Amyloidosis’ was first coined by Virchow, meaning starch like reaction of protein when treated with iodine and sulphuric acid.<sup>1</sup> Amyloidosis is a heterogenous group of disorders characterized by deposition of amyloid in various parts of the body. It may be either systemic or localized.<sup>2</sup> Amyloidosis commonly affects individuals between 50 and 70 years of age with a male: female ratio of 3:1. Amyloidosis of the larynx is a rare, usually benign process but the area is the most common site for isolated amyloid deposits to occur in the head and neck. The deposits account for 0.2 to 1.2% of benign tumors of the larynx.<sup>3</sup>

Laryngeal involvement can occur in all the three sub-sites of the Larynx. Other sites include the eyes, orbit, oral cavity, para-nasal cavities, nasopharynx and bronchus. Systemic amyloidosis in oral and para-nasal sinus are usually manifestation of plasma cell

dyscrasia.<sup>4</sup>

Patients with amyloidosis of the larynx typically present with hoarseness, although they may present with cough, globus, hemoptysis, stridor, or dyspnea, sometimes requiring emergency tracheostomy.<sup>5</sup> Its clinical appearance almost resembles an early laryngeal malignancy.

The definitive diagnosis is made with histopathological report of the biopsied specimen which confirms the presence of amyloid deposits. The staining is achieved by positive for Congo red with characteristic apple green bi-refringence in polarized light under electron microscopy.

We report a case of primary laryngeal amyloidosis.

### **Case report**

A 50 year old man, farmer by occupation who smoked, presented to otolaryngology OPD with complain of change in voice for 10 months and difficulty in breathing since 15 days. The symptom was gradually progressive. There were no complains of difficulty swallowing, blood mixed sputum or vomiting.

---

### **Address for correspondence**

Dr. Sudeep Mishra

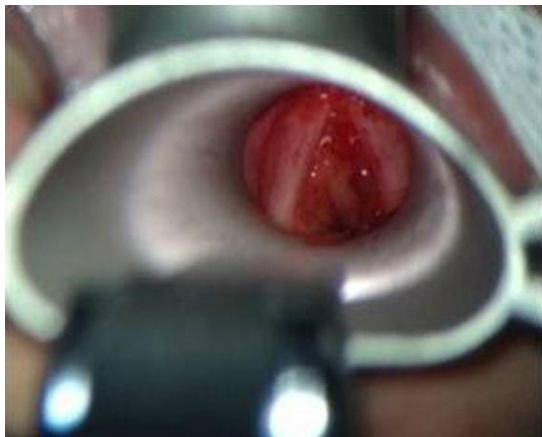Department of Otolaryngology

BP Koirala Institute of Health Sciences, Dharan

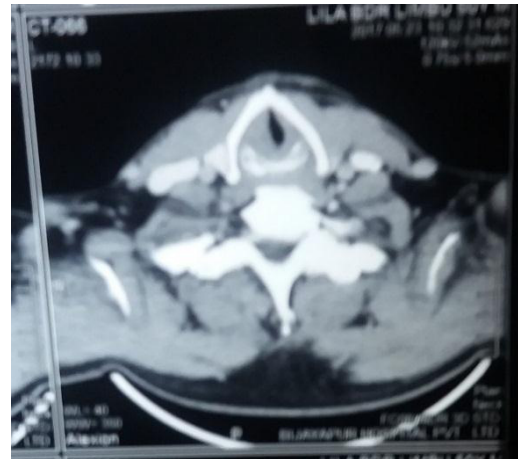Email: sudeep.mishra@bpkihs.edu

There was no history of laryngeal trauma or intubation. Physical examination revealed that pinkish mass in the left false cord, true cord and extending into the subglottis. Direct laryngoscopic examination and biopsy were performed with tracheostomy.

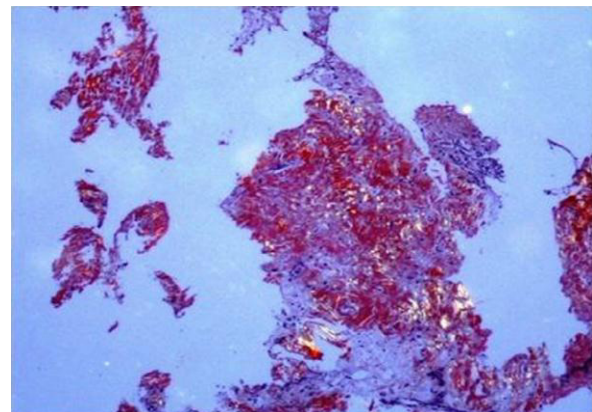
**Findings:**



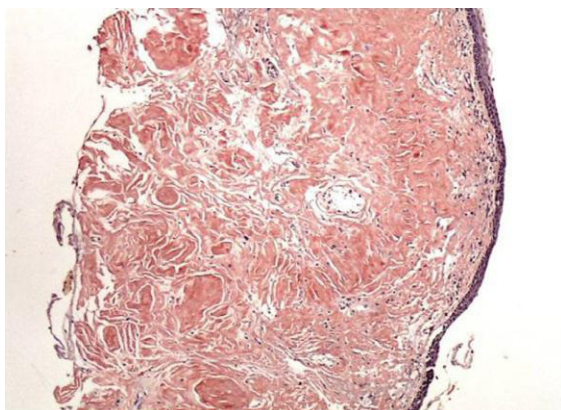
Laryngoscopic picture: proliferative growth involving Left true cord, extending into subglottis



CT showing heterogeneously enhancing lesion involving false cord and aryepiglottic fold left side



View under polarizing microscopy, amyloid deposits exhibit characteristic apple-green birefringence.



Congo red stain revealing intense amyloid deposits

**Discussion**

Amyloidosis is characterized by abnormal deposition of extracellular protein in the various tissues of the body. Amyloidosis may be localized and limited to a specific organ or generalized to various organs.<sup>5</sup>

There are two theories to explain the localized laryngeal amyloidosis. The first theory suggests the occurrence of plasma cell reaction to the inflammatory antigen. This theory is supported by the presence of mixed polyclonal plasma cells interspersed with the amyloid tissue pathologically. The next theory is

inability of the body to clear the light chains produced by the plasma cells located in the mucosal-associated lymphoid tissue.<sup>6</sup> During the work up for laryngeal amyloidosis, systemic involvement like multiple myeloma, rheumatic diseases, tuberculosis must be considered. Amyloidosis may be associated with familial syndromes and endocrinopathies. In such cases, medullary thyroid carcinoma should be considered.

Radiological investigations like CT or MRI are useful in knowing the extent of the disease. However, MRI is superior to CT as the amyloid deposits has intermediate T1 weighted and low T2 weighted intensity. The definite diagnosis is made by tissue biopsy followed by histological examination. The histopathological picture shows eosinophilic acellular stromal proliferation which stains with Congo red positive showing apple green birefringence in polarized light suggestive of amyloidosis. Investigations to rule out systemic amyloidosis are serum and urine electrophoresis, electrocardiogram, complete blood count, liver function test, renal function test and abdominal fat pad biopsy.<sup>8</sup> The main stay of treatment of laryngeal amyloidosis is surgical excision using CO<sub>2</sub> laser or micro laryngeal surgery. However, laser is superior to micro laryngeal surgery because of accuracy, better healing and preservation of function.<sup>7</sup> Other treatment measures like corticosteroids and radiotherapy had been tried without much success.

The disease has a very slow progressing course and, thus, may need repeated treatment and close follow up. Its resemblance to early laryngeal malignancy, work-up and

differential diagnosis for laryngeal amyloidosis has to be kept in mind.

### **Conclusion**

Change in voice, respiratory difficulty and laryngeal mass are common presentation of laryngeal amyloidosis. A systematic approach is mandatory for the effective management. Laryngeal amyloidosis should be kept as a differential diagnosis when we deal such patients closely resembling early laryngeal malignancy.

### **References**

1. Alaani A, Warfield AT, Pracy JP. Management of laryngeal amyloidosis. *J Laryngol Otol.* 2004; 118(4): 279-83.
2. Passerotti GH, Caniello M, Hachiya A, Santoro PP, Imamura R, Tsuji DH. Multiple sited amyloidosis in the upper aerodigestive tract: case report and literature review. *Rev Bras Otorrinolaringol.* 2008; 74(3): 462-6.
3. Thompson LD, Derringer GA, Wenig BM. Amyloidosis of the larynx: a clinicopathologic study of 11 cases. *Mod Pathol.* 2000; 13(5): 528-35.
4. Raymond AK, Sneige N, Batsakis JG. Pathology consultation. Amyloidosis in the upper aerodigestive tracts. *Ann Otol Rhinol Laryngol.* 1992; 101(9): 794-6.
5. Yiotakis, I, Georgolios A, Charalabopoulos A, Hatzipantelis P, Golias C, Charalabopoulos K and Manolopoulos L. Primary Localized

- Laryngeal Amyloidosis Presenting with Hoarseness and Dysphagia: A Case Report. *Journal of Medical Case Reports*, 2009; 3.10.4076/1752-1947-3-9049
6. Berg AM, Troxler RF, Grillone G, Kasznica J, Cohen AS, Skinner M. Localized amyloidosis of the larynx: evidence for light chain composition. *Ann Otol Rhinol Laryngol* 1993; 102(11): 884-9.
  7. Hegarty JL and Rao VM. Amyloidoma of the Nasopharynx: CT and MR Findings. *American Journal of Neuroradiology*, 1993; 14: 215-8.
  8. Ma L, Bandarchi B, Sasaki C, Levine S and Choi Y. Primary Localized Laryngeal Amyloidosis: Report of 3 Cases with Long-Term Follow-Up and Review of the Literature. *Archives of Pathology & Laboratory Medicine*, 2005; 129: 215-8.