

# DRUG-INDUCED GINGIVAL ENLARGEMENT- A PRACTICAL INSIGHT INTO ITS ETIOPATHOGENESIS AND MANAGEMENT

Simant Lamichhane<sup>1\*</sup>, Manoj Humagain<sup>2</sup>, Prakriti Rupakhety<sup>3</sup>, Arjun Hari Rijal<sup>4</sup>, Bhojraj Adhikari<sup>5</sup>

## Affiliation

1. Lecturer, Department of Periodontics, Kathmandu University School of Medical Sciences, Nepal
2. Professor, Department of Periodontics, Kathmandu University School of Medical Sciences, Nepal
3. Dental Surgeon, Chandragiri Dental Home and Implant Centre Pvt. Ltd., Nepal
4. Lecturer, Department of Periodontics, Kathmandu University School of Medical Sciences, Nepal
5. Lecturer, Department of Oral Pathology, Kathmandu University School of Medical Sciences, Nepal

## ARTICLE INFO

Received : 19 February, 2023

Accepted : 19 Jun2, 2023

Published : 10 November, 2023

© Authors retain copyright and grant the journal right of first publication with the work simultaneously licensed under Creative Commons Attribution License CC - BY 4.0 that allows others to share the work with an acknowledgment of the work's authorship and initial publication in this journal.



CR 55

DOI: <https://doi.org/10.3126/bjhs.v8i2.59862>

## Corresponding Author

Dr Simant Lamichhane

Lecturer

Department of Periodontics

Kathmandu University School of Medical Sciences, Nepal

Email: [drlamichhanesimant@gmail.com](mailto:drlamichhanesimant@gmail.com)

ORCID ID : <https://orcid.org/0000-0003-1997-9987>

## Citation

Drug-induced Gingival Enlargement- A Practical Insight Into Its Etiopathogenesis And Management. Simant Lamichhane, Manoj Humagain, Prakriti Rupakhety, Arjun Hari Rijal, Bhojraj Adhikari. BJHS 2023;8(2)21. 2066-2069.

## ABSTRACT

Drug-induced gingival enlargements are a familiar finding in a dental setup. They are seen especially in the patient on anti-convulsant, immunosuppressive, and calcium channel blockers therapy. Amlodipine used primarily as a monotherapy or in combination therapy in the management of a trailing disease like hypertension is associated with gingival enlargement constantly. This case report unveils the management of amlodipine-induced gingival enlargement and accentuates the important considerations regarding etiopathogenesis and practical ways of managing the case on a daily basis.

## KEYWORDS

*Amlodipine, Calcium channel blockers, Gingival overgrowth*

## INTRODUCTION

Hypertension affects around more than 25% of the total population on average residing in urban, rural, and suburban areas of Nepal.<sup>1</sup> The management protocol of hypertension is a tiresome work for many clinicians and researchers for many decades. They have remodelled the management protocol in recent times.<sup>2</sup> However, calcium channel blockers mainly amlodipine is considered a first-line agent for the management of hypertension owing to its patient compliant single dosing system due to their long half-life, minimum reflex neuroendocrine activation preventing of unwanted sudden drop of blood pressure, and with no rebound effect.<sup>3</sup> Data regarding the prevalence of amlodipine-induced gingival enlargement (AIGE) is highly skewed ranging from 2.5% to 31.4%.<sup>4,5</sup> Despite what the data suggest, we do commonly encounter AIGE in our clinical practice.

Here, we present a case report of AIGE along with a brief discussion on its etiopathogenesis and practical management that ensures a better result.

## CASE REPORT

A 47 years old female reported to the Department of Periodontology and Oral Implantology, Kathmandu university school of medical sciences with a chief complaint of gingival overgrowth hindering the oral hygiene maintenance and causing aesthetic concerns along with bleeding while toothbrushing. The extent of gingival enlargement was more evident and pronounce with relation to maxillary and mandibular front teeth region (Figure 1). The enlargements were graded as grade I with respect to 12-23 and grade II in 34-44 according to Bokenkamp and Bohnhorst grading system.<sup>6</sup> The management started with obtaining the medical history of the patient which revealed the patient is a known hypertensive and is on medication for 8 years. They were typically seen as bead-like painless enlargement more pronounced in the interdental region of anterior teeth. The overlying inflammation was present as suggested by bleeding on probing and there was presence of pseudo-pockets. Hence, the management protocol started with possibility of drug substitution after medical consultation (amlodipine substituted with losartan), non-surgical periodontal therapy and gingivectomy as a definitive resort.

On periodontal perspective, non-surgical periodontal therapy (scaling and root planning) was instituted twice at an interval of two weeks. Patient was taught regarding the proper oral hygiene procedures and informed consent was obtained for surgical periodontal therapy i.e., gingivectomy using scalpel. External bevel gingivectomy using the discontinuous incision technique was employed for the excision of the enlarged tissue. The positive architecture of gingiva was tried to maintain and few areas were managed with Gingivoplasty as well to create a thin and knife edge gingiva (Figure 2a and b). The surgical area was protected with non-eugenol periodontal dressing for two weeks (Figure 3).

The excised tissues were sent for histopathological examination. On histopathology, hyperkeratosis with elongated rete ridges were evident in epithelium. Underlying connective tissue revealed extensive fibrosis with numerous fibroblasts and plasma cells predominated inflammatory component all suggestive of drug induced gingival enlargement (Figure 4a and b).

During the follow ups at one month's post-operatively and six months post-operatively, results were fairly maintained with a nice positive gingival architecture, devoid of bleeding on probing, normal sulcus depth of around 2-3mm, all suggestive of normal gingival health (Figure 5 and 6). Scaling was performed on every follow up as a part of periodontal maintenance.

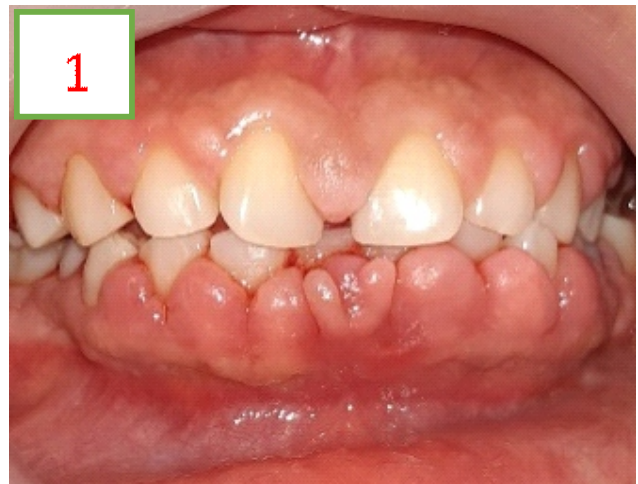

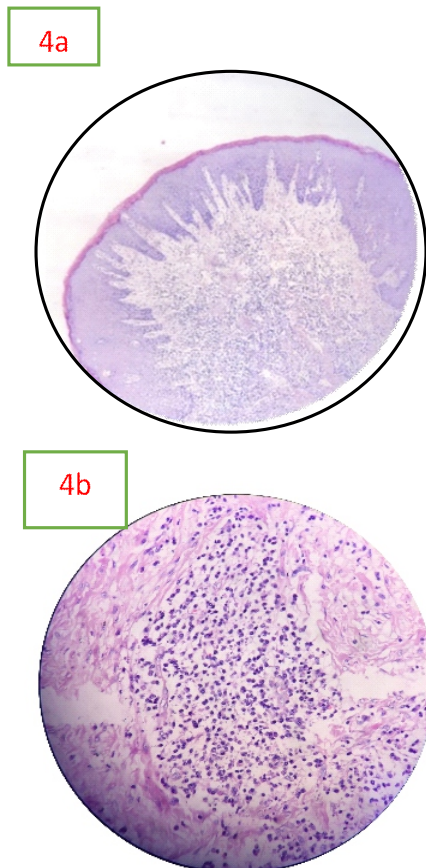
Figure 1: Initial clinical presentation of AIGE

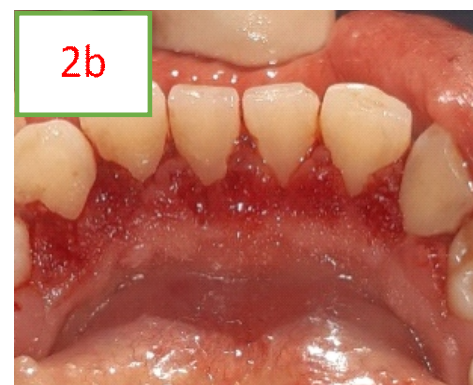
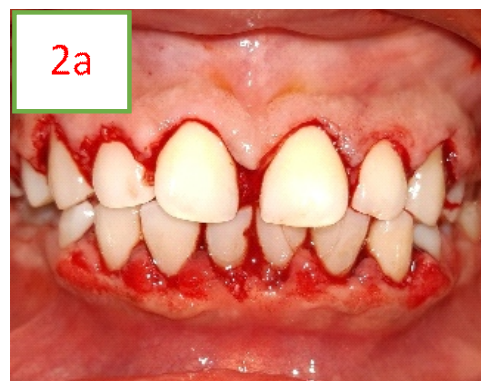
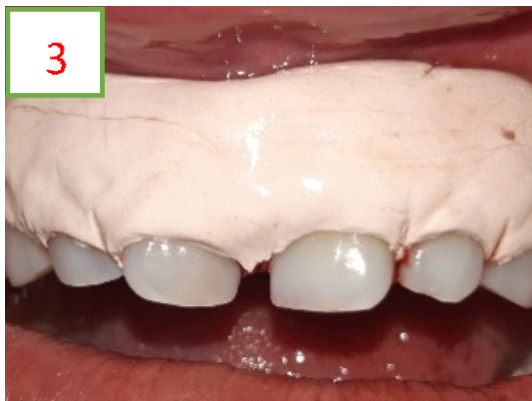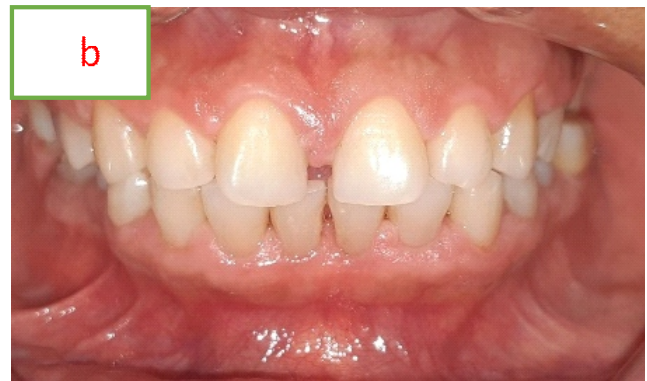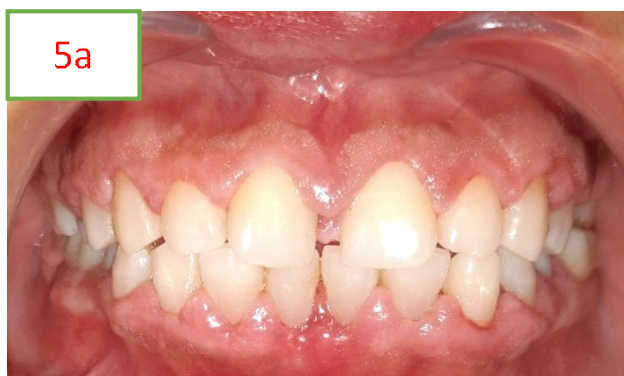Figure 2a and b: Gingivectomy and Gingivoplasty procedure



**Figure 3:** Application of periodontal dressing



**Figure 4:** Histological presentation  
 a) Hyperplastic parakeratinized epithelium with elongated rete ridges (10X)  
 b) Connective tissue showing dense collagen fibres and plasma cells infiltration (40X)



**Figure 5:** Post-op pictures showing stable results at a: 1month, b: 6 months

**DISCUSSION**

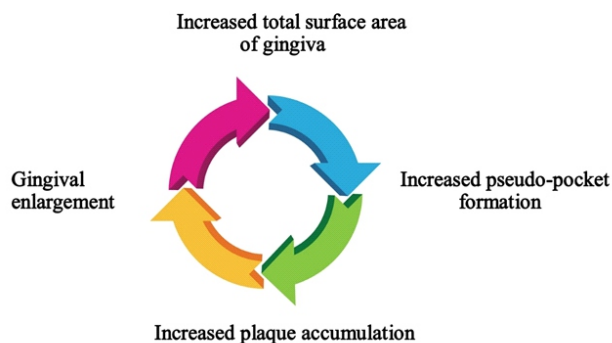
Drug induced gingival enlargement are commonly encountered with three main group of drugs namely calcium channel blockers, anti-convulsant and immunosuppressant. But in daily practice commonly we come across the enlargement associated with calcium channel blockers especially amlodipine as being used frequently for the management of hypertension, angina, peripheral vascular disease, migraine, etc.<sup>3</sup> Among the calcium channel blocker, amlodipine is the third generation dihydropyridine with increased duration of action and fewer known side effects.<sup>7</sup>

ALGE was first reported in periodontal literature in a case report from three patients in 1994 by Seymour et al.<sup>8</sup> Despite its finding before almost a three decades earlier, the exact establishment of its etiopathogenesis is fuzzy. Multiple mechanisms are described to validate the cause-effect relationship like reduction of calcium influx, genetic predisposition, activation of inflammatory cascades, concomitant role of plaque, etc.<sup>9</sup>

Amlodipine inhibit the Ca<sup>2+</sup> ion influx into the cell thereby reducing the folic acid uptake by cells necessary for formation of active collagenases.<sup>10</sup> The collagenases are responsible for breakdown of collagen fibres of the periodontium. The reports also suggest the increased level of tissue inhibitor of matrix metalloproteinases (TIMPs) favouring the increased fibres in the gingival tissues.

Plaque accumulation is usually pronounced in ALGE but who comes earlier is the biggest riddle, yet to be solved. Generally, plaque index and gingival index scores are seen higher in ALGE cases which signify the crucial role of plaque in ALGE.<sup>11</sup> Hence, drug induced gingival enlargements (DIGE) are kept under subheading of plaque induced gingival gingivitis and modifying factors in the recent 2017 World Workshop classification of periodontal and peri-implant diseases.<sup>12</sup> Furthermore, plaque accumulation will increase the inflammatory mediators which are proposed to be one of the mechanisms for DIGE. Transforming growth factor-Connective tissue growth factor (TGFβ1-CTGF) axis is one of the major pathways suggested among the inflammation induced DIGE which directly regulates fibrosis, gingival fibroblast lysyl oxidase, and collagen generation.<sup>13</sup> Hence, plaque control seems to be the mainstay to control DIGE.

Regarding the management protocol, it is always initiated with non-surgical therapy to potentially remove the inflammatory components. However, the true fibrotic component is resolved either with drug substitution or excision of the gingival tissues in case of pseudo-pockets. The suggested time to wait after drug substitution is at least 6 months which is practically infeasible. The main reason behind this is the heavily increased surface area of gingiva available for further plaque accumulation. This creates a vicious cycle which will eventually lead to gingival enlargement to a greater extent (Figure 6).



**Figure 6:** Vicious cycle of gingival enlargement possible if early interventions are not carried out

## CONCLUSION

AIGE is a regular finding in clinical practice. The data regarding the etiopathogenesis is sparse and inconclusive. Irrespective of other etiopathogenesis, plaque accumulation seems to be the major factor in determining the adverse effects. Management protocol shouldn't be too conservative. Waiting period after drug substitution is not practically possible as waiting too long might favour the plaque accumulation and further deteriorate the condition.

## PATIENT CONSENT

Written informed consent was obtained from patient before the surgical procedure.

## CONFLICTS OF INTEREST

None

## REFERENCES

- Huang Y, Guo P, Karmacharya BM, Seeruttun SR, Xu DR, Hao Y. Prevalence of hypertension and prehypertension in Nepal: a systematic review and meta-analysis. *Global health research and policy*. 2019 Dec;4(1):1-0. DOI: 10.1186/s41256-019-0102-6
- Unger T, Borghi C, Charchar F, Khan NA, Poulter NR, Prabhakaran D, Ramirez A, Schlaich M, Stergiou GS, Tomaszewski M, Wainford RD. 2020 International Society of Hypertension global hypertension practice guidelines. *Hypertension*. 2020 Jun;75(6):1334-57. DOI: 10.1161/HYPERTENSIONAHA.120.15026
- Fares H, DiNicolantonio JJ, O'Keefe JH, Lavie CJ. Amlodipine in hypertension: a first-line agent with efficacy for improving blood pressure and patient outcomes. *Open heart*. 2016 Sep 1;3(2):e000473. DOI: 10.1136/openhrt-2016-000473
- Sharma A, Joshi R, Rana SR, Shrestha DB, Joshi PR, Khadka S. Amlodipine induced gingival overgrowth in patients at a tertiary level hospital of Nepal. *J Nep Soc Perio Oral Implantol*. 2018 Jun 20;2(1):2-5.
- Gopal V, Quo BC, Chainani-Wu N. Amlodipine-Induced Gingival Overgrowth with Unusual Presentation as a Gingival Mass and Rapid Regression After Dose Reduction. *Clin Adv Periodontics*. 2017 Feb;7(1):25-9. DOI: 10.1902/cap.2016.160013
- Bökenkamp A, Bohnhorst B, Beier C, Albers N, Offner G, Brodehl J. Nifedipine aggravates cyclosporine A-induced gingival hyperplasia. *Pediatric nephrology*. 1994 Apr;8:181-5. DOI: 10.1007/BF00865474
- Desnica J, Vujovic S, Stevanovic M, Vasovic M, Stanisic D, Ognjanovic I, Rosic G, Jankovic S, Jovicic N, Kostic M. Gingival Enlargement Caused by Calcium Channel Blockers. *Experimental and Applied Biomedical Research (EABR)*. DOI: 10.2478/sjocr-2021-0061
- Seymour RA, Ellis JS, Thomason JM, Monkman S, Idle JR. Amlodipine-induced gingival overgrowth. *J Clin Periodontol*. 1994 Apr;21(4):281-3. DOI: 10.1111/j.1600-051x.1994.tb00318.x
- Bharti V, Bansal C. Drug-induced gingival overgrowth: The nemesis of gingiva unravelled. *J Indian Soc Periodontol*. 2013 Mar;17(2):182. DOI: 10.4103/0972-124X.113066
- Samudrala P, Chava VK, Chandana TS, Suresh R. Drug-induced gingival overgrowth: A critical insight into case reports from over two decades. *J Indian Soc Periodontol*. 2016 Sep;20(5):496. DOI: 10.4103/jisp.jisp\_265\_15
- Tejnani A, Mani A, Sodhi NK, Mehta A, Gourkhede S, Thorat V, Marawar P. Incidence of amlodipine-induced gingival overgrowth in the rural population of Loni. *J Indian Soc Periodontol*. 2014 Mar;18(2):226. DOI: 10.4103/0972-124X.131332
- Murakami S, Mealey BL, Mariotti A, Chapple IL. Dental plaque-induced gingival conditions. *J Clin Periodontol*. 2018 Jun;45:S17-27. DOI: 10.1002/JPER.17-0095
- Kantarci A, Carranza FA, Hogan E. Gingival enlargement. In: Newman MG, Takei HH, Klokkevold PR, Carranza FA, editors. *Newman and Carranza's Clinical Periodontology 13th ed*. St. Louis, MO: Saunders Elsevier; 2019. P261