

# MICROPTHALMOS WITH ORBITAL CYST: CASE SERIES WITH A REVIEW OF LITERATURE

Aashish Raj Pant<sup>1\*</sup>, Rinkal Suwal<sup>2</sup>, Purushottam Joshi<sup>3</sup>, Santosh Chaudhary<sup>4</sup>, Sujan Sharma<sup>5</sup>, Nisha Shrestha<sup>6</sup>

## Affiliation

1. Consultant, Department of Oculofacial Plastic Surgery, Mechi Eye Hospital, Nepal
2. BP Eye Foundation, Hospital for Children, Eye, ENT, and Rehabilitation Services (CHEERS) Optometrist, Department of Optometry
3. Ophthalmologist, Medical Director, Mechi Eye Hospital, Mechi Eye Hospital, Nepal
4. Assistant Professor, Department of Ophthalmology, B.P. Koirala Institute of Health Sciences, Nepal
5. Consultant Pathologist, National Reference Laboratory (NRL), Nepal
6. Lecturer, Department of Ophthalmology, KIST Medical College, Nepal

## ARTICLE INFO

Received : 25 July, 2021

Accepted : 02 January, 2022

Published : 21 February, 2022

© Authors retain copyright and grant the journal right of first publication with the work simultaneously licensed under Creative Commons Attribution License CC - BY 4.0 that allows others to share the work with an acknowledgment of the work's authorship and initial publication in this journal.



CR 45

DOI: <https://doi.org/10.3126/bjhs.v6i3.43247>

### \* Corresponding Author

Dr. Aashish Raj Pant  
Consultant

Department of Oculofacial Plastic Surgery  
Mechi Eye Hospital, Nepal

Email: [aashish.raj.pant@gmail.com](mailto:aashish.raj.pant@gmail.com)

ORCID ID: <https://orcid.org/0000-0003-0113-8338>

## Citation

Micropthalmos with orbital cyst: Case series with a review of literature. Aashish Raj Pant, Rinkal Suwal, Purushottam Joshi, Santosh Chaudhary, Sujan Sharma, Nisha Shrestha. BJHS 2021;6(3)16. 1665-1668.

## ABSTRACT

Micropthalmos with orbital cyst is a rare congenital abnormality of fetal fissure closure leading to a small eyeball associated with an orbital cyst. In this case series, we describe six such cases and discuss the clinical features, differential diagnosis, diagnostic modalities, and management in accordance with the existing literature. Out of the six cases, four were male and two were females. All the cases presented with a swelling in the lower eyelid of the involved eye, which was the right eye in all the male patients and the left eye in all the female cases. Other eye showed uveal coloboma in 50% of the cases. Micropthalmos with orbital cyst was diagnosed based on the clinical features and radiological findings (ultrasonography B-scan and/or Computed Tomography scan). Two patients from our case series underwent surgery (cyst excision with enucleation of microphthalmic eye with orbital implant and conformer) and, histopathology confirmed the diagnosis of micropthalmos with orbital cyst. Micropthalmos with orbital cyst presents as a swelling of the lower eyelid since birth in which a careful examination often reveals a microphthalmic eye. Two such cases in our case series were managed with orbital cyst excision and enucleation of microphthalmic eye followed by orbital implant and conformer, leading to good cosmetic results.

## KEYWORDS

Coloboma, cyst, micropthalmos



**INTRODUCTION**

Congenital microphthalmos is a rare entity with a reported prevalence of 1.4-3.5 per 10000 live births.<sup>1</sup> However, there is no accepted prevalence rate due to the rarity of this disease.<sup>2</sup> Microphthalmos associated with an orbital cyst is even rarer with only few case reports and case series been reported in the literature since it was first described by Arltin 1858.<sup>3</sup>

This serious congenital developmental anomaly of the eyeball is caused by faulty closure of the inferomedially placed embryonic fissure, which is generally identified in the early stage of the neonatal period.<sup>4-12</sup> Orbital cysts related to microphthalmia have been categorized by Duke-Elder into three types: small, not apparent cyst with a comparatively normal eye; apparent cyst related to a grossly malformed eye; large cyst pushing the globe backward thus resulting in a clinically unnoticeable globe.<sup>5</sup> In the majority of the cases of microphthalmia, the presence or absence of cyst is sporadic, and it is difficult to determine whether it is inherited or not.<sup>13</sup> Etiology can be both genetic or non-genetic. In this study, we have described six infrequent cases of microphthalmos with orbital cyst presenting at various age groups, in which two of them had surgical excision of the cyst along with the microphthalmic eye.

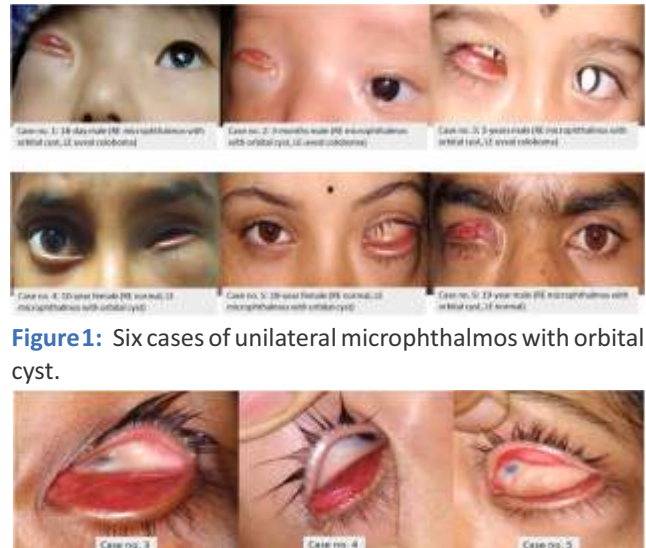**CASE REPORT**

We describe six cases of microphthalmos with orbital cyst presenting to us with ages ranging from 18 days to 19 years (Table 1). Four of them were male and two were female. Four cases were from the neighboring areas of India and only two were from Nepal. All the cases presented with a swelling of the lower eyelid of the involved eye since birth which was progressively enlarging with age. Interestingly, microphthalmos with cyst was present in the right eye of all four males whereas it was present in the left eye of both the females in our case series. There were no cases of bilateral microphthalmos with orbital cyst in our series.

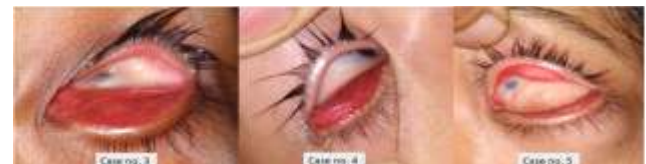**Table 1:** Summary of the cases of microphthalmos with orbital cyst.

Case	Age	Sex	Address	Diagnosis	Association	Management
1.	18 days	M	Nepal	RE Microphthalmos with orbital cyst	LE Uveal coloboma	Observation
2.	3 months	M	Nepal	RE Microphthalmos with orbital cyst	LE uveal coloboma	Observation
3.	3 years	M	India	RE Microphthalmos with orbital cyst	LE uveal coloboma	Surgery advised
4.	10 years	F	India	LE Microphthalmos with orbital cyst	RE normal	Surgery advised
5.	18 years	F	India	LE Microphthalmos with orbital cyst	RE normal	LE cyst excision + enucleation of eyeball with implant
6.	19 years	M	India	RE Microphthalmos with orbital cyst	LE normal	RE cyst excision + enucleation of eyeball with implant

M: Male; F: Female; RE: Right eye; LE: Left eye



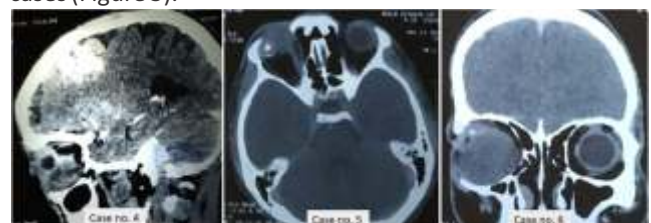**Figure 1:** Six cases of unilateral microphthalmos with orbital cyst.



**Figure 2:** Figure 2 Retraction of eyelid revealed the microphthalmic eye in cases 3,4,5. Microphthalmic eye could not be visualized on case 6 despite retraction.

In our case series, we found that uveal coloboma in the other eye was present in only 50% of the cases. The three cases had complete uveal coloboma (Iris and retino choroidal coloboma). The other three cases had normal eyeball with visual acuity of 6/6 and no evidence of uveal coloboma on the slit-lamp anterior segment examination and binocular indirect ophthalmoscopic fundus examination.

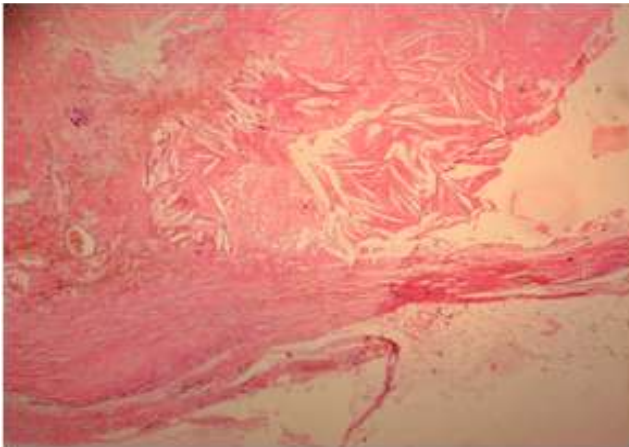
B-scan ultrasonography was done for all cases, which demonstrated a large cyst in the inferior and anterior part of the orbital cavity of the involved eye. We did not find any stump, presumed to be optic nerve stalk, in the posterior aspect of the cyst in our cases. Computed tomography (CT) scan of head and orbit was done for case no. four and the cases undergoing surgery (case five and six). CT scan revealed a large cystic mass in the inferior orbit with a microphthalmic eye in the superior part of the orbit in all the cases (Figure 3).



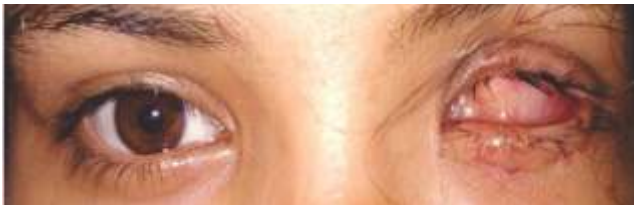**Figure 3:** CT scan reveals a large orbital cyst associated with microphthalmos in cases 4,5 and 6. Note very large cyst with small superoposteriorly displaced microphthalmos in case no. 6 which was not visualized on manual retraction.

The infants were kept for observation, whereas other cases were advised for surgery. Case three and four refused surgery at that time. Case five and six underwent right eye cyst excision with enucleation of microphthalmic eye. An orbital ball implant was placed to maintain the orbital volume, and a conformer was placed to maintain the fornixes.

Gross examination of the excised mass showed a small eyeball attached to a large cystic tissue which on the cut section revealed thick brownish jelly-like content in case five and thick yellowish content in case six. Histopathology demonstrated cyst wall partially lined by neuro-retinal epithelium with underlying fibrocollagenous stroma consisting of disorganized retinal tissue. Cavity contained eosinophilic material with cholesterol clefts and aggregates of foamy macrophages (Figure 4). Microphthalmic eye revealed well-developed retinal tissues and choroidal, and corneal tissues in both cases. Thus, a final diagnosis of microphthalmos with orbital cyst was made in those cases. Postoperative appearance after six weeks was acceptable (Figure 5).



**Figure 4:** Histopathological picture of case no. 5



**Figure 5:** postoperative appearance of case no 5 after 6 weeks

## DISCUSSION

Microphthalmos with orbital cyst occurs due to the faulty closure of the embryonic fissure stage at 7 to 14 mm, resulting in excessive growth of the inner layer of the optic cup.<sup>9</sup> Thus, it occasionally presents with retinochoroidal coloboma and hence the name colobomatous cyst.<sup>2,5,8-10</sup> Margin of the fissures are somewhat everted due to the rapid growth of the inner layer of the optic cup. The fissure of retinal margins is completely developed, which forbids the closing of the optic cup and finally forms a typical coloboma.<sup>14</sup> Uveal tissues are not well developed in the colobomatous zone, which often leads to the thinning and bulging of the overlying sclera resulting in a cystic structure. These orbital cysts can vary from small appendages to large masse and are generally placed at the inferomedial segment of orbit.<sup>9-10,15</sup> Though the nature of cystic mass in microphthalmia is benign, enlargement of cyst progressively with age has been reported and is often attributed to the constant filling up of the cyst by secretions from the neuroglial linings.<sup>9,10</sup>

Microphthalmos with orbital cyst may be unilateral or bilateral, and occasionally appear with isolated findings or associated with systemic abnormalities.<sup>16,17</sup> In our small case series of six cases, we did not find bilateral orbital cyst associated with microphthalmos. Chaudhry et al. observed that bilateral cysts are more likely to be associated with systemic abnormalities compared to unilateral cases. They observed that 29% of the unilateral cases and 67% of the bilateral cases of microphthalmos with orbital cyst were associated with other congenital abnormalities; such as renal agenesis, pulmonary hypoplasia, cleft lips, cleft palates, congenital heart defects, and abnormalities in the central nervous system.<sup>4</sup> In addition, presence of unilateral cyst placed superiorly in bilateral microphthalmos, with disc coloboma have been reported with an autistic child with CHARGE syndrome.<sup>18</sup> In another study, bilateral coloboma of the optic nerve with bilateral coloboma of temporal chorioretinal have also been reported in CHARGE syndrome.<sup>19</sup>

Orbital cysts associated with microphthalmos are placed inferiorly and are characterized by noticeable smaller elements such as lens, uvea, and retina.<sup>4</sup> Whereas, in anophthalmia, there is a complete absence of all the elements of the eye due to lack of invagination of the primary optic vesicle.<sup>20</sup> However, the placement of cystic mass might be unusual and often placed superiorly due to the rotation of fetal fissure in the course of development.<sup>21,22</sup> Also, there might be difficulty in clinical distinction in cyst related to anophthalmia and microphthalmia due to a small globe pushed posteriorly by the cyst.<sup>1</sup> Cyst masking the phtysical eye in unilateral microphthalmos with cyst have also been reported.<sup>23</sup> An orbital dermoid cyst, arachnoid cyst, tumors with central necrosis, or encephalocele can also be sometimes confused with microphthalmos with cyst. A scan and B scan ultrasonography (USG), Magnetic resonance imaging (MRI), and Computed tomography (CT) scan are useful tools to confirm the diagnosis and rule out the differentials.<sup>9,10,24,25</sup> MRI and CT imaging distinctly demonstrate the relation between the cyst and the vitreous and are useful tools to visualise very small clinically hidden globes.<sup>1</sup> In our case series, three cases (case no. four, five, and six) were scanned with CT, although all the patients were subjected to USG B-scan for the diagnosis. Interestingly, the clinical examination did not reveal the microphthalmic eye in case no. six. However, a CT scan later demonstrated a large orbital cyst with superoposteriorly displaced small globe.

Removal of the cyst, along with the microphthalmic eye if it is very small to contribute to the orbital volume, is the mainstay of surgical management. This is followed by an appropriately sized orbital implant, conformers, and ocular prosthesis weeks later to provide good cosmetic results. Evaluation of orbital volume can be done using the classification given by Duke-Elder.<sup>5</sup> Relation between the orbital cyst in microphthalmia and orbital volume have been described by Cui et al.<sup>2</sup> They recommended that large orbital cyst in microphthalmos have a positive role in orbital development. We were hesitant to operate on the two infants in our case series for this purpose. Chaudhry et al. managed 23 cases of microphthalmos with orbital cyst using



a treatment protocol as described in their study.<sup>4</sup> If the cyst is small, observation is recommended in mild cases. Similarly, if the cyst is large, surgical removal of the cyst is to be done. Severe cases need excision of both cyst and globe alongside adequate replacement of the orbital volume with implants.<sup>4</sup> McLean et al. also managed 34 patients with orbital cysts with microphthalmia using a similar approach.<sup>1</sup> Cystic orbital masses associated with microphthalmia are lined with neuroectodermal bulging throughout the colobomatous area of microphthalmic eye.<sup>14</sup> Histopathology demonstrates cyst wall lined by neuroretinal epithelium and stroma consisting of disorganized retinal tissue. The histopathology features of orbital cyst associated with microphthalmos and anophthalmos are similar, however, an associated microphthalmic eye renders the definitive diagnosis.

## CONCLUSION

Careful ophthalmic clinical examination aided by

radiographic investigations can reveal the microphthalmic eye in suspicious cases of anophthalmos whilst also revealing the orbital cyst associated. Two of the six cases in our series were managed surgically. Cyst excision with enucleation of the microphthalmic eye followed by an orbital implant of adequate volume and conformer lead to good cosmetic outcomes in our cases.

## PATIENT CONSENT

Written informed consent was obtained from the patients or their legal guardian for the publication of this case report and accompanying images. A copy of the written consent is available for review by the Editor-in-Chief of this journal.

## CONFLICT OF INTERESTS

The authors declare that they have no competing interests. No funding was available for this study.

## REFERENCES

- McLean C, Ragge N, Jones R, Collin J. The management of orbital cysts associated with congenital microphthalmos and anophthalmos. *British journal of ophthalmology*. 2003;87(7):860-3. DOI: 10.1136/bjo.87.7.860
- Cui Y, Zhang Y, Chang Q, Xian J, Hou Z, Li D. Digital evaluation of orbital cyst associated with microphthalmos: characteristics and their relationship with orbital volume. *PloS one*. 2016;11(6):e0157819 DOI: 10.1371/journal.pone.0157819
- Harimohan, Sen D, Gupta D, Aurora A. Congenital microphthalmos with orbital and orbitopalpebral cysts. *Indian Journal of Ophthalmology*. 1969;17(3):103-8. PMID: 5370708
- Chaudhry IA, Arat YO, Shamsi FA, Boniuk M. Congenital microphthalmos with orbital cysts: distinct diagnostic features and management. *Ophthalmic Plastic & Reconstructive Surgery*. 2004;20(6):452-7. DOI: 10.1097/01.iop.0000143716.12643.98
- Elder D. Congenital deformities. *System of Ophthalmology, Normal and Abnormal Development*. 1964;3(part 2):456-95.
- Foxman S, Cameron JD. The clinical implications of bilateral microphthalmos with cyst. *American journal of ophthalmology*. 1984;97(5):632-8. DOI: 10.1016/0002-9394(84)90384-2
- Guterman C, Abboud E, Mets MB. Microphthalmos with cyst and Edwards' syndrome. *American journal of ophthalmology*. 1990;109(2):228-30. DOI: 10.1016/s0002-9394(14)75995-1
- Waring GO, Roth AM, Rodrigues MM. Clinicopathologic correlation of microphthalmos with cyst. *American Journal of Ophthalmology*. 1976;82(5):714-21. DOI: 10.1016/0002-9394(76)90008-8
- Weiss A, Martinez C, Greenwald M. Microphthalmos with cyst: clinical presentations and computed tomographic findings. *Journal of pediatric ophthalmology and strabismus*. 1985;22(1):6-9. DOI: 10.3928/0191-3913-19850101-04
- Wright DC, Yuh WT, Thompson HS, Nerad JA. Bilateral microphthalmos with orbital cysts: MR findings. *Journal of computer assisted tomography*. 1987;11(4):727-9. DOI: 10.1097/00004728-198707000-00038
- Yoshihara M, Ishizawa A, Sato K, Tamaki H. Bilateral Microphthalmos with Orbital Cyst. *Neurologia medico-chirurgica*. 1991;31(4):223-5. DOI: 10.2176/nmc.31.223
- Zeiter HJ. Congenital Microphthalmos: pedigree of four affected siblings and an additional report of forty-four sporadic cases. *American journal of ophthalmology*. 1963;55(5):910-22. DOI: 10.1016/0002-9394(63)90368-4
- Warburg M. An update on microphthalmos and coloboma: a brief survey of genetic disorders with microphthalmos and coloboma. *Ophthalmic paediatrics and genetics*. 1991;12(2):57-63. DOI: 10.3109/13816819109023675
- Lieb W, Rochels R, Gronemeyer U. Microphthalmos with colobomatous orbital cyst: clinical, histological, immunohistological, and electronmicroscopic findings. *British journal of ophthalmology*. 1990;74(1):59-62. DOI: 10.1136/bjo.74.1.59
- Simmons JD, LaMasters D, Char D. Computed tomography of ocular colobomas. *American journal of roentgenology*. 1983;141(6):1223-6. DOI: 10.2214/ajr.141.6.1223
- Makley JT, Battles M. Microphthalmos with cyst. Report of two cases in the same family. *Survey of ophthalmology*. 1969;13(4):200-6. PMID: 5764076
- Kodama T, Shibuya Y, Setogawa T, Hasegawa Y, Yamaguchi S, Hirayama Y. A case of microphthalmos with cyst and partial trisomy 22. *Ophthalmic Genetics*. 1998;19(2):93-7. DOI: 10.1076/opge.19.2.93.2319
- Pushker N, Tinwala S, Khurana S, Sen S. Bilateral microphthalmos with unilateral superior cyst in a child with autism and CHARGE syndrome. *International ophthalmology*. 2013;33(2):195-8. DOI: 10.1007/s10792-012-9653-y
- De Krijger RR, Mooy CM, Van Hemel JO, Sulkers EJ, Kros JM, Bartelings MM, et al. CHARGE association-related ocular pathology in a newborn with partial trisomy 19q and partial monosomy 21q, from a maternal translocation (19;21)(q13.1;q22.3). *Pediatric and Developmental Pathology*. 1999;2(6):577-81. DOI: 10.1007/s100249900165
- Pasquale LR, Romayananda N, Kubacki J, Johnson MH, Chan GH. Congenital cystic eye with multiple ocular and intracranial anomalies. *Archives of Ophthalmology*. 1991;109(7):985-7. DOI: 10.1001/archophth.1991.01080070097044
- Mann I, Ross JA. A case of atypical coloboma associated with abnormal retinal vessels. *The British journal of ophthalmology*. 1929;13(12):608-12. DOI: 10.1136/bjo.13.12.608
- Thakur S, Kashyap B. Microphthalmos with upper eye lid cyst-A case report. *Indian journal of ophthalmology*. 1988;36(2):100. PMID: 3235157
- Ozturker C, Kaynak P, ÖzkanArat Y, OzturkKarabulut G, Akar S, Demirok A. An atypical case of microphthalmos with cyst: cyst masquerading as phthisical eye. *Ophthalmic plastic and reconstructive surgery*. 2015;31(6):e150-e2. DOI: 10.1097/iop.0000000000000185
- Fisher YL. Microphthalmus with ocular communicating orbital cyst-ultrasonic diagnosis. *Ophthalmology*. 1978;85(11):1208-11. DOI: 10.1016/s0161-6420(78)35565-2
- Timalsina BR, Shrestha GB, Thapa M. Congenital Microphthalmia with Intraorbital Cyst: A Rare Case Report. *Case Reports in Ophthalmological Medicine*. 2019;2019:3640175. DOI: 10.1155/2019/3640175.

