

# CHRONIC SUBDURAL HEMATOMA FOLLOWING VENTRICULOPERITONEAL SHUNT: A CASE REPORT

Karki M<sup>1\*</sup>, Roka YB<sup>2</sup>, Pandit M<sup>3</sup>, Yadav S<sup>3</sup>

## Affiliation

1. Consultant Neurosurgeon, Department of Neurosurgery, Neuro Cardio and Multispeciality Hospital, Nepal
2. Senior Consultant Neurosurgeon, Department of Neurosurgery, Neuro Cardio and Multispeciality Hospital, Nepal
3. Medical officer, Department of Neurosurgery, Neuro Cardio and Multispeciality Hospital, Nepal

## ARTICLE INFO

Received : 16 August, 2020

Accepted : 26 November, 2020

Published : 22 December, 2020

© Authors retain copyright and grant the journal right of first publication with the work simultaneously licensed under Creative Commons Attribution License CC - BY 4.0 that allows others to share the work with an acknowledgment of the work's authorship and initial publication in this journal.



CR 37

DOI: <https://doi.org/10.3126/bjhs.v5i3.33719>

### \* Corresponding Author

Dr. Mohan Karki

Consultant Neurosurgeon

Department of Neurosurgery

Neuro Cardio and Multispeciality Hospital, Nepal

Email: [jigyasu86@gmail.com](mailto:jigyasu86@gmail.com)

ORCID ID: <https://orcid.org/0000-0001-7201-0054>

## Citation

Karki M, Roka YB, Pandit M, Yadav S. Chronic Subdural Hematoma Following Ventriculoperitoneal Shunt: A Case Report. BJHS 2020;5(3)13. 1258-1260.

## ABSTRACT

Chronic Subdural Hematoma (CSDH) is rare complication following ventriculoperitoneal (VP) shunt for hydrocephalus. A fourteen year/male presented with complain of gradually weakness of right sided limbs, severe headache, seizure and slurring of speech after two and half month of VP shunt placement for congenital hydrocephalus. CT scan head was done and it reported left CSDH with mass effect. Patient was managed with left parietal single burr-hole and CSDH evacuation.

## KEYWORDS

*burr-hole, chronic, subdural hematoma, VP shunt*



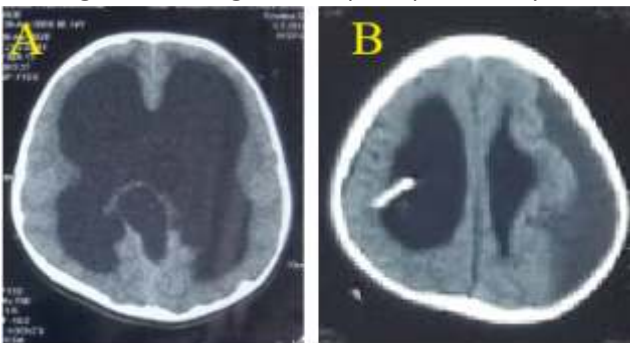
## INTRODUCTION

Chronic subdural hematoma (CSDH) is one of rarely accounting complication following VP shunt for hydrocephalus. Over-drainage of cerebrospinal fluid (CSF) following as a result of CSF diversion procedure is the main causes for CSDH consequent to VP shunt. Subdural hematoma (SDH) may occur in 10-12% of long term VP shunt patients within 6.5 year after initial shunting.<sup>1</sup> Similarly, it accounts approximately 4-23% in adults and 2.8-5.4% in children.<sup>2</sup> As the time passes, subdural hematoma liquefies sub -acute to chronic subdural hematoma. Even there are number of surgical techniques, most commonly applied techniques are burr-hole and craniotomy. We report a case of CSDH with right sided weakness, slurring of speech and seizure disorder two and half month following VP shunting. Patient was managed by burr-hole with CSDH evacuation and had better result.

## CASE REPORT

This 14 year-male child presented to emergency department to our hospital with complain of severe headache, right sided weakness, slurring of speech and seizure. He had undergone medium pressure (MP) ventriculoperitoneal shunting before two and half months for congenital (aqueductal stenosis) hydrocephalus. Shunting had also been done too late even it was congenital diseases. It might be due to unawareness about diseases/or living in remote area. (Figure 1A). At presentation he is alert and moving all limbs, but right sided limbs are comparatively weak than left one. CT head reported left fronto- temporo- parietal (FTP) hypo- dense homogenous collection with feature of mass effect and midline shift towards right side. The shunt tip is in situ (Figure 1 B).

Patient underwent left parietal single burr-hole. Liquefied hematoma with an appearance of machinery oil, called CSDH evacuation was done. Repeat CT head screening was done on 4<sup>th</sup> day of surgery because patient had complained of severe headache. CT head revealed left FTP hypo- dense collection with pneumocephalus, but comparatively smaller in size. Subdural drain was inserted for 5 days along with temporary tying of VP shunting for 5days. Patient was kept head down position. Patient tolerated surgery and advised to keep whole body on flat position for 3weeks after discharge and discharged on 12<sup>th</sup> post operative day.



**Figure 1:** Axial CT scan which showed grossly dilated ventricles (A), Post OP CT Scan which revealed VP hunt tip in situ and left CSDH (B), Post OP CT Scan which showed

some relaxation of compressed brain with left side small residual collection and pneumocephalus (C) and Post OP CT Scan which showed subdural drain is in situ and relaxation of left sided compressed parenchyma (D).

## DISCUSSION

Hydrocephalus (HCP) is common neurosurgical condition and accounting approximately prevalence and incidence of 0.9-1.2/1000 and 0.2-0.6/1000, respectively in developed countries.<sup>3</sup> Much research is going on but still remains a common problem for both developed and developing countries, although developing countries face the complications of VP shunting more than other countries.<sup>4</sup> Hydrocephalus (HCP) is mainly subdivided into obstructive and non-obstructive hydrocephalus. Congenital (obstructive) hydrocephalus is second most common congenital malformation after spina bifida.<sup>5</sup> The incidence of congenital hydrocephalus is approximately 0.9-1.8/1000 and reported range from 0.2-3.5/1000births.<sup>6</sup> Even there are some surgical methods, VP shunting and third ventriculostomy are commonly using technique for congenital hydrocephalus at this period.

Endoscopy third ventriculostomy is evolving new alternative technique for VP shunting,<sup>7</sup> however VP shunting is standard procedure for obstructive hydrocephalus till date. Kausch developed technique of CSF absorption in peritoneal cavity by VP shunting in 1908.<sup>8</sup> VP shunting have potential complications that may require multiple surgical procedures during patient's lifetime. However, it has effectively reduced the morbidity and mortality of children with hydrocephalus. Shunt malformation is mainly caused by obstruction, mechanical disconnection or breakage, infection and over-drainage. Over-drainage (over-shunting) has possible complications such as slit ventricle syndrome, intracranial hypotension, microcephaly and craniosynostosis, stenosis or occlusion of sylvian aqueduct and subdural hematoma (SDH).<sup>1</sup>

Chronic subdural hematoma following VP shunting is uncommon neurosurgical disorder. Most common mechanism for subdural hematoma (SDH) formation may be due over -drainage of CSF following VP shunt.<sup>9</sup> It may cause to collapse of brain with tearing of bridging vein. A study by Yovne et al, described that children had higher rate of shunt complication than adults at 5 years (48% versus 27%).<sup>10</sup> The pathogenesis of the formation and development of CSDH is still issue of discussion and needs further studies. Patho-physiological process, such as inflammatory reaction, formation of neomembrane and liquefaction of blood has been implicated.<sup>11</sup>

The clinical presentations can range from asymptomatic to symptomatic with sign of intracranial hypertension, seizure, delayed in development or even heriation.<sup>12</sup> CT head is primary modality for diagnosis.<sup>13</sup> But, non-contrast brain MRI can also be used to rule out hygroma from CSDH. CSDH can be evacuated by small twist-drill or burr hole with or without placement of subdural drain. Treatment for CSDH has preferred to change from craniotomy to burr hole in

recent years,<sup>14</sup> where craniotomy is applied for organized and calcified CSDH. In our case, single burr-hole and CSDH evacuation was implicated. Patient developed severe headache on 4<sup>th</sup> day of surgery. Repeat CT head was done and found comparatively small residual collection. Subdural drain was inserted again along with temporary tying off shunt was done (Figure 1 C). Temporary tying off shunt usually reduces the degree of shunting drainage by lower pressure in subdural space than intra-ventricular space to

prevent the re-collection of SDH.<sup>15</sup> Patient discharged on 12<sup>th</sup> day of first surgery with improvement of symptoms (Figure 1D).

## CONCLUSIONS

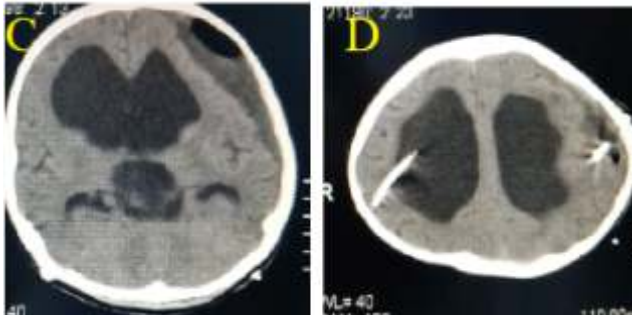
CSDH following VP shunting is rare neurosurgical condition. The craniotomy procedure also need to be thought for CSDH evacuation, however burr hole is standard method. Sometimes, both insertion of subdural drain and temporary tying off shunt are also applicable for management of CSDH following VP shunting.

## ACKNOWLEDGEMENT

None

## CONFLICT OF INTERESTS

There is no conflict of interests



## REFERENCES

- Pudenz R H, Foltz EH. Hydrocephalus: Overdrainage by ventricular shunt. A review and recommendations. *Surg Neurol.* 1991; 35:200-12. DOI: 10.1016/0096-3019(91)90072-h.
- Puca A, Fernandez E, Colosimo C, Lauretti L, Pallini R, Tamburrini G. Hydrocephalus and macrocrania: Surgical or non-surgical treatment of post shunting subdural hematoma. *Surg Neurol.* 1996; 45:76-82. DOI: 10.1016/0096-3019(95)00450-5.
- Oi S. Classification and identification of hydrocephalus. Origin, controversy, and assignment of the terminology. In: Cinalli G, Sainte-Rose C, Maixner WJ, editors. *Pediatric hydrocephalus.* Milano: Springer; 2005. Pp.95-111. <https://doi.org/10.1007/978-88-2121-111-6>.
- Mubarak H, Riaz A, Aleem-ud-Din Sh, Mohammad H A. Ventriculoperitoneal shunt blockage. *J Ayub Med Coll Abbottabad.* 2012;24(3-4):82-4. PMID:24669618.
- Wiswell TE, Tuttle DJ, Northam RS, Simonds GR. Major Congenital neurologic malformation. A 17-year survey. *Am J Dis Child.* 1990; 144:61-67. DOI:10.1001/archpedi.1090.02150250071035.
- Lamire R J. Neural tube defects. *JAMA.* 1988; 259:558-62. PMID: 3275817.
- McLaughlin MR, Wahlig J B, Kaufmann A M, Albright AL. Traumatic basilar aneurysm after endoscopy third ventriculostomy: Case report. *Neurosurgery.* 1997; 41:1400-4. <https://doi.org/10.1097/00006123-199712000-00034>.
- Chung JJ, Yu JS, Kim JH, Nam SJ, Kim MJ. Intrabdominal complications secondary to ventriculoperitoneal shunt: CT findings and review of the literature. *AJR Am J Roentgenol.* 2009; 193: 1311-7. DOI: 10.2214/AJR.09.2463.
- Papanikolaou PG, Paleogos TS, Triantafyllou TM, Chatzidakis EM. Shunt revision 33 year in a patient with bilateral calcified chronic subdural hematoma. *J Neurosurg.* 2008; 108:401. DOI:10.3171/JNS/2008/108/2/0401.
- Yovvne W, Nella L Green, Margarent R W, Shoujun Z, Nalin G et al. Ventriculoperitoneal shunt complications in California. 1990-2000. *Neurosurgery.* 2007; 61(3): 557-63. <https://doi.org/10.1227/01.NEU.0000290903.07943.AF>.
- Drapkin A J. Chronic subdural hematoma: Pathophysiological basis of treatment. *Br J Neurosurg.* 1991; 5:467-73. <https://doi.org/10.3109/02688699108998475>.
- Hideki M, Yuichi H, Masachika S, Kazuhiro S, Masaru K, Kazuhiro G et al. Why do chronic subdural hematoma continue to grow and not coagulate? Role of thrombomodulin in the mechanism. *J Neurosurg.* 2001; 96(5):877-84. DOI: 10.3171/jns.2002.96.5.0877. DOI:10.3172/jns.2002.96.5.0877.
- Ludwig B, Nix W, Lanksch W. Computed tomography of the "armored brain". *Neuroradiology.* 1983;25:39-43. DOI:10.1007/BF00327479.
- Weir B K A. Results of burr hole and open or closed suction of drainage for chronic subdural hematoma in adults. *Can J Neurol Sci.* 1983; 10: 22-26. DOI: 10.1017/so317100044516.
- Illingworth E D, Subdural hematoma after the treatment of chronic hydrocephalus by ventriculocaval shunts. *J Neurol Neurosurg Psychiatry.* 1970; 33: 95-9. DOI: 10.1136/jnnp.33.1.95.