

A VITREOUS CYST IN AN ELDERLY: A RARE CASE REPORT

Khatri A^{1*}, Banstola A², Karki P³

Affiliation

1. *Lecture, Department of Ophthalmology, Birat Medical College and Teaching Hospital, Nepal*
2. *Lecturer, Department of Ophthalmology, Lumbini Eye Insitute and Research Centre, Nepal*
3. *Vitreo Retina Surgeon, BPKLCS, Institute of Medicine, Kathmandu, Nepal*

ARTICLE INFO

Article History

Received : 05 June, 2019

Accepted : 27 July, 2019

Published : 31 August, 2019

© Authors retain copyright and grant the journal right of first publication with the work simultaneously licensed under Creative Commons Attribution License CC - BY 4.0 that allows others to share the work with an acknowledgment of the work's authorship and initial publication in this journal.



CR 25

DOI: <http://dx.doi.org/10.3126/bjhs.v4i2.25461>

* Corresponding Author

Dr. Anadi Khatri

Lecturer

Department of Ophthalmology

Birat Medical College and Teaching Hospital, Nepal

Email ID : anadik@gmail.com

ORCID ID: <https://orcid.org/0000-0002-0444-224X>

Citation

Khatri A, Banstola A, Karki P. A Vitreous Cyst In An Elderly: A Rare Case Report. BJHS 2019;4(2)9: 759 - 761.

ABSTRACT

This condition has been seen to occur in younger patients. We report here a case of a 54-year - old woman with vitreous cyst.

KEY WORDS

Adult, Eye Diseases, Vitreous Body, Cysts



INTRODUCTION

Vitreous cysts are an uncommon eye disorder and are considered an "ocular oddity". This condition has been seen in younger patients aged 6 -8 years, across the entire range of adults. It is mostly seen in adults aged 10 - 20 years. Here, we report a case of 54 years female presenting with a single floater occasionally obscuring vision in her left eye for 15 days.

CASE REPORT

A 54-year-old female presented with a floater in the left eye. She reported a single shadow like projection in her left eye since last 15 days. When specifically asked, she reported shadow changing with head position. She denies any history of diminution of vision, redness, trauma, double vision, flashes or past ocular surgery/intervention. The intraocular pressure was 18 and 16 mmHg respectively.

She has no history of Diabetes, hypertension or any other chronic illness for which she has been treated or is receiving treatment. She is a non-vegetarian but doesn't eat pork/beef /partially cooked meat.

The patient's best-corrected visual acuity was 6/6 in both eyes. The anterior segment was normal in both eyes on slit-lamp examination. Fundus examination of the right eye was also normal. On examination of the left eye, a round, semi-translucent, partially pigmented cystic lesion (~1.5 disc diameter (DD) in size) was found in the vitreous cavity just below the supero-temporal vascular arcades (~1DD from temporal disc margin).(Figure 1 and 3)

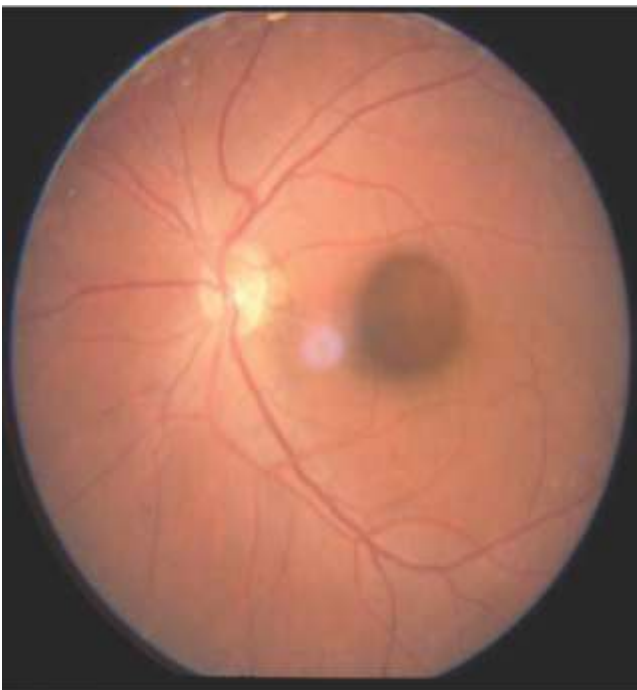


Figure 1: Fundus picture showing the vitreous cyst floating in front of the macular region of the left eye.

The cyst seemed freely floating during the ocular movements but came to its neutral position at rest. Systemic investigations such as- Blood, stool, and urine investigations were sent and were normal. No ova or cyst was observed in the stool.

Ultrasonography of the left was performed which showed a cystic lesion with hyper echogenic wall with central hypoechogenicity in the posterior vitreous. On changing to transverse scan, the cyst appeared not free floating but attached to a posterior pole with a pedunculation which was hyperechogenic in nature (Figure 2)

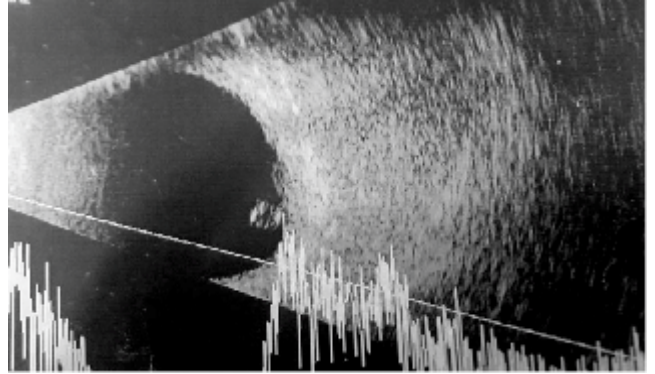


Figure 2: USG scan showing a pedunculated mass

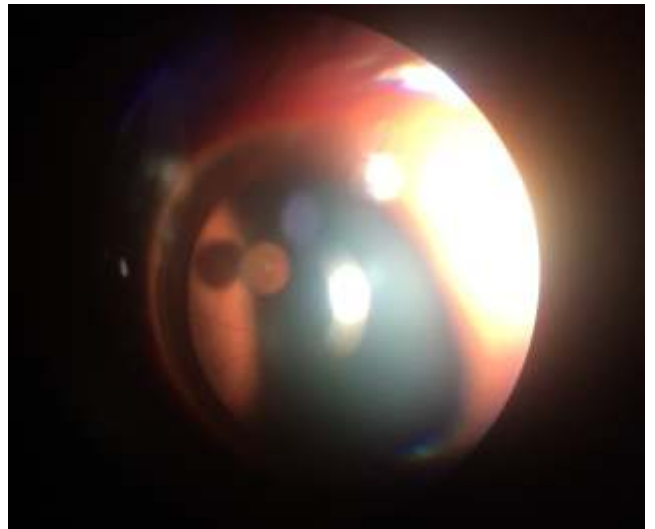


Figure 3: Vitreous cyst floating seen via slit lamp.

The patient was planned for left eye core vitrectomy with cyst removal and biopsy. 3 port pars plana vitrectomy using 20 gaugeport was done and the cyst was removed in toto and sent for histopathological and microbiological evaluation.

Biopsy revealed pigmented cells with the absence of vessels. No calcification, atypical cells or parasites were observed. Her post-operative BCVA was 6/6 and diagnosis of left eye Vitreous cyst was made.

DISCUSSION

Although their origins are still under discussion, free - floating vitreous cysts were mainly classified as congenital and acquired. The former may come from residues of the

hyaloid artery or glial residues of the papilla of Bergmeister and are often detected in normal and symptomless eyes. These congenital vitreous cysts have been described as sessile or stalked cysts anterior to the optic disc and are rarely limited in their movement by vitreous strands linked to it. In patients affected by degenerative diseases, such as retinitis pigmentosa and choroidal atrophy, acquired

vitreous cysts have been described and reported to arise from the degeneration of a ciliary anomaly breaking into the vitreous cavity, cystic growth at the site of a coloboma entering the vitreous cavity or in case of parasitic infestation. Non pathological vitreous cysts usually needs no intervention but in cases with problems such as floaters, vitrectomy can be performed safely to surgically remove the cyst.

REFERENCES

1. Bullock JD. Developmental vitreous cysts. *Arch Ophthalmol.* 1974; 91:83–84.
2. Lisch W, Rochels R. Pathogenesis of congenital vitreous cysts (in German) *KlinMonbl Augenheilkd.* 1989;195:375–378.
3. Pannarale C. On a case of preretinal mobile cysts in a subject affected by congenital toxoplasmosis (in Italian) *G ItalOftalmol.* 1964;17:306–317.
4. Tranos PG, Ferrante P, Pavesio C. Posterior vitreous cyst and intermediate uveitis. *Eye.* 2010;24:1115–1116.
5. Tuncer S, Bayramoglu S. Pigmented free-floating vitreous cyst in a patient with high myopia and uvealcoloboma simulating choroidal melanoma. *Ophthalmic Surg Lasers Imaging.* 2011;42 (Online): e49–e52.

