

OUTCOME OF COMPLICATED GROIN HERNIA REPAIR AT B.P. KOIRALA INSTITUTE OF HEALTH SCIENCES: A RETROSPECTIVE STUDY

Joshi BR^{1*}, Gautam S², Sah S³, Poudel N⁴, Shrees PT⁴

Affiliation

1. Assistant Professor, Department of Surgery, BP Koirala Institute of Health Sciences, Nepal
2. Research Officer, Study Co-ordinator, Global Congestive Heart Failure (G-CHF) Studies, B P Koirala Institute of Health Sciences, Dharan, Nepal
3. Additional Professor, Department of Surgery, B P Koirala Institute of Health Sciences, Dharan, Nepal
4. Student (MBBS-4th year), B P Koirala Institute of Health Sciences, Dharan, Nepal

ARTICLE INFO

Article History

Received : 26 October, 2017

Accepted : 11 August, 2018

Published : 31 August, 2018

© Authors retain copyright and grant the journal right of first publication with the work simultaneously licensed under Creative Commons Attribution License CC - BY 4.0 that allows others to share the work with an acknowledgment of the work's authorship and initial publication in this journal.



ORA 62

DOI: <http://dx.doi.org/10.3126/bjhs.v3i2.20932>

* Corresponding Author

Dr Brikh Raj Joshi
Assistant Professor
B.P. Koirala Institute of Health Sciences, Nepal
brikhajoshi@gmail.com
ORCID: <https://orcid.org/0000-0003-2410-2979>

Citation

Joshi BR, Gautam S, Sah S, Poudel N, Shrees PT. Outcome of Complicated Groin Hernia Repair at B.P. Koirala Institute of Health Sciences: A Retrospective Study. BJHS 2018;3(2)6:395-398.

ABSTRACT

Introduction

Groin hernias are common problem worldwide with approximate incidence of 5%. Indirect inguinal hernia is the commonest hernia irrespective of gender. The prevalence as well as complication of inguinal hernia will increase with increasing age. Strangulation, the most common serious complication of inguinal hernia occurs in 1 to 3% of the patients. Outcome of the treatment depends on the duration of presentation, co-morbidities and extent of the surgery.

Objective

The objectives were to study the different clinical presentation, surgical options and outcome of complicated groin hernia in tertiary care centre.

Methodology

This retrospective review of case sheet was conducted in the department of surgery. We reviewed the record file of complicated groin hernia patients, irrespective of age and gender from January 2008 to December 2016(8 years). Ethical Clearance was obtained from institutional review committee. Statistical analysis was performed using SPSS for windows, version 11.5(SPSS Inc., Chicago, IL). The data were presented in percentage, mean and standard deviation.

Results

Out of 45 patients, majority were male 37(82.2%) and commonly effected age group was more than 60 years 18(40%) followed by infants and adolescents. Majorities had complicated inguinal hernias 42 (93.3%) followed by femoral hernia, i.e.3(7%). Majority of patient underwent inguino-scrotal exploration 26(57.77%) followed by herniotomy 9(20%) and hernioplasty 7(15.55%). Most of the patients were discharged from the hospital 37(82.2%).

Conclusion

Most common type of complicated hernia is inguinal hernia; irreducibility and pain were commonest symptoms at presentation. Commonly performed operation is inguino-scrotal exploration and herniorraphy with good surgical outcome.

KEYWORDS

Groin hernia, herniorraphy, strangulation.



INTRODUCTION

Inguinal hernia is an abnormal protrusion of intra-abdominal tissue through a fascial defect in the groin. The overall lifetime risk of developing a groin hernia is approximately 15% in males and less than 5% in females. There is clearly an association between age and hernia diagnosis. After an initial peak in the infant, groin hernias become more prevalent with advancing age.¹

If the symptomatic hernia is not treated in time there is always a chance of complication like irreducibility, obstruction and strangulation. Risk factors for groin hernias to present as acute emergencies are advancing age, large hernias with small opening, delay in hospitalizations and coexisting medical complications.

During the initial period of complication, hernia may be just irreducible but with the passage of time there will be bowel obstruction and if still the surgical intervention is delayed, patient will land up with strangulation. In case of a strangulated inguinal hernia, bowel becomes gangrenous and perforation occurs. This will increase the morbidity and mortality of the patient.

Eduard Bassini's paper describing his new operation for inguinal hernia in 1889 with very low recurrence rate revolutionized the hernia operation technique. The main feature of his operation was suture of the threefold layer to Poupart's ligament to form the posterior wall of the new inguinal canal.²

Till date there are multiple surgical techniques for repair of uncomplicated groin hernia like Bassini repair, Shouldice's repair, Lichtenstein mesh repair and laparoscopic hernia repair. For the complicated groin hernia open operation is the surgery of choice.

Groin hernias are one of the most common surgical problems in our setting. Due to lack of health awareness and unavailability of medical facility in many places of our region, the rate of complicated hernias are high. So, this study will help to provide valuable information about age of presentation, operation performed and outcomes of complicated groin hernias.

METHODOLOGY

This retrospective review of case sheet was conducted in the department of surgery. After permission from hospital director and medical record section, we reviewed the record file of complicated groin hernia patients, irrespective of age and gender from January 2008 to December 2016 (8 years). Objectives of our study were to study the different presentations, surgical procedures and outcome of complicated groin hernia. Ethical Clearance was obtained from institutional review committee.

Parameters analyzed were age, gender, history of swelling, clinical examination, clinical diagnosis, operation performed and postoperative outcome.

Operative Techniques

Herniotomy

After general anaesthesia and endotracheal intubation, prepping and draping of surgical area was done. All cases were operated by either senior surgeon or lecturer. Incision was made in the inguinal crease and extended up to root of scrotal region through the most prominent part of swelling according to the need of the surgeon. External oblique muscle was opened along the line of fibers. Sac and cord structures were hooked using index finger against pubic tubercle. Sac was identified and dissected from the cord structures. The sac was opened, fluid was sucked out and hernia contents were examined for its viability and managed accordingly (either reduction, resection anastomosis, hot mopping with warm saline wet tetra for 10 to 15 minutes). Then neck of the sac was closed with polyglactin 2-0 round body sutures. In case of children and adolescent (less than 16 years of age) posterior wall strengthening was not done. Hemostasis was maintained and external oblique muscle was closed. Skin was sutured with nylon 3/0 sutures and dressing was applied.

Herniorraphy /hernioplasty

After transfixation of sac at the deep ring, posterior wall strengthening was done by standard darn repair in case of adult and elderly patients. But if the contents of sac were viable (irreducible and obstructed hernia) then polypropylene mesh was kept (Lichtenstein's tension free mesh repair technique) for the strengthening of posterior inguinal canal wall. Closure was similar to herniotomy.

McEvedy operation

McEvedy was the operation of choice in case of complicated femoral hernia. A vertical incision was made in the lower abdomen centered at the lateral edge of the rectus muscle. The anterior rectus sheath was incised and the rectus muscle displaced medially. Then proceeded to the muscle in the preperitoneal space. The femoral hernia was reduced and the sac opened to allow careful inspection of the bowel, and a decision was made regarding the need for bowel resection. The femoral defect was then closed with sutures (polypropylene). Rectus sheath was closed with polypropylene and skin was closed with nylon sutures.

Laparotomy

Patients who had preoperative evidence of peritonitis, were planned for laparotomy with peritoneal lavage and closure of internal ring and resection and anastomosis of the perforated bowel segment under general anaesthesia. After prepping and draping generous midline incision was made, rectus sheath was divided along the line of incision and peritoneal cavity was opened. Peritoneal lavage was done with warm saline. Hernia was reduced and perforated bowel was identified and resection and end to end two layer anastomosis was done. Internal ring was closed with polypropylene sutures. Drain was kept in the pelvis. Midline was closed with polypropylene sutures and skin was closed with nylon sutures.

Data were entered in Microsoft Excel 2007 and Statistical Package for Social Sciences Version software (SPSS) was used for statistical analysis. The data were presented in percentage, mean and standard deviation.

RESULTS

Out of 45 patients majorities were male 37 (82.2%). Most of the patients were more than 60 years of age 18(40%) followed by infants and adolescents 10(22.2%). (Figure 1).

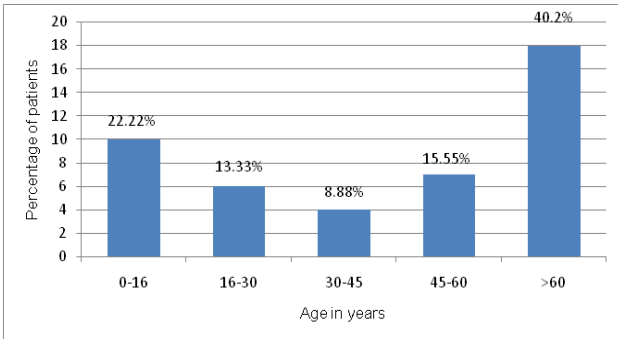


Figure 1: Age (years) wise distribution of the patients (n= 45)

Out of 45 patients, majorities had complicated inguinal hernias 42 (93.3%) followed by femoral hernia 3 (7%). Majority of patient presented with pain and irreducibility followed by features of intestinal obstruction (abdominal distension, vomiting, and not passing stool and flatus). Only one patient had diabetes mellitus and 10(13.3%) had hypertension. Majority of the patients had obstructed hernia 30 (67%) followed by irreducibility 8 (18%) and strangulation 7 (15%).

Majority of patients underwent inguino-scrotal exploration 26 (57.77%) followed by herniotomy 9 (20%) and hernioplasty 7(15.55%). Only 2 (4.44%) patient underwent laparotomy and one patient had Mc-evedy operation (Figure 2). Operative findings were edematous bowel as content 25 (55.5%) followed by gangrenous bowel 9 (20%) and omentum 11(24.4%).

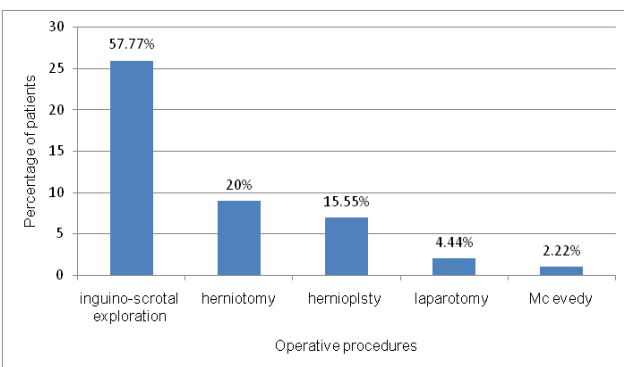


Figure 2. Operative procedures

Most of the patients were discharged from the hospital 37 (82.23%), 5 (11.11%) expired and 3 (6.66%) left the hospital against medical advice (LAMA).

DISCUSSION

In this study 37(82.2%) male patients were suffering from complicated groin hernia and only 8 (17.2%) were females. Systemic review done by McIntosh A et al. also showed that inguinal hernias were nine times more common in males and so the complications. Although the femoral hernias were more common in females but still the inguinal hernia was the most common.¹

Most of the patients with complicated groin were infants and adolescents 10 (22.22%) and elderly patients 18 (40%). The risk of strangulation is highest in the first months to years after the initial presentation of a reducible hernia probably because of tighter deep ring.¹ With the passage of time, the hernia contents weaken the hernia defect and widen the hernia neck so that the sac is no longer compressed as tightly, thereby decreasing the opportunity for incarceration and strangulation to take place. The prospective clinical study conducted in the department of surgery showed that most common age group involved was the 41-50 years (42.5%) with male dominance(95%,38).³

Pattern of clinical presentation, Operation performed, Operative findings and Postoperative outcome:

In this study majority of patient presented with pain and irreducibility followed by features of intestinal obstruction (abdominal distension, vomiting, and not passing stool and flatus). Majority of the patients were suffering from obstructed hernia 30 (67%) followed by irreducibility 8 (18%) and strangulation 7 (15%). But Muralidharan, S et al. found that most common presentation was irreducible swelling in the groin and pain in the swelling however they did not mentioned about features of obstruction and strangulation.³

In some patient it was difficult to differentiate between irreducible, obstructed and strangulated hernia clinically. An interesting retrospective study done in 2012 examining whether various laboratory parameters could predict the viability of sac contents showed that only increased lactate level was associated with a lack of viability ($P < 0.01$, Mann-Whitney U test).⁴

In our study almost all the patient underwent open emergency operation. Laparoscopic repair was not done due to lack of equipment and surgeon's expertise. Out of forty five patient majority of them underwent inguino-scrotal exploration 26(57.77%) followed by herniotomy 9 (20%) and hernioplasty 7(15.55%). Only 2(4.44%) patient underwent laparotomy and 1 patient had Mc-evedy operation. In case of complicated groin hernia operation of choice was open hernia operation but there were studies that advocate laparoscopic repair is a feasible procedure with acceptable results.^{5,6,7}

In this study 7(15%) patient underwent Lichtenstein tension free mesh repair. The retrospective study by Venara et al. compared the 30-day outcome after acute hernia (inguinal, femoral, and umbilical) repair with or without mesh. They found that the mesh repair was neither related

to a significant increase of complications ($P = 0.89$) nor related to surgical site infection (SSI) ($P = 0.95$).⁸ A four year retrospective review of 188 patients who underwent emergency laparoscopic repair of complicated groin hernia and open repair revealed that laparoscopic group had significant lower wound infection rate ($P < 0.018$) without higher recurrence rate ($P < 0.815$) and shorter hospital stay (4.39 vs 7.34 days).⁹

A systematic literature review performed in 2009 identified articles reporting on laparoscopic treatment, reduction, and repair of incarcerated or strangulated inguinal hernias from 1989 to 2008, concluded that the laparoscopic repair is a feasible procedure with acceptable results; however, its efficacy needs to be studied further, ideally with larger, multicentre randomized controlled trials.¹⁰

Outcome of the treatment was comparable with other studies. Most of the patients were improved and discharged from hospital 37 (82.2%). Five (11.1%) had mortality and was mainly because of hospital acquired pneumonia and sepsis. Three (7%) patients left the hospital against medical advice. In one other study the records of 385 consecutive patients undergoing emergency surgical operation were analyzed. Study revealed that the overall complication rate was 19.5%, and major complications were 15.1%.¹¹ They found that the mortality was only 2.9% and most serious postoperative complications were pulmonary and cardiovascular. Retrospective review of 188 patients was done to investigate factors affecting the outcome in cases of incarcerated abdominal wall hernias. The results showed that symptomatic periods lasting longer than 8 hours, the presence of comorbid disease, high American Society of Anesthesiologists (ASA) scores, the use of general

anaesthesia, the presence of strangulation, and the presence of necrosis significantly affect morbidity and mortality rates.^{12,13}

CONCLUSION

The most common type of complicated hernia is inguinal hernia and irreducibility and obstruction were commonest symptoms at presentation. Commonly performed operation was inguino-scrotal exploration with herniorrhaphy with good surgical outcome.

RECOMMENDATIONS

A prospective longitudinal study to evaluate the different factors affecting the outcome of the patient with complicated groin hernia is recommended.

LIMITATION OF THE STUDY

The case sheets were not filled completely regarding surgical as well as postoperative complications. This study could not evaluate the outcome of surgery over a period of time.

ACKNOWLEDGEMENT

We would like to thank department of surgery and medical record section for their constant support to conduct this study.

CONFLICT OF INTEREST

We declare no conflict of interest.

FINANCIAL DISCLOSURE

None

REFERENCES

- McIntosh A, Hutchinson A, Roberts A, Withers H. Evidence-based management of groin hernia in primary care—a systematic review. *Fam Pract.* 2000;17(5):442-7 PMID:11021907 [Indexed for MEDLINE].
- John E, Summers M.D. Classical herniorrhaphies of Bassini, Halsted and Ferguson, *The American Journal of Surgery.* 1947; 73(1):87-99 [https://doi.org/10.1016/0002-9610\(47\)90294-8](https://doi.org/10.1016/0002-9610(47)90294-8)
- Muralidharan S. and Jade R. An institutional experience on complicated groin hernias. *Indian journal of applied research.* 2016;6 (4)183-84: ISSN - 2249-555X | IF : 3.919.
- Tanaka K, Hanyu N, Iida T, Watanabe A, Kawano S, Usuba T, Iino T, Mizuno R. Lactate levels in the detection of preoperative bowel strangulation. *Am Surg.* 2012;78(1):86–8. PMID:22273321.
- Gallegos NC, Dawson J, Jarvis M, Hobsley M. Risk of strangulation in groin hernias. *Br J Surg* 1991;78(10):1171-73. PMID:1958976.
- El-Dhuwaiby, Corles D, Emmett C, Deakin M, Slavin J Laparoscopic versus open repair of inguinal hernia: a longitudinal cohort study *Surg Endosc.* 2013;27(3):936-45. doi: 10.1007/s00464-012-2538-3. Epub 2012:17. PMID: 23073679.
- Esposito C, St Peter SD, Escolino M, Juang D, Settini A, Holcomb GW 3rd. Laparoscopic versus open inguinal hernia repair in pediatric patients: a systematic review *J Laparoendosc Adv Surg Tech A.* 2014;24(11):811-8. doi: 10.1089/lap.2014.0194.
- Venara A, Hubner M, Le Naoures P, Hamel JF, Hamy A, Demartines N. Surgery for incarcerated hernia: short-term outcome with or without mesh. *Langenbeck's Arch Surg.* 2014;399(5):571–577. PMID:24789811. DOI: 10.1007/s00423-014-1202-x.
- Yang GPC, Chan CTY, Lai ECH, Chan OCY, Tang CN, Li MKW. Laparoscopic versus open repair for strangulated groin hernias: 188 cases over 4 years. *Asian J Endosc Surg.* 2012;5(3):131–137. DOI: 10.1111/j.1758-5910.2012.00138.
- Deeba S, Purkayastha S, Paraskevas P, Athanasiou T, Darzi A, Zacharakis E. Laparoscopic approach to incarcerated and strangulated inguinal hernias. *Journal of society of laparoscopic surgeons.* 2009;13(3): 327–331. PMID: PMC3015964.
- Kulah B, Kulacoglu IH, Oruc MT, Duzgun AP, Moran M, Ozmen MM, Coskun F. Presentation and outcome of incarcerated external hernias in adults *Am J Surg.* 2001;181(2):101-4. PMID: 11425048.
- Derici H, Unalp HR, Bozdog AD, Nazli O, Tansug T, Kamer E. Factors affecting morbidity and mortality in incarcerated abdominal wall hernias. *Hernia.* 2007;11(4):341–6. PMID: 17440794. DOI: 10.1007/s10029-007-0226-3.
- Wolf LL, Scott JW, Zogg CK, Havens JM, Schneider EB, Smink DS, Salim A, Haider AH Predictors of emergency ventral hernia repair: Targets to improve patient access and guide patient selection for elective repair *Surgery.* 2016;160(5):1379-1391. doi: 10.1016/j.surg.2016.06.027.