

## Acupuncture as a Rehabilitative Therapy in Patient with Multiple Sclerosis: A case Study

Jaya Satyal<sup>1</sup>, Pradeep KC<sup>1,2</sup>, Rabindra Shrestha<sup>3</sup>, Pratima Dhakal<sup>3</sup>

<sup>1</sup>Ayurveda Hospital, Nardevi, Kathmandu, Nepal

<sup>2</sup>Ministry of Health and Population, Kathmandu, Nepal

<sup>3</sup>Ayurveda Campus Teaching Hospital, Institute of Medicine, Tribhuvan University

### CORRESPONDENCE

Dr. Jaya Satyal  
Ayurveda Hospital, Nardevi, Kathmandu.  
Nepal  
Email: satyaldrjaya@gmail.com

### ARTICLE INFO

Article History

Submitted: 30 April, 2021

Accepted: 16 June, 2021

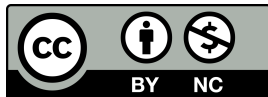
Published: 8 August, 2021

Source of support: None

Conflict of Interest: None

**Copyright :** ©The Author(S) 2021

This is an open access article under the Creative Common Attribution license CC BY-NC 4.0



### ABSTRACT

Acupuncture is a branch of TCM (Traditional Chinese Medicine) and has been practiced in China for more than 3000 years. It coordinates conventional Chinese needling strategies with Western clinical information on the cerebral cortex and has been demonstrated to be an extremely compelling method for treating Multiple sclerosis (MS) and other focal sensory system issues. A 42-year-old female patient who was diagnosed with MS was treated with Acupuncture therapy. This case shows that Acupuncture therapy can be complimentary treatment in Multiple Sclerosis. Acupuncture therapy that holds the possibility to extend treatment alternatives for MS in both ordinary and integrative treatments.

**Keywords:** Acupuncture; Multiple Sclerosis; Traditional Chinese Medicine.

### INTRODUCTION

Multiple sclerosis (MS) is a disease affecting 300,000 people in the United States and 2.3 million worldwide.<sup>1</sup> It is characterized by chronic inflammation, demyelination, gliosis (plaques or scarring), and neuronal loss; the course can be relapsing or progressive. The clinical course is extremely variable, ranging from a relatively benign condition to a rapidly evolving and incapacitating disease requiring profound lifestyle adjustments. Medical management had shown some success in limiting the frequency and intensity of disease activity. Disease activity in patients with primary progressive or secondary progressive MS has not been shown to improve from medical intervention. Many persons with MS have also been dissatisfied with medical management due to perceptions that the medication has a range of unpleasant side effects.<sup>2</sup> This has led many persons with MS to investigate the use of alternative therapies to treat their

disease. Acupuncture coordinates conventional Chinese needling strategies with Western clinical information on the cerebral cortex.<sup>3</sup> and found to be very effective in many neurological conditions. Acupuncture has been frequently mentioned as a non-pharmacologic means of managing the disease, with prevalence of its usage reported from 7.2 to 21% of the MS population.<sup>4</sup> Localized tingling, "pins and needles," and numb sensations are common presenting complain in MS. Involvement of the brainstem may result in diplopia, nystagmus, vertigo, or facial pain, numbness, weakness, hemispasm, or myokymia (rippling muscular contractions). Ataxia, tremor, and dysarthria may reflect disease of cerebellar pathways. Therapy for MS can be divided into several categories: (a) treatment of acute attacks, (b) treatments with disease-modifying agents that reduce the biologic activity of MS, and (c) symptomatic therapy.<sup>5</sup>

## CASE PRESENTATION

42-year-old female, came to our center with a previous diagnosis of MS. She had been diagnosed with MS 2 years earlier. Her initial symptoms were an onset of numbness on the right arm that was followed by subsequent numbness descending down both legs. Over the past 2 years, she had multiple relapses and remissions with episodes of lower extremity weakness, stiffness and muscle spasm, central visual blurring, loss of balance, double vision, and fatigue. Those symptoms typically lasted a few weeks to several months. A year ago, she had a dramatic neurological decline during which she was unable to walk steadily and lost strength and sensation in her lower extremities. For the last 2 years, up to when she came to our center, it was more difficult for her to walk due to weakness in her legs and loss of balance. She also complained of numbness, tingling, and spasms in her legs accompanied by double vision, poor memory and concentration, dizziness and vertigo, heat intolerance, and severe fatigue.

Her diagnosis had been confirmed by MRI that showed multifocal altered signal intensity changes in the bilateral caudate head, right anterior putamen, left posterior limb of internal capsule, left subthalamic region, right paramedian aspect of ventral pons and left side of dorsal pons, right side superior olive, bilateral superior cerebellar peduncle, right side of splenium of corpus callosum, superior vermis and dentate nucleus, some part of inferior cerebellar peduncle and left cerebellar Cortex. Similar signal changes were seen in the right high frontal cortex, left posterior temporal cortical-subcortical WM, left anteromedial temporal cortex and right superior temporal cortex. Some of those areas showed bright signals on DWI without any diffusion restriction. There were micro and macro hemorrhagic changes in the right caudate head, left posterior limb of internal capsule and right superior temporal cortex and also left anterior and posterior temporal cortex. No obvious signal changes were seen in visualized optic nerves.

For the acupuncture session, general and neurological examinations were carried out. Mrs. Lama was awake, alert, cooperative, and attentive and gave appropriate responses. Motor strength was one in both legs and one in both arms and in hand grip. The patient could not make rapid movements with the toes of either foot. The examination revealed no sensory deficit in the patient's face and four extremities. The patient's finger-to-nose tests on both right and left sides were normal. The patient's index finger-to-index finger test was normal. She had difficulty getting out of a chair and presented with spastic and ataxic gait. She ambulated with stiffness

in both legs, was unsteady, and had a wide-based stance. The patient failed the heel toe walking test and could not stand on one leg. She could not stand steadily with eyes open and performed worse with eyes closed.

## ACUPUNCTURE TREATMENT AND ACUPOINT SELECTION

She received Acupuncture for one and half month. She received six treatments per week, from 23rd of March 2021 to 23rd of April 2021. Each Acupuncture treatment session lasted for 30 minutes. Needles were inserted to 0.8 to 1.0 cun perpendicularly. After 15 minutes lifting thrusting and twirling and rotating manipulation was done for one minute at a frequency of 100-120/min. The Acupuncturist with 10 years of experience and with MD in TCM (Acupuncture) administered the treatment. Stainless steel needles of 0.52\*40 mm were used. Appropriate stimulation was applied in order to attain the 'deqi' sensation. The Used Acupoints are Baihui(GV20), Sishencong(EX HN1), Zusanli(ST36), Yanglingquan(GB34), Yinlingquan(SP9), Taichong(LR3), Fenglong(ST40), Kunlun(BL60), Weizhong(BL40), Zhibian(BL54), Neiguan(P6), Hegu(LI4), Waiguan(SJ5), Shousanli(LI10), Qihai(CV6), Guanyuan(CV4), Shenshu(BL23), Ciliao (BL32), Pangguangshu(BL28).

## DURING HOSPITAL STAY

The patient had a very positive response to her initial acupuncture treatment. The dizziness, balance, stiffness, and weakness in her legs showed improvement. She continued to improve with each additional treatments. The numbness and tingling in her limbs did not bother her anymore. She had more energy and the motor functions were significantly improved.

## DISCUSSION

The most common demyelinating neurological disease in the world is Multiple Sclerosis MS. Acupuncture has been demonstrated to have prevalent accomplishment in treating MS and other focal sensory system harm.<sup>6</sup> It can exclusively improve the patient's personal satisfaction and moderate the movement of actual inability yet in addition lessens the quantity of backslides. Patients ought to get needle therapy treatment as quickly as time permits; the prior the treatment, the better the result. Chinese acupuncture therapy treatment for MS has had a lot of accomplishment in diminishing numbness and agony, diminishing fits, partially improving the motor functions, and improving equilibrium. Numerous patients

control, weariness, and in general feeling of prosperity altogether improved after treatment.

As stated above, recent studies have shown that acupuncture can be a very effective modality in controlling MS. Acupuncture often produces remarkable results after her first sitting. It usually relieves symptoms immediately, and sometimes in just several minutes noticeable results are achieved. Acupuncture areas should be chosen according to the patient's particular symptoms.

## CONCLUSIONS

MS is an illness of the focal sensory system influencing a large portion of around 1.3 million individuals around the world. At present, contemporary medicines don't offer a complete solution for MS. Acupuncture is one of the significant correlative and elective treatments for MS. This case report shows that Acupuncture accounts a more successful methodology in achieving speedier and regularly viable upgrades to patients with MS. Acupuncture can give arrangements in circumstances where Western medicines are restricted. It holds the possibility to grow treatment choices for MS in both traditional and correlative or integrative treatments. It not only can improve the patient's side effects and personal satisfaction and moderate and converse the movement of actual incapacities but also improve the quality of life. This case study provides preliminary evidence to suggest that acupuncture is safe for people with MS. A large scale trial and further research is necessary to provide definitive evidence.

## REFERENCE

1. Rosati G. The prevalence of multiple sclerosis in the world: an update. *Neurological sciences*. 2001;22(2):117-39.
2. Karpatkin H, Napolione D, Siminovich-Blok B. Acupuncture and multiple sclerosis: a review of the evidence. *Evidence-Based Complementary and Alternative Medicine*. 2014;2014.
3. Hao JJ, Hao LL. Review of clinical applications of scalp acupuncture for paralysis: an excerpt from chinese scalp acupuncture. *Global advances in health and medicine*. 2012;1(1):102-21.
4. Nayak S, Matheis RJ, Schoenberger NE, Shiflett SC. Use of unconventional therapies by individuals with multiple sclerosis. *Clinical rehabilitation*. 2003;17(2):181-91.
5. Sha D, Qi L, Dongjie Z, Yuhua W, Suicheng X. A Review of Acupuncture in Multiple Sclerosis and Experimental Autoimmune Encephalomyelitis.
6. Jameson, et.al.(2018). *Harrison's Principles of Internal Medicine*, 20th. ed. McGraw-Hill, pg 3188-3200