

An Integrated Approach in COVID-19 Patient with High Oxygen Dependency Status

Jaya Satyal¹, Kasi khatiwada¹, Pratigya koju², Jhularam Adhikari¹, Pradeep kc¹

¹Ayurveda Hospital, Nardevi, Kathmandu. Nepal

²Ayurveda Campus Teaching Hospital, Institute of Medicine, Tribhuvan University

CORRESPONDENCE

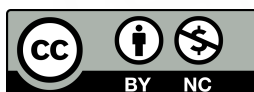
Dr. Jaya Satyal
Ayurveda Hospital,
Nardevi, Kathmandu. Nepal
Email: satyaldrjaya@gmail.com

ARTICLE INFO

Article History
Submitted: 25 December 2021
Accepted: 06 January 2022
Published: 8 February, 2022

Source of support: None
Conflict of Interest: None

Copyright : ©The Author(S) 2022
This is an open access article under
the Creative Common Attribution
license CC BY-NC 4.0



ABSTRACT

Covid-19 has become a global pandemic leading towards thousands of death worldwide. It is infectious disease caused by a new corona virus called SARS-cov-2. WHO learned of the new virus on 31 december 2019 for the first time, following a report of cluster of cases of viral pneumonia in Wuhan, China. However, we report a presentation of covid infection in a 45 year old male in a covid hospital where he was treated with integrated approach i.e Allopathy, Ayurveda, TCM (Traditional Chinese Medicine), Yoga and physiotherapy. During treatment Patient was kept on cpap for some days and got discharged after complete treatment.

Key Words : Allopathy; Ayurveda; Covid-19; Cpap; TCM.

INTRODUCTION

Covid-19 is a highly contagious and pathogenic viral infection which was first reported from Wuhan, China.¹ The causative agent of COVID-19, the SARS-CoV-2 virus is a positive-strand RNA virus that causes severe respiratory syndrome in humans. Symptoms of covid 19 are fever, cough, weakness, chills, shortness of breath, diarrhoea and vomiting. Incubation period of SARS cov 2 is 3-7 days, maximum is found to be 14 days. SARS-coV-2 causes acute lung injury and ARDS (Acute respiratory distress syndrome) which leads to pulmonary failure and this may result to fatality if not treated on time.² The mortality rate of covid-19 patients are found to be high.³ The reason behind this may be complication of covid-19 with fungal infections, arterial and venous thrombosis. Covid-19 is found to induce coagulation disorder leading to clot formation, pulmonary embolism and ischemia.⁴

According to protocol of WHO and guideline of IDSA,

suitable antibiotics, corticosteroids, ivermectin, anti-pyretics, zinc and vitamin supplements, antiviral drugs, anti-coagulants are well practiced during treatment of covid.⁵ China also practiced integrated approach to control Covid -19 pandemic, and found to be very effective. According to protocol of Health Ministry of Nepal, Ayurvedic drugs used for treatment are Jesthavasadi, Guduchi (Tinospora cordifolia), Laxmivilas ras, Sitopaladi powder, Shringa bhasma and Sudarshan powder with Godanti bhasma. JGY powder which is being used since 2 years by covid and non-covid patients was also mentioned and used.

CASE REPORT

A 45 year old male patient admitted to covid hospital with symptoms of dry cough for 5 days duration, fever of 3 days duration. Maximum temperature noted by patient himself

was 100° F. There was no history of vomiting, diarrhea, shortness of breathing, dizziness and loss of appetite and no any associated gastro-intestinal symptoms. He was tested PCR positive and by then he was admitted to covid hospital.

On day 1 of hospital stay, baseline investigations and chest x-ray was done. Haemoglobin was found to be 13.7mg/dl, WBC-4370/ul, neutrophil-84%, lymphocytes-13%, eosinophil-01%, monocytes-00%, basophil-00%, platelets-129900/ul, MCV-92.8fl, MCH-30.9pg, MCHC-33.2%, PCV-41%, glucose random-143mg/dl. Liver function test was also done and report was found to be -Bilirubin (total)-1.4mg/dl, bilirubin (direct)-0.8mg/dl, SGPT-120iu/l, SGOT-383iu/l. C-reactive protein was 22.5 mg/dl. Renal function test was also done with the results, urea-25mg/dl, creatinine-0.9mg/dl, sodium-137mmol/l and potassium -3.8mmol/l.

Chest x-ray-showed Consolidation on both lungs(Figure 1)

TREATMENT COURSE

Patient was kept on Oxygen support with nasal prong at 3L. Patient was given antibiotic Montaz 1gm, solumedrol 80mg, PCM 1gm(stat), enoxaparin 40mg, metronidazole 400mg in Injectable form. Vitamin supplements and zinc supplement along with Ayurvedic cough syrup (Syp crux+kasturibhusan rasa), Lianhua qingwen which is a TCM herbal medicine and cupping therapy were given. Liver tonic was also started. Vitals were monitored 6 hourly. Till day 3 patient was stable and same medicine was continued. But on the 4th day he developed shortness of breath and Spo2 dropped to 85-87%. He was

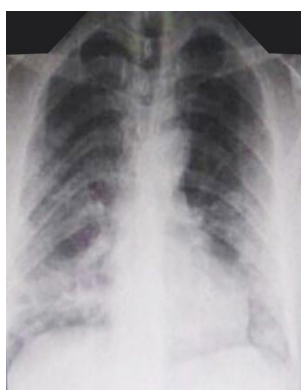

Fig. 1 Chest X-ray during admission

Additional Ayurveda medicines (sitopaladi churna-3gm, laxmibilas rasa 125mg, shringa bhasma 125mg, abhrakbhasma 125mg, godanti bhasma 125mg, sudarshan churna 3gm) with physiotherapy and yoga exercise were started. On day 7 patient was Nebulized. D-dimer, ferritin tests and sputum culture were done and baseline investigations were repeated. He was then sent

for HRCT. D-dimer was found to be 1mg/l, ferretin 750ng/ml, and CRP was found to be 8.7mg/dl. Sputum culture showed no any growth. HRCT reporting showed multifocal patches of ground glass opacities-consolidated changes in all lobes of both lungs involving almost all the segments with sparing of the apical segments in B/L lobes

of lung (Figure 2). CT severity index score was 14/25. Then Antibiotics were changed to Tab.levofloxacin 750mg and Tab. Amoxicillin/Potassium Clavulanate 750 mg and remaining all the medicines were continued as before.

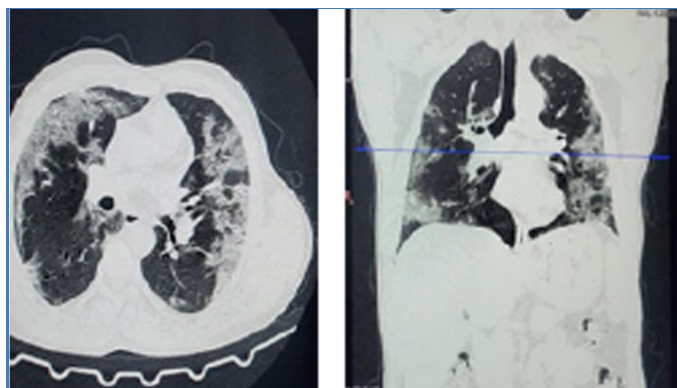


Fig. 2 HRCT Chest showing multifocal patches of ground glass opacities

As vitals were fluctuating, ABG analysis was done on Day 10 and Day 13. ABG report showed normal arterial pH but Pco2 and Po2 were decreased. Patient was kept on cpap as respiration rate was found to increase >25. Patient was kept under cpap at 13L O2 flow. Chest physiotherapy along with yoga, cupping and all the supporting medicines were continued. Cpap with same 13L O2 was continued on day 14 and 15. Vitals were monitored regularly at 2 hours interval. Oxygen was then reduced to 9L on day 16 and 17. On 18th and 19th day cpap was on 8L oxygen and vitals were monitored regularly. On day 20 patient was kept on face mask with 5L flow of O2. Spo2 was 98%. ABG analysis was done again and arterial blood pH was still normal and Pco2 and Po2 were significantly increased. On days 21, 22 and 23 patient was kept under nasal prong, cpap according to the vitals and respiratory rate of patients with regular continuation of medicine. On 24, 25 and 26th days SpO2 was 98% in normal room air. All vitals were normal. All the symptoms got resolved. All the baseline investigations were repeated and report seemed to be normal. Naso-pharyngeal swab was collected and sent for PCR. On day 27 patient was discharged as PCR report came negative and he was fully back to normal condition. He was asked to come for follow up in the opd after 10 days.

On followup, patient was present in opd with no any related symptoms. On examination crackles were heard at the base of right lungs. SPO2 recorded was 94%.

DISCUSSION

During admission patient was quiet fine with all baseline investigations in normal range but the chest x-ray consolidation was seen on both lungs. Conditions deteriorated on course of treatment and the patient

needed more oxygen support for breathing. He was then on cpap from day 13 for 10 days. With all allopathy, Ayurveda, TCM medicine, cupping, physiotherapy and yoga-pranayam, his condition was improved. HRCT showed multifocal patches of ground glass opacities on all lung segments with CT-severity index score of 14/25 and then antibiotic was started. Sputum culture D-dimer, ferretin all showed better results till the day 27. Nebulization from day 7 and antibiotics helped the condition improve. ABG report of day 10 and day 13 showed reduced pco₂ and po₂ with normal blood pH but the condition was still deteriorating with RR>25/min. Cpap starting from 13 L was reduced to 8L on day 19 and then he was kept on 5L O₂ flow on face mask. 20th day ABG showed increased pco₂ and po₂ level with normal arterial blood pH. Finally on day 26, his Spo₂ was 98% on air and PCR test found negative. After every single cupping therapy Spo₂ was found to increase by 3-5%. Ayurveda medicines given were the medicine protocol approved by Ministry of health and population, government of Nepal. Ingredients of sitopaladi churna are cinnamomum zeylanicum, Elettariacardamomum, Piperlongum, Bambusa bambos, cane sugar. All these ingredients are found to have anti histamine property. It is often beneficial to control fever related with flu, congestion and respiratory illness. Sitopaladi churna has antioxidant properties due to which it is mainly efficient for anti-inflammatory action by preventing free radical damage. JGY powder includes Jestavashadi churna, Guduchi churna and Yestimadhu churna which was found to have antihistaminic and anti-viral property. Glycyrrhizin of Yestimadhu is proved having antiviral effect in related SARS-corona virus in cell culture.⁸

Frequent studies have assessed the effects of cupping therapy in this new pandemic. Cupping therapy is a traditional practice which involves placing cups on the skin surface to create vacuum by suction believed to increase blood flow and promote healing associated with chronic neck and back pain. Cupping is also effective in many pathological conditions including high fever, due to infection of the upper respiratory tract pulmonary dysfunctions in asthmatic children. Cupping therapy may improve the most common signs and symptoms of covid -19. Recent study research by Key laboratory of Respiratory disease in China found that Lianhuaqingwen could inhibit the activity of covid 19, reduce the number of viruses in the cell membrane and cytoplasm and inhibit the over activation of cytokines.⁹

CONCLUSION

Integreted approach of Ayurveda medicines along with

Integreted approach of Ayurveda medicines along with Traditional Chinese Medicines, physiotherapy and Allopathy medicine helped a lot to improve his condition but the medicines still need further study to prove its effectiveness on Covid-19 cases as it is only a single case study.

REFERENCE

1. Shereen MA, Khan S, Kazmi A, Bashir N, Siddique R. COVID-19 infection: Origin, transmission, and characteristics of human coronaviruses. *J Adv Res.* 2020;24:91-98. Published 2020 Mar 16. doi:10.1016/j.jare.2020.03.005
2. Zhu N, Zhang D, Wang W, Li X, Yang B, Song J, et al. A novel coronavirus from patients with pneumonia in China, 2019. *N Engl J Med.* 2020. <https://doi.org/10.1056/NEJMoa2001017>.
3. Baud D, Qi X, Nielsen-Saines K, et al.: Real estimates of mortality following COVID-19 infection. *Lancet Infect Dis* 20.20; 20: 773
4. Clerkin KJ, Fried JA, Raikhelkar J, et al.: COVID-19 and Cardiovascular Disease. *Circulation.* 2020; 141(20): 1648–1655.
5. Bhimraj A, Morgan RL, Shumaker AH, Lavergne V, Baden L, Cheng VC, Edwards KM, Gandhi R, Gallagher J, Muller WJ, O'Horo JC, Shoham S, Murad MH, Mustafa RA, Sultan S, Falck-Ytter Y. Infectious Diseases Society of America Guidelines on the Treatment and Management of Patients with COVID-19. *Infectious Diseases Society of America* 2021; Version 4.4.1. Available at <https://www.idsociety.org/practice-guideline/covid-19-guideline-treatment-and-management/>.
6. Jyoti Negi*, Bharat Prashar, Jyoti Gupta, Sitopaladi Churna As Anti-Tussive: A Review, *International Journal of Health and Clinical Research*, 2019;2(6):1-5, e-ISSN: 2590-3241, p-ISSN: 2590-325X
7. Stephanie I. Cheng. (2021). Medical Acupuncture as a Treatment for Novel COVID-19-Related Respiratory Distress: Personal Experience from a Frontline Anesthesiologist. *Medical Acupuncture*, vol. 33 (1), 83-85. doi:10.1089/acu.2020.1467.
8. Cinatl J, Morgenstern B, Bauer G, Chandra P, Rabenau H, Doerr HW. Glycyrrhizin, an active component of liquorice roots, and replication of SARS-associated coronavirus. *Lancet.* (2003) 361:2045–6. doi: 10.1016/S0140-6736(03)13615-X
9. Z. Jia, H. Li, L. Chang, et al. Historical review and reflection about application of traditional chinese medicine in epidemic diseases [J/OL] *Chinese J Exp Formu* (2020), pp. 1-6, 10.13422/j.cnki.syfjx.20201071 -02-26